



## Case report

# In vivo confocal microscopy of verticillata-like paraproteinemic keratopathy in a patient with monoclonal gammopathy of uncertain significance evolving into smoldering multiple myeloma

Chiara Chierogo<sup>a</sup>, Tommaso Merz<sup>a,\*</sup>, Adriano Fasolo<sup>a</sup>, Neil Lagali<sup>b</sup>, Emilio Pedrotti<sup>a</sup>

<sup>a</sup> Eye Clinic, Department of Neurosciences, Biomedicine and Movement Sciences, University of Verona, Italy

<sup>b</sup> Department of Ophthalmology, Institute for Clinical and Experimental Medicine, Linköping University, Linköping, Sweden

## ARTICLE INFO

## Keywords:

Confocal microscopy  
Vortex keratopathy  
Paraproteinemic keratopathy  
Smoldering multiple myeloma

## ABSTRACT

**Purpose:** To highlight the utility of in vivo confocal microscopy (IVCM) in the microstructural characterization of corneal deposits resembling vortex keratopathy in a case of secondary deposition keratopathy due to an evolving monoclonal gammopathy.

**Observations:** A 56-year-old Caucasian woman previously diagnosed with monoclonal gammopathy of undetermined significance (MGUS), exhibited bilateral diffuse sub-epithelial and anterior stromal opacities distributed in a whorl-shaped pattern. IVCM examination permitted analysis of the microstructural features and distribution of the opacities in different corneal layers. Deposits resembling those reported in multiple myeloma rather than MGUS were detected, and the patient's hematologist was subsequently advised to re-evaluate the earlier diagnosis. Two months later, a bone marrow biopsy led to a diagnosis of plasma cell myeloma.

**Conclusions and importance:** It is suggested that cornea verticillata-like paraproteinemic keratopathy (PPK) in MGUS might be predictive of disease evolution to plasma cell myeloma. Characteristic deposits and morphological features revealed by IVCM may be helpful for non-invasive assessment or screening in patients with hematological disorders.

## 1. Introduction

The occurrence of corneal opacities in monoclonal gammopathies (MG) is rarely observed and is known as paraproteinemic keratopathy (PPK).<sup>1</sup> The classic corneal involvement consists of bilateral crystal-like deposits in some or all layers of the cornea, often combined with diffuse or patch-like opacities.<sup>2</sup>

The presence of diffuse granular and spindle-shaped crystals (both intracellular and extracellular) at the level of the corneal epithelium and stroma (crystalline keratopathy) has been reported in patients with MG<sup>3–5</sup> and in those with multiple myeloma (MM).<sup>6–8</sup> While deposits representing a vortex keratopathy (cornea verticillata-like PPK) has been described in four patients with MM<sup>9–12</sup> and in one patient with MGUS,<sup>13</sup> in none of these prior reports had a confocal microscopy evaluation been performed.

Here, we report a case of cornea verticillata-like paraproteinemic keratopathy in a patient with undiagnosed early progression of MGUS, with noteworthy morphologic features revealed by IVCM, particularly in the corneal epithelium and subbasal epithelial layers.

## 2. Case history

A 56-year-old Caucasian woman was referred to our eye clinic for suspected corneal dystrophy and a two month history of transient, mild blurry vision in both eyes. She was previously diagnosed with MGUS, a condition defined by the presence of serum M-protein < 3g/dL, clonal plasma cell population in the bone marrow < 10%, and the absence of end-organ damage such as hypercalcemia (serum calcium  $\geq$  11.5 mg/dL), renal insufficiency (serum creatinine  $\geq$  2 mg/dL), anemia (hemoglobin value below the lower limit of normal by more than 2 g/dL or hemoglobin value < 10 g/dL) and lytic bone lesions (CRAB features) that can be attributed to the plasma cell proliferative disorder.<sup>14</sup> Our patient had a IgG kappa monoclonal peak of 22.7 g/L with a free light chain ratio of 59.1 by electrophoresis, and no evidence of bone lesions, anemia, hypercalcemia, or renal insufficiency.

Best-corrected visual acuity was 20/20, with a hyperopic correction of 0.75 D and 1 D sphere in right and left eyes, respectively. Family and personal medical history were negative for ocular or corneal diseases, and the patient did not use any medication for ocular or systemic

\* Corresponding author. U.O.C. di Oculistica, Policlinico G.B. Rossi, P.le L.A. Scuro 10, 37134, Verona, Italy.

E-mail address: [tommaso.merz@apss.tn.it](mailto:tommaso.merz@apss.tn.it) (T. Merz).

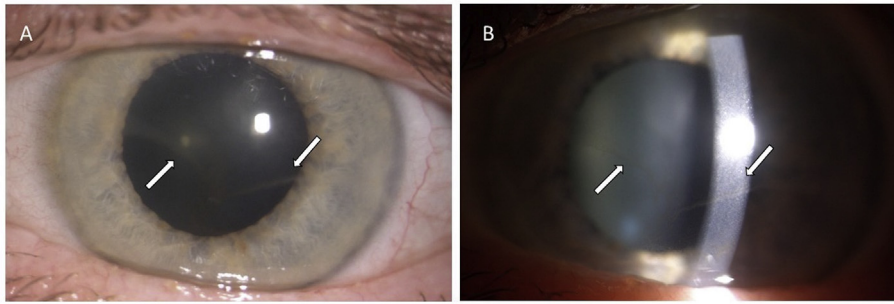
<https://doi.org/10.1016/j.ajoc.2019.100505>

Received 9 July 2018; Received in revised form 13 January 2019; Accepted 27 June 2019

Available online 29 June 2019

2451-9936/© 2019 The Authors. Published by Elsevier Inc. This is an open access article under the CC BY-NC-ND license

(<http://creativecommons.org/licenses/by-nc-nd/4.0/>).



**Fig. 1.** Corneal biomicroscopy examination. A, Pigmented hazy subtle deposits at the level of the basal epithelium/anterior stroma forming a faint golden-brown whorl pattern (arrows). B, Slit-lamp detail (arrows). Similar features were observed in both eyes. (For interpretation of the references to colour in this figure legend, the reader is referred to the Web version of this article.)

conditions.

Slit-lamp examination revealed bilateral sub-epithelial and anterior stromal whorl-shaped opacities, consisting of fine lines emanating from a central nodal point in a pattern resembling that reported for cornea verticillata (Fig. 1). In vivo confocal microscopy (IVCM, HRT3 Rostock Cornea Module, Heidelberg Engineering GmbH) was performed to characterize the corneal deposits at the microstructural level and enabled the visualization of deposits in different corneal layers, which changed in appearance according to depth in the epithelium and stroma (Fig. 2). Specifically, hyperreflective deposits confined to the cell nucleus were observed in the wing cell layers of the epithelium. These deposits were predominantly round or oval-shaped in the upper wing cells, and less dense and more polygonal in shape in the lower wing cell layers. Linear, crystalline deposits were found at the level of the basal epithelium. Nerves in the subbasal nerve plexus exhibited very prominent deposits or beads along the entire nerve fiber length. In the anterior stroma, small reflective para-nuclear deposits were accompanied by more needle-shaped opacities while only smaller reflective opacities within keratocytes were found extending from mid-stroma to the deep pre-Desceemet stroma.

Considering the negative family history for ocular diseases and earlier diagnosis of MGUS, the slit lamp and IVCM findings led to a

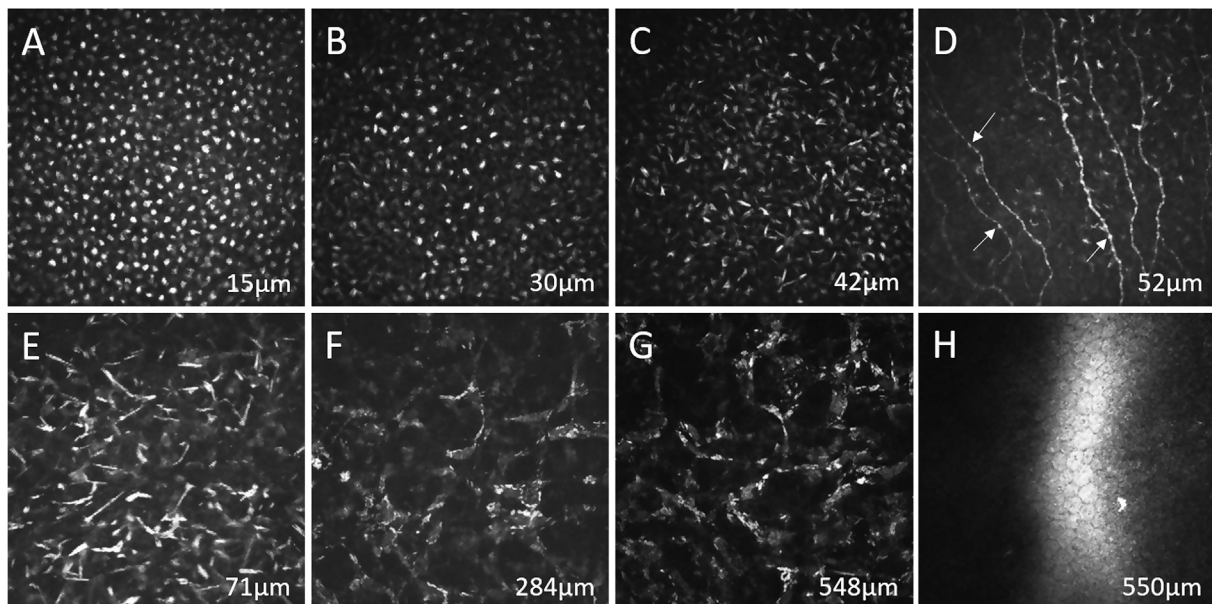
diagnosis of verticillata-like PPK.<sup>1</sup>

Due to the relatively recent onset of the symptoms and the more frequently reported presence of deposits observed by IVCM in MM rather than MGUS,<sup>4, 15</sup> the patient's hematologist was advised to re-evaluate the systemic diagnosis. Immunoglobulin light chain restriction following bone marrow biopsy showed increased mature plasma cell count kappa (25–30% of the whole cellularity) and morphological and immunophenotypic analyses led to a diagnosis of plasma cell myeloma. Since the patient continued to be asymptomatic, without anemia, kidney failure, hypercalcemia or skeletal lesion at low dose total body CT, smouldering multiple myeloma (SMM) IgG kappa was diagnosed.<sup>16</sup>

### 3. Discussion

Vortex keratopathy is commonly associated with Fabry disease, pharmacologically-induced corneal deposits (amiodarone, chloroquine, hydroxy chloroquine, indomethacin, chlorpromazine, tamoxifen, mepredine), toxicity of topical medications and ocular surface failure secondary to chemical and thermal burns.<sup>11</sup> In order to diagnose these conditions a full anamnesis is required, including pharmacological and familial history.

Fabry disease is a hereditary, X-linked disease caused by a



**Fig. 2.** In vivo laser scanning confocal microscopy findings. A, hyperreflective deposits, predominantly round or oval-shaped confined to the nucleus, in the upper wing cell layers of the epithelium. B, less dense reflective deposits, more polygonal in shape, confined to the nucleus in lower wing cell layers. C, dense, linear, crystalline deposits with basal epithelial cell borders not visible in the basal epithelium. D, subbasal nerve plexus contains linear crystalline deposits, with subbasal nerves exhibiting very prominent deposits or beads (arrows) along the entire nerve fiber length. E, long, crystalline deposits in the subepithelial stroma. F, reflective para-nuclear deposits within keratocytes of the mid-stroma. G, para-nuclear keratocyte deposits extending to the deep pre-Desceemet stroma. H, normal mosaic appearance with no apparent deposits in the endothelium. All images are  $400 \times 400 \mu\text{m}$  in size, and were taken from the central cornea. Approximate depth from the corneal surface is indicated on each image.

deficiency in lysosomal hydrolase  $\alpha$ -galactosidase A ( $\alpha$ -GalA), with the result being intralysosomal accumulation of glycosphingolipids. The diagnosis is difficult when the family history is negative for Fabry disease, in which case gene mutation analysis should be performed to confirm a clinical diagnosis.<sup>17</sup>

Corneal epithelial disturbance in a spiraling pattern has been rarely reported in patients with dysproteinemias such as MM and SMM<sup>9–13</sup>; in these patients corneal features more frequently include stromal haze, lattice and crystalline dystrophy, secondary to immunoglobulin deposition in the various corneal layers.<sup>1,11</sup>

SMM is an asymptomatic clonal plasma cell disorder, distinguished from MGUS by a much higher risk of progression to MM. SMM includes patients who behave like those with MGUS (with a very low rate of progression) and those who develop clinical symptoms and end-organ damage within the first 2 years of diagnosis.<sup>16</sup>

Therefore, ophthalmologists should consider that even mild corneal alterations could be an important sign of insidious systemic disease.

Paraproteinemic keratopathy in a patient with SMM assessed with IVCM was previously described by Mazzotta et al.<sup>6</sup> as diffuse, bilateral randomly oriented needle-shaped crystals present in the corneal stroma, sparing epithelium and endothelium. Conversely, our patient showed a vortex disposition of opacities upon clinical examination, while IVCM demonstrated an involvement of all layers of the epithelium, atypical prominent beading of sub-basal nerves and affected keratocytes throughout the stroma, with apparent sparing of the endothelium. Biopsy and histological examination of corneal deposits was avoided as this would be unnecessarily invasive and is not standard procedure for paraproteinemic keratopathy.

Based on the observations in this case, it is suggested that cornea verticillata-like PPK in MGUS might be predictive of disease evolution; however, further cases would be required to confirm this hypothesis. We agree with the suggestion of Lisch et al. namely to examine every patient with MGUS at the slit lamp to include or exclude a PPK and conversely, to perform serum protein electrophoresis in all cases of unclear bilateral corneal opacification to include or exclude a PPK.<sup>1</sup> Characteristic cellular deposits and morphological features revealed by IVCM examination may additionally be helpful for non-invasive assessment or screening of corneal signs in patients with hematological disorders.

#### Patient consent

Written consent to publish case details has been obtained from the patient.

#### Acknowledgements and disclosures

#### Funding

No funding or grant support

#### Conflicts of interest

The authors have no financial disclosures.

#### Authorship

All authors attest that they meet the current ICMJE criteria for Authorship.

#### Acknowledgements

None.

#### Appendix A. Supplementary data

Supplementary data to this article can be found online at <https://doi.org/10.1016/j.ajoc.2019.100505>.

#### References

- Lisch W, Wasieleca-Poslednik J, Kivelä T, et al. The hematologic definition of monoclonal gammopathy of undetermined significance in relation to paraproteinemic keratopathy (an American ophthalmological society thesis). *Trans Am Ophthalmol Soc*. 2016 Aug;114:T7.
- Garibaldi DC1, Gottsch J, de la Cruz Z, et al. Immunotactoid keratopathy: a clinicopathologic case report and a review of reports of corneal involvement in systemic paraproteinemias. *Surv Ophthalmol*. 2005 Jan-Feb;50(1):61–80.
- Bourne WM, Kyle RA, Brubaker RF, et al. Incidence of corneal crystals in the monoclonal gammopathies. *Am J Ophthalmol*. 1989;107:192–193.
- Aragona P, Allegra A, Postorino EI, et al. Corneal structural changes in nonneoplastic and neoplastic monoclonal gammopathies. *Investig Ophthalmol Vis Sci*. 2016;57:2657–2665.
- Paladini I, Pieretti G, Giuntoli M, et al. Crystalline corneal deposits in monoclonal gammopathy: in-vivo confocal microscopy. *Semin Ophthalmol*. 2013;28:37–40.
- Buerk BM, Tu E. Confocal microscopy in multiple myeloma crystalline keratopathy. *Cornea*. 2002;21:619–620.
- Kocabeyoglu S, Mocan MC, Haznedaroglu IC, et al. In vivo confocal microscopic characteristics of crystalline keratopathy in patients with monoclonal gammopathy: report of two cases. *Indian J Ophthalmol*. 2014;62:938–940.
- Mazzotta C, Caragiuli S, Caporossi A. Confocal microscopy in a case of crystalline keratopathy in a patient with smoldering multiple myeloma. *Int Ophthalmol*. 2014;34:651–654.
- Auran JD, Donn A, Hyman GA. Multiple myeloma presenting as vortex crystalline keratopathy and complicated by endocapsular hematoma. *Cornea*. 1992;11:584–585.
- Chong EM, Campbell RJ, Bourne WM. Vortex keratopathy in a patient with multiple myeloma. *Cornea*. 1997;16:592–594.
- Sharma P, Madi HA, Bonshek R, et al. Cloudy corneas as an initial presentation of multiple myeloma. *Clin Ophthalmol*. 2014;8:813–817.
- Finis D, Stammen J. Ungewöhnliche stromale hornhauteinlagerungen. *Ophthalmologe*. 2010;107(5):471–473.
- Hutchinson K, Dal Pra M, Apel A. Immunoglobulin G crystalline keratopathy associated with monoclonal gammopathy. *Aust N Z J Ophthalmol*. 1998;26(2):177–179.
- Kyle RA, Therneau TM, Rajkumar SV, et al. Prevalence of monoclonal gammopathy of undetermined significance. *N Engl J Med*. 2006;354:1362–1369.
- Steinberg J, Eddy MT, Katz T, et al. Bilateral crystalline corneal deposits as first clinical manifestation of monoclonal gammopathy: a case report. *Case Rep Ophthalmol*. 2011;2:222–227.
- Rajkumar SV, Landgren O, Mateos MV. Smoldering multiple myeloma. *Blood*. 2015;125:3069–3075.
- Cumali D, Suzan GY, Huseyin O, et al. A novel mutation and in vivo confocal microscopic findings in Fabry disease. *Saudi J Ophthalmol*. 2017;31:45–47.