Technical Note

Improved Gadolinium-Enhanced Subtraction MR Angiography of the Femoropopliteal Arteries: Reintroduction of Osseous Anatomic Landmarks

Neil M. Rofsky[1], Giovanni Morana[2], Mark A. Adelman[3], Vivian S. Lee[1], Glenn A. Krinsky[1]

Gadolinium-enhanced MR angiography techniques are proliferating for the examination of patients with peripheral vascular disease [1–3]. Gadolinium-enhanced MR angiography relies on the IV injection of paramagnetic contrast material to shorten the T1 relaxation time of blood and thus optimize contrast between vessels and background [4]. To augment such image contrast, the use of digital subtraction imaging has become popular [2, 3, 5]. With subtraction, the signal from background tissues can be minimized, if not completely eliminated, and additional vascular detail can be shown. A consequence of subtraction techniques is the loss of anatomic landmarks, especially osseous landmarks. These landmarks can be essential for presurgical planning, such as guiding the proximal and distal surgical incision sites [6]. The purpose of this report is to describe and detail the clinical relevance of a simple postprocessing MR technique that preserves the benefits of subtracted images while reintroducing bony landmarks.

Materials and Methods

Gadolinium-enhanced MR angiography studies obtained for the evaluation of peripheral vascular disease of the femoropopliteal segment were selected for postprocessing. All studies were performed on a 1.5-T machine (Vision; Siemens, Iselin, NJ) equipped with a 25-mT/m gradient system and 600-μsec rise time using the body coil. Coronal three-dimensional gradient-echo MR images were acquired with the following parameters: 3.8–5/1.3–2 (TR range/TE range) and a flip angle of 30–50°. The field of view was adjusted to cover the anatomic area under study and varied from 375 to 450 mm with a slab thickness between 100 and 130 mm. The data matrix was adjusted so that pixels were smaller than 2.8 × 1.75 (in-plane) × 3 mm (partition thickness). Imaging times were between 16 and 34 sec. As part of our routine, two station studies were performed using similar parameters in the aortoiliac segment and the femoropopliteal segment.

Gadopentetate dimeglumine (Magnevist; Berlex Laboratories, Wayne, NJ) was administered through a 22-gauge IV arm catheter using a dose of 0.1 mmol/kg. For patients examined before April 1, 1996, contrast medium was administered by a hand bolus injection, and the data acquisition was initiated 10 sec after completing the IV injection. For patients examined on or after April 1, 1996, an MR-compatible power injector (Spectris; Medrad, Pittsburgh, PA) was used in conjunction with a timing scan to optimize contrast administration, as previously described [7]. Contrast medium was injected at a rate of 2 ml/sec and was followed immediately by a 20-ml saline flush. Images were acquired before, during, and after gadolinium injection to visualize the unenhanced, early arterial, and delayed arterial phases, respectively. In all cases, the femoropopliteal segment was evaluated using a separate contrast injection after gadolinium-enhanced MR angiography of the pelvis.

All image postprocessing techniques, including maximum intensity projection, multiplanar reformatting, and image addition and subtraction, used the standard, commercially available software of the MR system.

Images of the femoropopliteal segment with the greatest arterial enhancement were chosen for processing. To minimize background signal intensity, a baseline image set was subtracted from the enhanced image set with the greatest arterial enhancement, resulting in a subtraction image set. The baseline image set was acquired after completion of gadolinium-enhanced pelvic MR angiography but before the second administration of contrast medium dedicated to the femoropopliteal segment. Maximum-intensity-projection images were generated at 12° increments for 180° for the following data sets: baseline, peak contrast, nonsubtracted, and subtracted. The frontal view from the maximum-intensity-projection data sets was used in subsequent image postprocessing.

A coronal 10-mm-thick reconstruction of the baseline data set that best showed both femurs was obtained. In some cases, a slight obliquity was introduced in the anteroposterior plane to capture a greater amount of femoral detail for reference. The 10-mm reformatted image was fur-

Received November 4, 1998; accepted after revision March 3, 1999.

[1]Department of Radiology, New York University Medical Center, MRI Basement, Schwartz Bldg., 530 First Ave., New York, NY 10016. Address correspondence to N. M. Rofsky.

[2]Department of Radiology, University of Verona, 37134 Verona, Italy.

[3]Department of Surgery, New York University Medical Center, New York, NY 10016.

AJR 1999;173:1009–1011 0361–803X/99/1734–1009

ther manipulated by reducing all pixel values by 20 units, with four sequential decrements of 20 units. Each of the four manipulated images was then added to a separate anteroposterior view of the subtracted maximum-intensity-projection image, resulting in four combined images, each with a different vessel–background contrast. The image that was best overall at displaying vascular detail and sufficiently showed the osseous landmarks was then selected by the individual who performed the manipulations.

Results

Subtracted arterial phase maximum-intensity-projection images show better artery–background contrast than do nonsubtracted arterial phase maximum-intensity-projection images (Figs. 1 and 2). Subtraction images were able to reveal small vessels that were not well seen on nonsubtracted images (Fig. 1). The addition of bony landmarks to the subtraction anteroposterior maximum

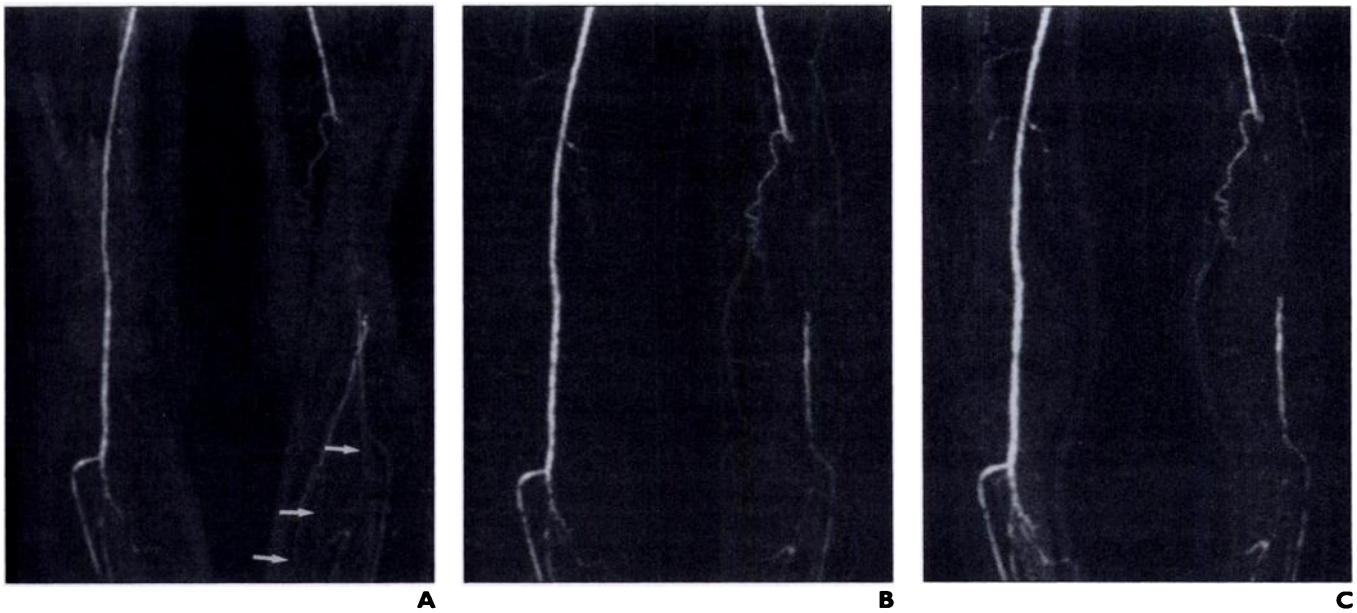

Fig. 1.—81-year-old man who presented with ischemia in left lower extremity.
A, Maximum-intensity-projection image of gadolinium-enhanced three-dimensional data set shows obstruction of left femoral superficial artery. Visualization of reconstituted arteries is degraded by residual venous enhancement (*arrows*) associated with preceding pelvic segment study.
B, Digital subtraction MR angiogram shows vascular details better than **A** and reduces venous enhancement, thus giving better visualization of infrageniculate arterial segment and collateral vessels.
C, Image in **B** after reintroduction of osseous landmarks shows osseous detail.

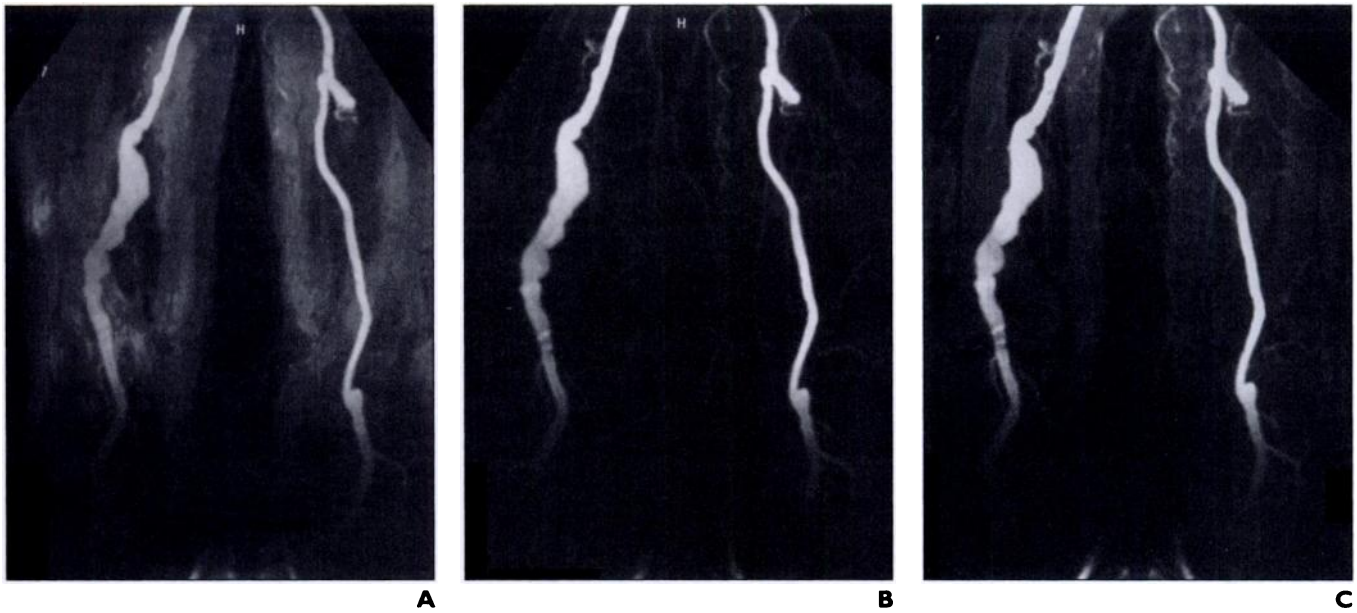

Fig. 2.—73-year-old man with popliteal artery aneurysm.
A, Maximum-intensity-projection image of gadolinium-enhanced MR angiogram shows right-sided aneurysm, but osseous landmarks are difficult to identify.
B, Maximum-intensity-projection image from subtracted data set improves vascular detail and better delineates branch vessels.
C, Image in **B** after manipulation, with osseous landmarks reintroduced.

intensity projection did not compromise vascular detail (Figs. 1 and 2).

Discussion

Gadolinium-enhanced MR angiography has emerged as an alternative to evaluate vascular disorders in the femoropopliteal region [1–3]. The subtraction technique improves visualization of small vessels and may be especially important with reduced-dose gadolinium-enhanced MR angiography [1, 3, 5]. When multiple anatomic segments are studied using repeated injections of contrast medium, residual venous enhancement from the first contrast administration can obscure arterial detail in subsequent acquisitions (Fig. 1A). In these situations, subtraction of the baseline images helps to eliminate the signal from veins (Fig. 1B) and other background tissues.

The osseous anatomy lost during subtraction provides reference points that are important for directing the surgical approach. A common practice with digital subtraction angiography is reintroduction of the osseous landmarks using conventional angiography; if used as the exclusive preoperative angiographic study for patients with peripheral vascular disease, subtraction gadolinium-enhanced MR angiography must be able to satisfy the needs of the vascular surgeon. One can also reintroduce osseous landmarks to gadolinium-enhanced MR angiography images using version 2.5.1 Photoshop software (Adobe Systems, San Jose, CA) after transferring images to a PC. Thus, users with MR systems that do not have the postprocessing capabilities of our unit can also reintroduce osseous landmarks.

The image manipulation strategies we have described depend on image coregistration. Uncooperative patients who cannot remain still may render the postprocessing techniques unsuccessful. Adequate sedation and analgesia, fast examinations, and restraints should minimize the number of technical failures.

On our commercially available system, subtraction postprocessing can be performed in the background while source data are reviewed. All postprocessing can be accomplished in 5–10 min, and in our practice both physicians and technologists are involved.

Osseous landmarks are useful when examining patients with popliteal artery disease. The landmarks are critical for directing the incision site [6] and may influence the selection of graft material by distinguishing supragenicular from infrageniculate disease [8].

Landmarks are also important when an iliac–popliteal artery bypass is needed. The anterosuperior iliac spine and the pubic tubercle provide the landmarks to plan a suprainguinal, retroperitoneal approach. However, reconstruction of pelvic anatomy is more difficult with our technique because the larger volume usually needed typically includes overlying soft tissues.

In summary, we have shown an MR angiography strategy that combines the benefits of subtraction imaging while preserving important information on osseous anatomic landmarks. In so doing, this technique provides a succinct presentation that indicates the level of disease with precision. This approach facilitates the use of MR angiography data as a reliable guide for surgery. We hope that an awareness of these MR techniques and clinical issues will help radiologists communicate gadolinium-enhanced MR angiography information to vascular surgeons most effectively.

References

1. Douek PC, Revel D, Chazel S, Falise B, Villard J, Amiel M. Fast MR angiography of the aortoiliac arteries and arteries of the lower extremity: value of bolus-enhanced, whole-volume subtraction technique. *AJR* **1995**;165:431–437
2. Rofsky NM, Johnson G, Adelman MA, Rosen RJ, Krinsky GA, Weinreb JC. Peripheral vascular disease evaluated with reduced dose gadolinium-enhanced MR angiography. *Radiology* **1997**;205:163–169
3. Lee HM, Wang Y, Sostman HD, et al. Distal lower extremity arteries: evaluation with two-dimensional MR digital subtraction angiography. *Radiology* **1998**;207:505–512
4. Prince MA. Body MR angiography with gadolinium contrast agents. *Magn Reson Imaging Clin N Am* **1996**;4:11–24
5. Leung DA, Pelkonen P, Hany TF, Zimmermann G, Pfammatter T, Debatin JF. Value of image subtraction in 3D gadolinium-enhanced MR angiography of the renal arteries. *J Magn Reson Imaging* **1998**;8:598–602
6. Veith FJ, Haimovici H. Femoropopliteal arteriosclerotic occlusive disease. In: Haimovici H, Ascer E, Hollier LE, Strandness DE, Towne JB, eds. *Vascular surgery*. Cambridge, MA: Blackwell Science, **1996**:605–630
7. Earls JP, Rofsky NM, DeCorato DR, Krinsky GA, Weinreb JC. Breath-hold single-dose gadolinium-enhanced three-dimensional MR aortography: usefulness of a timing examination and MR power injector. *Radiology* **1996**;201:705–710
8. Whittemore AD. Infrainguinal bypass. In: Rutherford RB, ed. *Vascular surgery*. Philadelphia: Saunders, **1995**:794–814