



# Efficacy and safety of flexible versus rigid endoscopic third ventriculostomy in pediatric and adult populations: a systematic review and meta-analysis

Alessandro Boaro<sup>1,2</sup> · Bhargavi Mahadik<sup>3</sup> · Anthony Petrillo<sup>3</sup> · Francesca Siddi<sup>1</sup> · Sharmila Devi<sup>1,4</sup> · Shreya Chawla<sup>1,4</sup> · Abdullah M. Abunimer<sup>1</sup> · Alberto Feletti<sup>2</sup> · Alessandro Fiorindi<sup>5</sup> · Pierluigi Longatti<sup>6</sup> · Francesco Sala<sup>4</sup> · Timothy R. Smith<sup>1</sup> · Rania A. Mekary<sup>1,2</sup>

Received: 13 April 2021 / Revised: 13 May 2021 / Accepted: 14 June 2021  
© The Author(s) 2021

## Abstract

Endoscopic third ventriculostomy (ETV) is a well-established surgical procedure for hydrocephalus treatment, but there is sparse evidence on the optimal choice between flexible and rigid approaches. A meta-analysis was conducted to compare efficacy and safety profiles of both techniques in pediatrics and adults. A comprehensive search was conducted on PubMed, EMBASE, and Cochrane until 11/10/2019. Efficacy was evaluated comparing incidence of ETV failure, while safety was defined by the incidence of perioperative complications, intraoperative bleedings, and deaths. Random-effects models were used to pool the incidence. Out of 1365 studies, 46 case series were meta-analyzed, yielding 821 patients who underwent flexible ETV and 2918 who underwent rigid ETV, with an age range of [5 days–87 years]. Although flexible ETV had a higher incidence of failure in adults (flexible: 54%, 95%CI: 22–82% vs rigid: 20%, 95%CI: 22–82%) possibly due to confounding due to etiology in adults treated with flexible, a smaller difference was seen in pediatrics (flexible: 36%, pediatric: 32%). Safety profiles were acceptable for both techniques, with a certain degree of variability for complications (flexible 2%, rigid 18%) and death (flexible 1%, rigid 3%) in pediatrics as well as complications (rigid 9%, flexible 13%), death (flexible 4%, rigid 6%) and intra-operative bleeding events (rigid 6%, flexible 8%) in adults. No clear superiority in efficacy could be depicted between flexible and rigid ETV for hydrocephalus treatment. Safety profiles varied by age but were acceptable for both techniques. Well-designed comparative studies are needed to assess the optimal endoscopic treatment option for hydrocephalus.

**Keywords** Flexible neuroendoscopy · Rigid neuroendoscopy · Endoscopic third ventriculostomy · Hydrocephalus · Efficacy · Complications

## Introduction

Endoscopic third ventriculostomy (ETV) is a well-established surgical procedure for the treatment of hydrocephalus. It consists in the opening of the floor of the third ventricle

using different types of tools driven through the operative channel of an endoscope [18]. The first ever-reported ETV was conducted by William J Mixer in 1923; he successfully treated a case of non-communicating hydrocephalus using an urethroscope [18]. Ten years later, Tracy Putnam developed the “ventriculoscope,” the first endoscope specifically designed to operate in cerebral ventricles. It included one

Timothy R Smith and Rania A Mekary are the co-senior authors

✉ Alessandro Boaro  
alessandro.boaro@univr.it

<sup>1</sup> Computational Neurosciences Outcomes Center, Brigham and Women’s Hospital, Harvard Medical School, Boston, MA, USA

<sup>2</sup> Institute of Neurosurgery, Department of Neurosciences, Biomedicine and Movement Sciences, University of Verona, Verona, Italy

<sup>3</sup> School of Pharmacy, Massachusetts College of Pharmacy and Health Sciences University, Boston, MA, USA

<sup>4</sup> Faculty of Life Sciences and Medicine, King’s College London, London, UK

<sup>5</sup> Department of Neurosurgery, University of Brescia, Brescia, Italy

<sup>6</sup> Department of Neurosurgery, University of Padova, Padova, Italy

optical glass rod and three grooves, one for the light source and two for the diathermy electrodes [18]. The design and the optic systems, as well as the available operative tools, were then progressively refined. In the 1970s, the British physicist Harold H Hopkins with his system of solid and cemented glass rod lenses surrounded by fiberoptic bundles, paved the way for both the modern rigid and flexible endoscopy [18]. In 1973, Takanori Fukushima was the first neurosurgeon to use a flexible endoscope to perform ventriculostomies with his refined “ventriculofiberscope” [18].

Rigid and flexible endoscopes are both currently used to perform third ventriculostomy, and each type has distinct advantages and drawbacks. Rigid endoscopes are more commonly used compared with their flexible counterparts because they generally produce higher quality images and allow for easier passing of instruments [4]. Their use, however, can be restricted by the size of ventricles and made difficult by the rigid linear nature of the rod lenses [4, 5, 16, 38]. Flexible endoscopes, on the other hand, have an added degree of mobility to help overcome the nonlinear ventricular anatomy. They have been used more frequently in children given their narrower diameter, but they generally present images of lower quality and a limited set of operative tools [4, 5, 22]. Interestingly, the published literature usually focuses on the nuances and outcomes of either rigid or flexible endoscopy alone; only one paper compared the two techniques in a comparative study design to assess the optimal choice of treatment [57]. To our knowledge, no meta-analysis has been conducted to compare efficacy and safety of rigid endoscopy versus flexible endoscopy in ETV.

As the two approaches present both risks and benefits, we decided to pool the available evidence and conduct a meta-analysis to compare efficacy and safety of flexible and rigid neuro-endoscopy in the performance of ETV in pediatric and adult populations.

## Materials and methods

### Search strategy and study selection

A comprehensive electronic search was conducted on PubMed, EMBASE, and Cochrane until November 10, 2019. The search was filtered for English language articles. Comprehensive search results were obtained using relevant MeSH terms, Emtree terms, and text words (Appendix 1). The duplicates were removed and data were exported into Covidence software for screening [17]. All the articles underwent two levels of screening (title/abstract and full-text) by six reviewers (BM, AP, AB, FS, SD, AA). Discrepancies were resolved by discussion or consulting senior authors (AB, RM, FS). Reasons for rejection were listed in accordance with the PRISMA checklist [26].

### Inclusion and exclusion criteria

Articles were included in our study if: they had participants suffering from hydrocephalus who underwent flexible endoscopic third ventriculostomy or rigid endoscopic third ventriculostomy; the study reported failure or reoperation rate in the procedure; the study was an observational study, randomized control trial, or case series of five or more patients diagnosed with hydrocephalus. Articles were excluded from our study if they were not in the English language or if they did not report on patients' outcome and follow-up.

### Data extraction

Studies included after full text screening had their data extracted by five authors (BM, AP, FS, SC, SD). Data were extracted for study characteristics (author, publication year, country of origin, study design and timing, and sample size), patients' characteristics (average age, age category -pediatrics, adults-, type and etiology of hydrocephalus), and intervention characteristics (type of intervention and type of endoscope used). Efficacy or ETV failure was the primary outcome and was defined as patients requiring reoperations after ETV surgery which could either be a second ETV or shunt placement. Safety was assessed as a secondary outcome, evaluating incidence of complications including infection, intraventricular hemorrhage, neurological deficit, motor aphasia, ependymitis, sepsis, and CSF leak, among others, incidence of intra-operative bleeding (witnessed, controlled and reported by the operating surgeon), and incidence of death due to surgery. All the variables and outcomes were recorded for adults, pediatrics, and mixed (both pediatrics and adults) population. Number of events for failure and safety outcomes were recorded for each intervention.

### Data analysis

Incidence measures were analyzed for categorical outcomes by using number of events and total sample size of outcome measures. Pooled effect estimates of incidence measures were analyzed by the random-effects model using the DerSimonian–Laird method [26]. Comprehensive meta-analysis software (CMA) version 3 was used to perform the statistical analyses. Unless otherwise specified, a two-sided  $p$  value of  $< 0.05$  was considered statistically significant.

### Heterogeneity assessment and analysis

The presence of heterogeneity was assessed using Cochrane Q statistic with a significance level of  $p < 0.10$  [27]. Degree of heterogeneity among studies was

determined using the  $I^2$  value [27]. Degree of heterogeneity was reported to be low, medium, and high with  $I^2$  values of 25, 50, and 75%, respectively [28]. All analyses were stratified by age categories (pediatric, adult, mixed). The  $p$  value comparing the subgroups was not derived as these would be highly confounded due to the nature of the included studies (non-comparative). An additional sensitivity analysis was done by removing low quality studies (< median score of 4) from all the analyses to assess the robustness of the findings.

### Risk of bias assessment

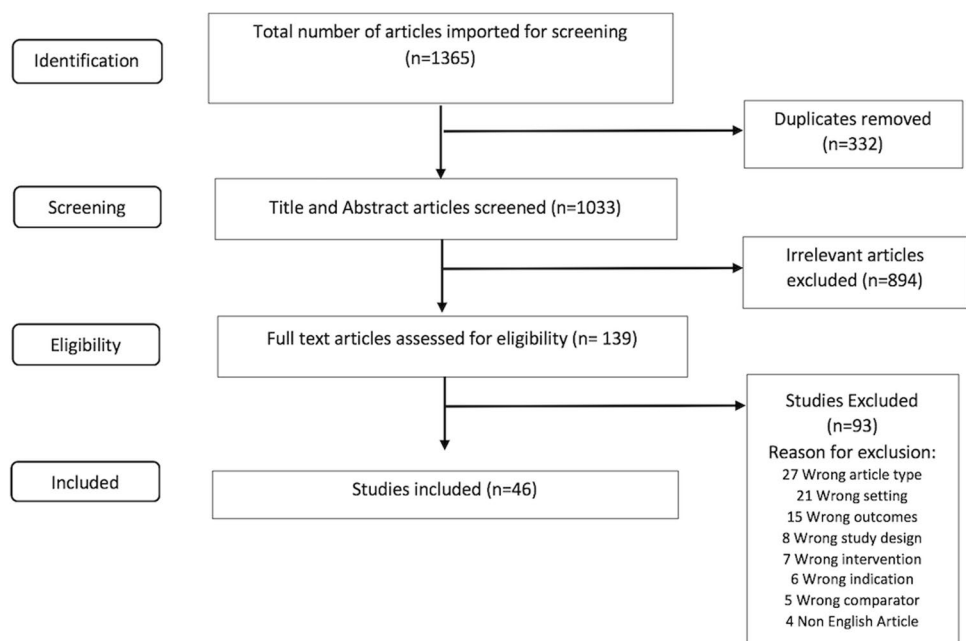
Publication bias was assessed by Begg's [9] test and the funnel plot was analyzed for visual determination of asymmetry if the assessed outcomes had at least 10 studies [26]. If presence of publication bias was confirmed, the trim and fill method was used to estimate the possible number of missing studies, which were then imputed to recalculate the new pooled effect estimate. As all the studies included in the analysis were case series, the quality of the studies was assessed by a questionnaire by Chan and Bhanushali [14]. The questionnaire assessed all studies based on whether their objective, protocol, inclusion and exclusion criteria, time interval, and patient enrollment were well defined and if the studies had a prospective collection of outcome data and a high follow-up. Each category had one point associated to it with the highest possible score of 8. Studies with higher scores on the questionnaire were assessed to be of better quality.

## Results

### Search results and characteristics

The electronic search yielded a total of 1365 studies [PubMed (743), EMBASE (602) and Cochrane (20)]. Of all imported studies, 1033 studies were screened and 46 case series [1–3, 6–8, 10–13, 15, 18–21, 23–25, 29, 30, 33–35, 37, 39–60] were used for the final meta-analysis (Fig. 1). The study timing for 39 studies was retrospective, while 7 studies were prospective. Patients in all age groups, from neonatal to geriatric population, were captured in the studies. The age range of the patients was 5 days–89 years and both naïve as well as previously shunted patients were included in the analysis. Out of the 46 case series with 3739 patients, 12 studies included adult population [7, 11, 13, 24, 25, 34, 35, 39, 40, 49, 50], 14 studies included pediatric population [1, 4, 7, 8, 12, 29, 33, 45, 46, 51, 58, 60], and 20 studies included patients from both groups [2, 10, 15, 19, 21, 23, 29, 30, 37, 41–44, 47, 52, 53, 55, 56, 59]. Regarding flexible ETV, 10 studies [23, 34, 35, 41, 42, 48, 52, 53, 57, 58] reported outcomes with a total of 821 patients, of whom 38 were adults, 126 were pediatric, and 657 were a mixture of adult and pediatric populations. For rigid ETV, 37 studies [1–4, 6–8, 10–13, 15, 18–21, 24, 25, 29, 30, 33, 37, 39, 40, 43–47, 49–51, 54–57, 59, 60] reported outcomes for a total of 2918 patients, of whom 1018 were adults, 747 were pediatric, and 1153 patients were a mixture of adult and pediatric populations. The types of hydrocephalus included were communicating hydrocephalus, non-communicating hydrocephalus, and normal pressure hydrocephalus (Table 1).

**Fig. 1** Study selection process of the identified articles



**Table 1** Characteristics of studies included in the systematic review and meta-analysis

| Author, Year                   | Endoscope (Rigid/Flexible) | Study Design, Timing       | Hydrocephalus type              | Etiology (no. of patients)  | Patient Population  | Age: Mean (range) unless otherwise specified | Male, n (%) | Study Quality* |
|--------------------------------|----------------------------|----------------------------|---------------------------------|---|---------------------|--|-------------|----------------|
| Abbassy et al., 2018 [1]       | Rigid                      | Case series, retrospective | Non-communicating hydrocephalus | Endodermal sinus tumor (1), Germi-noma (2), Grade II astrocytoma (1), Mixed germ-cell tumor (1), Pineo-blastoma (3), Pilo-cytic astrocytoma (1), Grade II tectal glioma (1), Pilocytic astrocytoma (1)  | Pediatric           | 11 years (1 year–17 years)                   | 10 (90.9%)  | 3              |
| Aranha et al., 2018 [3]        | Rigid                      | Case series, prospective   | Communicating hydrocephalus     | Tuberculous meningitis (TBM) Hydrocephalus  | Pediatric           | NR   | 15 (57.7%)  | 4              |
| Chiba et al., 2018 [15]        | Rigid                      | Case series, retrospective | Non-communicating hydrocephalus | Aqueductal stenosis (3), Cerebellar tumor (2), Intraven-tricular hemor-rhage (3), Pineal tumor (13), Fourth ventricle tumor (2), Brainstem tumor (1), Tectal tumor (3), Brain metas-tasis (1), Isolated fourth ventricle (1), Bilateral thalamic glioma (1) | Adult and Pediatric | 31.4 years (0.3 years–74 years)              | 17 (56.7%)  | 5              |
| Torres-Corzo et al., 2018 [52] | Flexible                   | Case series, retrospective | Non-communicating hydrocephalus | NR  | Mixed               | 20.45 years                                  | 25 (52%)    | 4              |
| Uche et al., 2018 [54]         | Rigid                      | Case series, prospective   | Non-communicating hydrocephalus | Aqueductal stenosis (37), Dandy-Walker malformation (7), Arnold-Chiari malformation (8), Intraventricular cyst loculations (3)  | Pediatric           | 2.3 years (3 months–4.5 years)               | 37 (67%)    | 5              |
| Wu et al., 2018 [59]           | Rigid                      | Case series, retrospective | Non-communicating hydrocephalus | Chiari type I malfor-mation (10)  | Adult and Pediatric | 28.14 years (0.75 years–55 years)            | 4 (40%)     | 5              |

Table 1 (continued)

| Author, Year               | Endoscope (Rigid/Flexible) | Study Design, Timing       | Hydrocephalus type              | Etiology (no. of patients)  | Patient Population  | Age: Mean (range) unless otherwise specified | Male, n (%) | Study Quality* |
|----------------------------|----------------------------|----------------------------|---------------------------------|---|---------------------|--|-------------|----------------|
| Sufianov et al., 2018 [51] | Rigid                      | Case series, prospective   | Non-communicating hydrocephalus | Aqueductal stenosis (21), Post hemorrhagic hydrocephalus (25), Post-infectious hydrocephalus (11), Dandy-Walker malformation (4), Myelomeningocele (3)              | Pediatric           | NR   | 34 (53.1%)  | 4              |
| Aref et al., 2017 [4]      | Rigid                      | Case series, retrospective | Nr                              | Normal pressure hydrocephalus (40), Obstructive tumor (46), Aqueductal stenosis (18), Hemorrhage (3), Unknown etiology (19), Trauma (3), Tuberculosis (1), Cyst (7) | Adult               | 51.7 years                                   | 82 (62%)    | 4              |
| Oertel et al., 2017 [43]   | Rigid                      | Case series, retrospective | Non-communicating hydrocephalus | Benign aqueductal stenosis (40), Tumor (35), Infection/hemorrhage (15), Intracranial cysts (13), Other (10)   | Adult and Pediatric | NR   | 58 (51.3%)  | 2              |

Table 1 (continued)

| Author, Year                | Endoscope (Rigid/Flexible) | Study Design, Timing       | Hydrocephalus type   | Etiology (no. of patients)  | Patient Population | Age: Mean (range) unless otherwise specified       | Male, n (%) | Study Quality* |
|-----------------------------|----------------------------|----------------------------|--|---|--------------------|--|-------------|----------------|
| Wang et al., 2017 [57]      | Rigid                      | Case series, retrospective | Nr   | Post-hemorrhagic hydrocephalus (25), Aqueductal stenosis (21), Myelomeningocele (23), Dandy-Walker complex (6), Congenital idiopathic hydrocephalus (4), Postinfectious hydrocephalus (6), Other etiology (6)     | Pediatric          | Median = 3.5 months<br>IQR = 1.2 months–5.7 months | 45 (52.9%)  | 5              |
|                             | Flexible                   | Case series, retrospective | Nr   | Post-hemorrhagic hydrocephalus (44), Aqueductal stenosis (12), Myelomeningocele (7), Dandy-Walker malformation (6), Congenital idiopathic hydrocephalus (6), Postinfectious hydrocephalus (5), Other etiology (5) | Pediatric          | Median = 3.2 months<br>IQR = 0.7 months–6.8 months | 50 (54.9%)  | 5              |
| Rodriguez et al., 2017 [58] | Flexible                   | Case series, retrospective | Nr   | Tumor (20), infectious or due to parasites (75), Post-hemorrhagic (16), Congenital (39)   | Mixed              | (4 days–76 years)                                  | 76 (51%)    | 5              |
| Zhao et al., 2016 [60]      | Rigid                      | Case series, retrospective | Non-communicating hydrocephalus (24), communicating hydrocephalus (13) | Posterior fossa tumor or pineal tumor (9), Idiopathic aqueduct stenosis (15), Postmeningitis (8), Post-hemorrhagic (3)  | Pediatric          | (8 months–36 months)<br>Median = 21.6 months       | NR          | 4              |

Table 1 (continued)

| Author, Year               | Endoscope (Rigid/Flexible) | Study Design, Timing       | Hydrocephalus type  | Etiology (no. of patients)  | Patient Population | Age: Mean (range) unless otherwise specified | Male, n (%)  | Study Quality* |
|----------------------------|----------------------------|----------------------------|---|---|--------------------|--|--------------|----------------|
| Grand et al., 2016 [24]    | Rigid                      | Case series, retrospective | Nr  | Aqueduct stenosis (56), Intraventricular hemorrhage (20), Remote head trauma (57), Post-craniotomy for posterior fossa tumor (14), Subarachnoid hemorrhage (23), Tumor or cyst (42), Shunt obstruction (23), Other cause (8)  | Adult              | 51 years (17 years–88 years)                 | 128 (52.7%)  | 4              |
| Kawsar et al., 2015 [30]   | Rigid                      | Case series, retrospective | Nr  | Aqueductal stenosis (210), Posterior fossa tumors (74), Cysts (56), Previous ventriculitis (49), Shunt failure (8), Posterior fossa hemorrhage (6), Hydrocephalus due to Chiari malformation (6), Congenital fourth ventricular outflow obstruction (2) Hydrocephalus w/ empty sella syndrome (1) | Mixed              | NR   | 224 (54.37%) | 4              |
| Niknejad et al., 2015 [39] | Rigid                      | Case series, retrospective | Tri-ventricular hydrocephalus (14), communicating hydrocephalus (1), quadri-ventricular hydrocephalus (1) | Tumor (8), Giant basilar tip aneurysm (1), Normal pressure hydrocephalus (1), idiopathic aqueductal stenosis (3), post-hemorrhagic (1), Tuberculous meningitis (1), Wegener granuloma (1)   | Adult              | 72.8 years (66 years–83 years)               | 11 (68.75%)  | 5              |
| Obaid et al., 2015 [40]    | Rigid                      | Case series, retrospective | Non-communicating hydrocephalus   | Intraventricular hemorrhage   | Adult              | 58 years (42 years–79 years)                 | 9 (52.94%)   | 5              |

Table 1 (continued)

| Author, Year                    | Endoscope (Rigid/Flexible) | Study Design, Timing       | Hydrocephalus type              | Etiology (no. of patients)  | Patient Population  | Age: Mean (range) unless otherwise specified | Male, n (%) | Study Quality* |
|---------------------------------|----------------------------|----------------------------|---------------------------------|---|---------------------|--|-------------|----------------|
| Vulcu et al., 2015 [56]         | Rigid                      | Case series, retrospective | Nr                              | Benign aqueductal stenosis (40), Tumor (35), Infection/hemorrhage (15), Intracranial cysts (13), Other (10)   | Mixed               | 35 years (8 days–77 years)                   | 58 (51.3%)  | 4              |
| Bisht et al., 2014 [10]         | Rigid                      | Case series, retrospective | Non-communicating hydrocephalus | Congenital aqueductal stenosis  | Adult and Pediatric | 7.45 years (1 month–52 years)                | 79 (77.45%) | 6              |
| Salvador et al., 2014 [47]      | Rigid                      | Case series, retrospective | Non-communicating hydrocephalus | Congenital malformations (74), Tumor (52), Cysts (15), Infection (12), Hemorrhage (11)  | Adult and Pediatric | 22.1 years                                   | 98 (60%)    | 6              |
| Stachura et al., 2014 [50]      | Rigid                      | Case series, retrospective | Non-communicating hydrocephalus | Primary aqueductal stenosis (24), Brain tumor (61), Basilar tip aneurysm (2), Undetermined (9)  | Adult               | 47 years (18 years–82 years)                 | 55 (57.3%)  | 2              |
| Ali et al., 2013 [2]            | Rigid                      | Case series, retrospective | Non-communicating hydrocephalus | Posterior fossa tumor (83), Aqueductal stenosis (37), Non tectal tumor (8), CP angle tumor (7), Tectal tumor (7), Posterior fossa abscess (3), Posterior fossa hematoma (2) | Mixed               | 15 years (6 months–60 years)                 | 72 (46.45%) | 5              |
| Brusius & Cavalleiro, 2013 [12] | Rigid                      | Case series, prospective   | Non-communicating hydrocephalus | Blake pouch cyst (8)  | Pediatric           | 13.25 months (1 month–48 months)             | 5 (62.5%)   | 7              |
| Melot et al., 2013 [37]         | Rigid                      | Case series, retrospective | Non-communicating hydrocephalus | Malformation (43), Mass lesion (35), Post-infectious (4)  | Adult and Pediatric | NR   | NR          | 4              |
| Romeo et al., 2013 [46]         | Rigid                      | Case series, retrospective | Non-communicating hydrocephalus | Tectal plate gliomas  | Pediatric           | 11.6 years (4 years–18 years)                | 15 (68%)    | 3              |



Table 1 (continued)

| Author, Year               | Endoscope (Rigid/Flexible) | Study Design, Timing       | Hydrocephalus type              | Etiology (no. of patients)   | Patient Population | Age: Mean (range) unless otherwise specified | Male, n (%) | Study Quality* |
|----------------------------|----------------------------|----------------------------|---------------------------------|--|--------------------|--|-------------|----------------|
| Vogel et al., 2013 [55]    | Rigid                      | Case series, retrospective | Non-communicating hydrocephalus | Aqueductal stenosis (35), Nontectal tumor (23), Tectal tumor (16), Myelomeningocele (9), Intracranial cyst (6), Infection (3), Chiari malformation Type I (3)      | Mixed              | 19.7 years (5 months–77 years)               | 46 (48%)    | 4              |
| Bouramas et al., 2012 [11] | Rigid                      | Case series, retrospective | Non-communicating hydrocephalus | Aqueductal stenosis (30), Post infection (3), Cyst (5), Tumor (15), Hemorrhage (4)   | Adult              | (43 years–89 years)                          | 26 (48.14%) | 5              |
| Warf et al., 2012 [58]     | Flexible                   | Case series, retrospective | Non-communicating hydrocephalus | Congenital aqueductal stenosis   | Pediatric          | NR   | 19 (54.28%) | 4              |
| Durnford et al., 2011 [19] | Rigid                      | Case series, retrospective | Non-communicating hydrocephalus | Aqueductal stenosis (40), Nontectal tumor (39), Intraventricular Hemorrhage (23), Tectal tumor (15), Myelomeningocele (5), Post-infectious (7), Other (37)         | Mixed              | (0 years–19 years)                           | 95 (57.2%)  | 4              |
| Egger et al., 2010 [20]    | Rigid                      | Case series, retrospective | Non-communicating hydrocephalus | Cyst (4), Tumor (4), Chiari II Malformation and myelomeningocele (3), Aqueductal stenosis (3)  | Pediatric          | Median = 3 years 4 months                    | 6 (42.8%)   | 5              |
| Ogigawa et al., 2010 [45]  | Rigid                      | Case series, retrospective | Non-communicating hydrocephalus | Congenital aqueduct stenosis (1), Post-hemorrhagic obstruction (6), Myelomeningocele (2), Post-meningitis (2), Chiari I malformation (1), Dandy walker variant (1) | Pediatric          | 87.7 days (5 days–158 days)                  | 14 (60.8%)  | 4              |

Table 1 (continued)

| Author, Year                   | Endoscope (Rigid/Flexible) | Study Design, Timing       | Hydrocephalus type  | Etiology (no. of patients)  | Patient Population | Age: Mean (range) unless otherwise specified | Male, n (%) | Study Quality* |
|--------------------------------|----------------------------|----------------------------|---|---|--------------------|--|-------------|----------------|
| Torres-Corzo et al., 2010 [53] | Flexible                   | Case series, retrospective | Non-communicating hydrocephalus   | Neurocysticercosis (86)   | Mixed              | (9 years–79 years)                           | 42 (56%)    | 4              |
| Oertel et al., 2009 [44]       | Rigid                      | Case series, prospective   | Non-communicating hydrocephalus   | Cerebellar hemorrhage (17), Thalamic hemorrhage (6), Intraventricular hemorrhage (5), basal ganglia hemorrhage (3), subarachnoid hemorrhage (2), pontine hemorrhage (1) | Mixed              | 60.8 years (3 months–83 years)               | 15 (44%)    | 6              |
| Ersahin & Arslan, 2008 [21]    | Rigid                      | Case series, retrospective | Non-communicating hydrocephalus   | Obstruction of fourth ventricular outlets, Dandy-Walker Malformation, Chiari Malformation type I, Chiari malformation type II, Aqueductal stenosis                      | Mixed              | 14.8 years (2 months–77 years)               | 85 (54.8%)  | 5              |
| Hailong et al., 2008 [25]      | Rigid                      | Case series, retrospective | Idiopathic normal pressure (17), secondary communicating hydrocephalus (15) | Idiopathic normal-pressure hydrocephalus (17), Tubercular meningitis (1), Trauma (9), Hypertensive intracranial hemorrhage (4), Subarachnoid hemorrhage (1)             | Adult              | 61.4 years                                   | 24 (75%)    | 3              |
| Lipina et al., 2008 [33]       | Rigid                      | Case series, retrospective | Non-communicating hydrocephalus   | Aqueductal stenosis (5), Peri and intraventricular hemorrhage (8), Hemorrhage and Infection (1)   | Pediatric          | 105 days                                     | 8 (57.1%)   | 5              |
| Idowu et al., 2008 [29]        | Rigid                      | Case series, prospective   | Non-communicating hydrocephalus   | Aqueductal stenosis (11), Dandy-Walker malformation (9), Myelomeningocele (4), Pineal region tumor(1)   | Mixed              | (4 weeks to 48 years) median = 6 months      | 14 (56%)    | 4              |

Table 1 (continued)

| Author, Year                 | Endoscope (Rigid/Flexible) | Study Design, Timing       | Hydrocephalus type              | Etiology (no. of patients)  | Patient Population | Age: Mean (range) unless otherwise specified | Male, n (%) | Study Quality* |
|------------------------------|----------------------------|----------------------------|---------------------------------|---|--------------------|--|-------------|----------------|
| Baldauf et al., 2007 [7]     | Rigid                      | Case series, retrospective | Non-communicating hydrocephalus | Idiopathic aqueductal stenosis (8), Other congenital anomalies (4), Post-hemorrhagic (3), Tumor-related (3), Shunt infection (2), Shunt failure (1)               | Pediatric          | 6.7 months                                   | 15 (71.4%)  | 3              |
| Baldauf et al., 2006 [6]     | Rigid                      | Case series, retrospective | Non-communicating hydrocephalus | cerebellar infarction   | Adult              | 62 years (25 years–85 years)                 | 5 (55%)     | 4              |
| O'Brien et al., 2006 [41]    | Flexible                   | Case series, retrospective | Non-communicating hydrocephalus | NR  | Mixed              | 37 years (5 years–77 years)<br>Median = 33   | 21 (50%)    | 3              |
| Baykan et al., 2005 [8]      | Rigid                      | Case series, retrospective | Non-communicating hydrocephalus | NR  | Pediatric          | (2 months–10 years)                          | 120 (57.1%) | 5              |
| O'Brien et al., 2005 [42]    | Flexible                   | Case series, retrospective | Non-communicating hydrocephalus | Spina bifida, aqueductal stenosis, arachnoid cysts, primary infective and haemorrhagic origin   | Mixed              | 27.78 (37 weeks–77 years)                    | NR          | 4              |
|                              | Flexible                   | Case series, retrospective | Non-communicating hydrocephalus | Spina bifida, aqueductal stenosis, arachnoid cysts, primary infective and haemorrhagic origin (IVH)   | Mixed              | 20.43 (9 months–69 years)                    | NR          | 4              |
| Santamarta et al., 2005 [49] | Rigid                      | Case series, retrospective | Non-communicating hydrocephalus | Primary aqueductal stenosis (27), Tumoural (30), Non-tumoural (haemorrhage, cysts) (9)  | Adult              | Median = 53 IQR = 27–67                      | 33 (50%)    | 5              |
| Longatti et al., 2004 [34]   | Flexible                   | Case series, retrospective | Non-communicating hydrocephalus | Primitive aqueductal stenosis (3) secondary CSF pathway obstruction (11) frontal cystic glioblastoma (1) normal pressure hydrocephalus (6) previously shunted (3) | Adult              | (35 years–82 years)<br>Median = 59.5         | 14 (58.3%)  | 5              |

Table 1 (continued)

| Author, Year               | Endoscope (Rigid/Flexible) | Study Design, Timing   | Hydrocephalus type  | Etiology (no. of patients)   | Patient Population | Age: Mean (range) unless otherwise specified | Male, n (%) | Study Quality* |
|----------------------------|----------------------------|--|---|--|--------------------|--|-------------|----------------|
| Longatti et al., 2004 [35] | Flexible                   | Case series, retrospective   | Normal pressure hydrocephalus   | NR   | Adult              | (66 years–78 years)                          | 8 (57.1%)   | 5              |
| Buxton et al., 2001 [13]   | Rigid                      | Case series, retrospective until August 1994, post August 1994 prospective | Non communicating hydrocephalus (44), communicating hydrocephalus (9)   | Third ventricular tumor (22), Aqueduct stenosis (18), Third ventricular arachnoid cyst (4), Infection (4), SAH/Post haemorrhagic (2) Myelomeningocele (4), Other (4) Hydrocephalus cause (3)                   | Adult              | 37.5 years (17 years–77 years)               | 38 (60.3%)  | 7              |
| Gangemi et al., 1999 [23]  | Flexible                   | Case series, retrospective   | Triventricular hydrocephalus (110), tetraventricular hydrocephalus (15) | Primary aqueductal stenosis (77) mesencephalic tumors (16), pineal region tumors (9) posterior fossa tumors (8) blockage in the posterior fossa (11) subarachnoid hemorrhage (3), infection due to Candida (1) | Mixed              | 31 years (7 days–81 years)                   | 72 (57.6%)  | 6              |

\* Study quality (Median 4, IQR 4–5) was assessed based on the quality assessment questionnaire for case series based on Chan and Bhandari

### Efficacy (ETV failure) analysis

Flexible ETV showed a higher incidence of failure compared with rigid ETV in adults (54% vs 20%) (Fig. 2), while a smaller difference was found in pediatric patients (36% flexible vs 32% rigid) (Fig. 3) and mixed age patients (23% flexible vs 22% rigid) (Fig. 4) (Table 2).

### Safety analysis (complications, bleeding, death)

Even though pooled results could not be compared with a statistical *p* value, it was worth exploring the trends resulting from our analysis. Flexible endoscopy presented an overall lower incidence of complications in pediatric (2 vs 18%) and mixed populations (8 vs 11%) but not in adults (13 vs 9%) when compared with the rigid approach (Table 3, Appendix 2). Flexible endoscopy presented an overall trend towards lower incidence of intra-operative bleeding in the mixed age category (4 vs 6%) but not in the adult category (8 vs 6%) when compared with the rigid approach. No studies conducted in pediatrics presented data on intra-operative bleeding (Table 3, Appendix 3). Flexible endoscopy reported lower incidence of death related to surgery in each age group (pediatric 1 vs 3%, adult 4 vs 6%, mixed 1.2 vs 1.7%) when compared with the rigid approach (Table 3, Appendix 4).

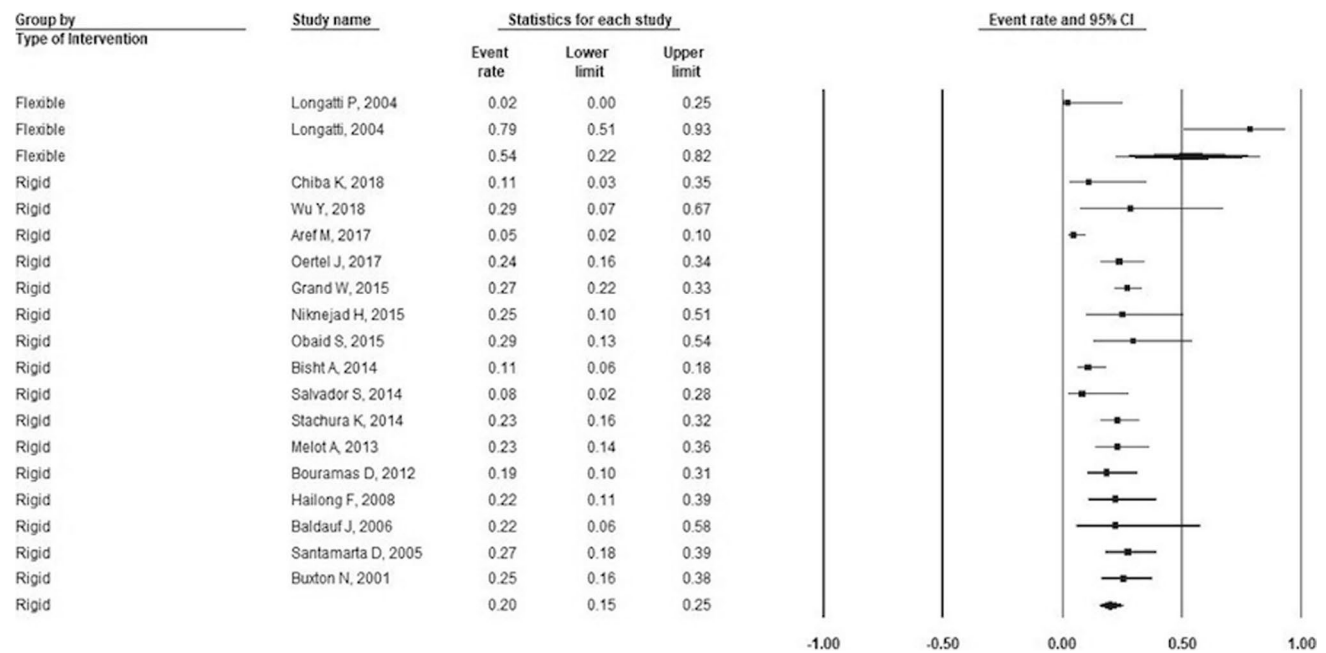
### Quality score and bias assessment

The quality score for all studies ranged from 2 to 7 with a median score of 4 (IQR 4–5) (Appendix 5) on the Chan and Bhanushali questionnaire. Only 7 studies had a quality score < median [1,7,25,41,43,46,50,]. All studies had a well-defined study objective and clinically relevant outcomes. The majority of them had well-defined protocols and high follow-up rates. A few studies did not report explicit inclusion/exclusion criteria, time interval, and consecutive patient enrollment. Only seven studies had prospective data collection. Only the rigid endoscopy group with regard of the incidence of failure had more than 10 studies in their analysis for each of the adult and pediatric populations.

The funnel plot for the incidence of failure using the rigid endoscopy did not show obvious signs of asymmetry in adult population (Fig. 5a) or pediatric population (Fig. 5b), which suggested the absence of publication bias. The Begg’s test for each was not statistically significant, further confirming these findings (*p* value: 0.22 in adults; *p* value: 0.55 in pediatrics).

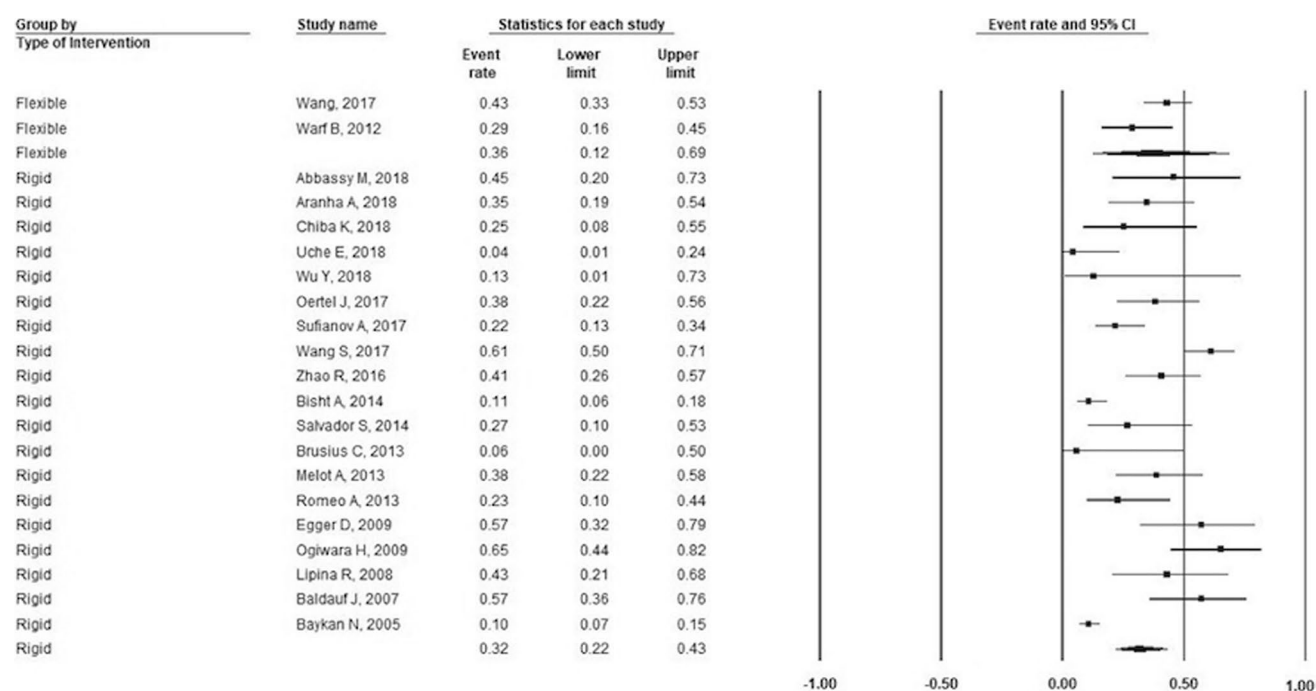
### Sensitivity analysis

All of the above analyses did not materially change when we excluded studies with a quality score below the median level (<4) (Appendices 6 and 7).



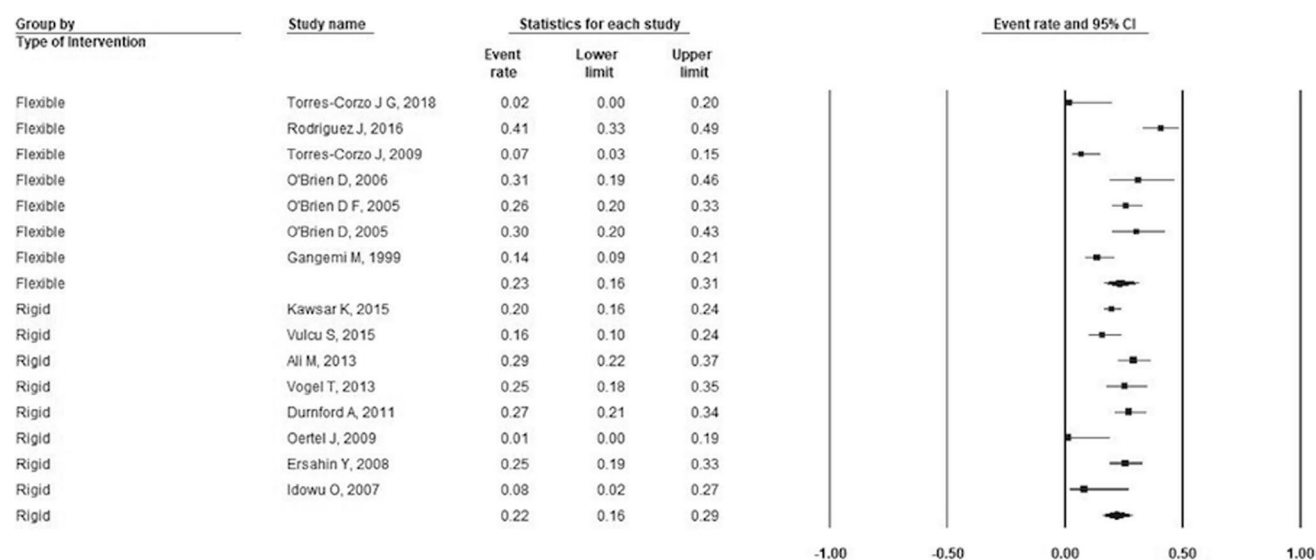
**Fig. 2** Forest plot for incidence of failure in adults stratified by endoscopy type. For flexible ETV: incidence of failure=54%; number of studies=2; P-heterogeneity=0.001; I<sup>2</sup>=90.9%; for rigid ETV:

incidence of failure: 20% number of studies=16; P-heterogeneity=0.002; I<sup>2</sup>=57.4%. Error bars represent the 95% CI. ETV: endoscopic third-ventriculostomy



**Fig. 3** Forest plot for incidence of failure in pediatric population stratified by endoscopy type. For flexible ETV: incidence of failure = 36%; number of studies = 2; P-heterogeneity = 0.14;  $I^2 = 53.2\%$ ;

for rigid ETV: incidence of failure = 32%; number of studies = 19; P-heterogeneity = 0.00;  $I^2 = 85.2\%$ . Error bars represent the 95% CI. ETV: endoscopic third-ventriculostomy



**Fig. 4** Forest plot for incidence of failure in mixed population stratified by endoscopy type. For flexible ETV: incidence of failure = 23%; number of studies = 7; P-heterogeneity = 0.00;  $I^2 = 86\%$ ; for rigid

ETV: incidence of failure = 22%; number of studies = 8; P-heterogeneity = 0.01;  $I^2 = 61\%$ . Error bars represent the 95% CI. ETV: endoscopic third-ventriculostomy

## Discussion

The results of this meta-analysis suggested the presence of better efficacy of rigid endoscopy for ETV performance in

adults. Safety profiles were mixed, while flexible endoscopy showed fewer complications in pediatrics and lower death events in pediatrics and adults, rigid endoscopy showed fewer complications and bleeding events in adults.

**Table 2** Pooled effect estimates for efficacy (failure)

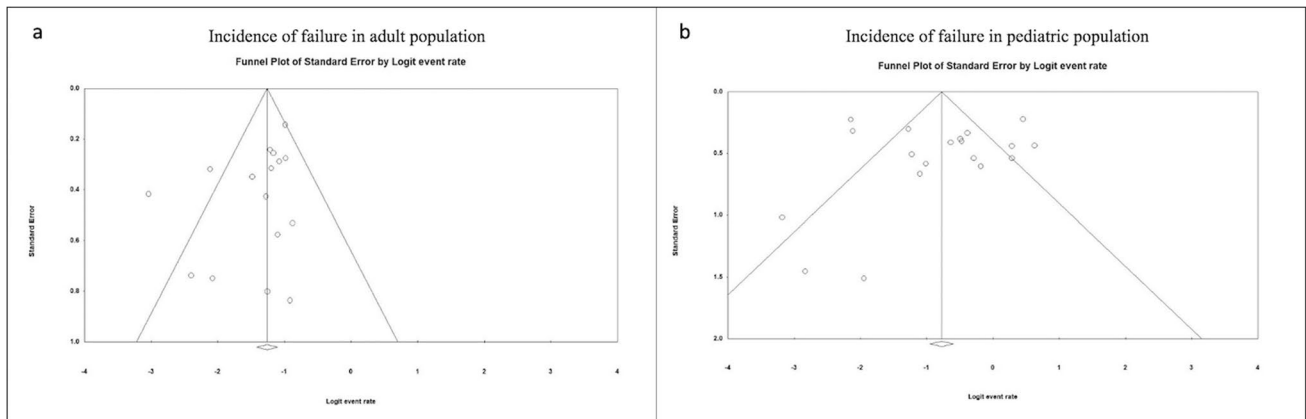
| Outcome | Population type; | Flexible ETV                |                      |              | Rigid ETV                   |                      |              |
|---------|------------------|-----------------------------|----------------------|--------------|-----------------------------|----------------------|--------------|
|         |                  | Pooled incidence (95% C.I.) | I <sup>2</sup> value | # of studies | Pooled incidence (95% C.I.) | I <sup>2</sup> value | # of studies |
| Failure | Pediatric        | 36% (12%, 66%)              | 53.2%                | 2            | 32% (22%, 43%)              | 85.2%                | 19           |
|         | Adult            | 54% (22%, 82%)              | 90.9%                | 2            | 20% (15%, 25%)              | 57.4%                | 16           |
|         | Mixed            | 23% (16%, 31%)              | 86%                  | 7            | 22% (16%, 27%)              | 61.6%                | 8            |

C.I.: Confidence interval

**Table 3** Pooled effect estimates for safety outcomes of complications, bleeding, and death

| Outcome       | Population; | Flexible ETV                |                      |              | Rigid ETV                   |                      |              |
|---------------|-------------|-----------------------------|----------------------|--------------|-----------------------------|----------------------|--------------|
|               |             | Pooled incidence (95% C.I.) | I <sup>2</sup> value | # of studies | Pooled incidence (95% C.I.) | I <sup>2</sup> value | # of studies |
| Complications | Pediatric   | 2% (0.1–34%)                | N.A                  | 1            | 18% (7–41%)                 | 90.8%                | 7            |
|               | Adult       | 13% (3–40%)                 | N.A                  | 1            | 9% (5–13%)                  | 55.9%                | 8            |
|               | Mixed       | 8% (5–11%)                  | 54%                  | 5            | 11% (8–16%)                 | 27.9%                | 4            |
| Bleeding      | Adult       | 8% (2–27%)                  | N.A                  | 1            | 6% (4–10%)                  | 0%                   | 4            |
|               | Mixed       | 4% (2–9%)                   | 19.1%                | 5            | 6% (2–13%)                  | 89.7%                | 4            |
| Death         | Pediatric   | 1% (0.1–3%)                 | 0%                   | 2            | 3% (1–5%)                   | 0%                   | 12           |
|               | Adult       | 4% (0.4–32%)                | 0%                   | 2            | 6% (2–13%)                  | 80.9%                | 10           |
|               | Mixed       | 1.2% (0.6–2.7%)             | 0%                   | 6            | 1.7% (1.1–2.8%)             | 0%                   | 7            |

CI confidence interval, NA not applicable



**Fig. 5** Funnel plots for incidence of failure in adult and pediatric populations undergoing rigid ETV. No evident signs of asymmetry are unveiled in adult (a) or pediatric (b) population. The Begg’s test

confirmed these findings (adult *p* value 0.22, pediatric *p* value 0.55). ETV: endoscopic third-ventriculostomy

Regarding the efficacy profile, the results for the adult group were limited by the availability of only two studies on flexible endoscopy [34, 35]. It is particularly important to notice that one of these two studies focused on patients suffering from normal pressure hydrocephalus, which is known to have overall better outcomes when treated with a shunt [35], given the non-obstructive nature of the disease [36]. Therefore, the efficacy results were more suggestive of the

fact that ETV was able to provide actual benefit to patients with hydrocephalus depending on its etiology, rather than providing evidence of an overall superiority of flexible or rigid approach over the other. The available literature has in fact already shown that both etiology and age are crucial factors to consider in the decision of treating hydrocephalus through a shunt or ETV, particularly in the pediatric population [31, 32].

In terms of safety, both flexible and rigid endoscopic approaches turned out to be procedures with acceptable peri-operative complication rates and very low occurrence of intra-operative bleeding and death. With regard to peri-operative complications, we could appreciate a trend towards a lower rate in the use of flexible approach, particularly in the pediatric population, but whether these comparisons would reach statistical significance is yet to be confirmed in future comparative studies. Flexible instruments are smaller and tend to be more delicate, which could at least in part explain our findings. With regard to intra-operative bleeding, the results need to be interpreted cautiously. The risk of bleeding depends also on the type of procedure performed during the endoscopy: a patient who undergoes ETV alone has a reduced risk of experience bleeding compared to a patient who undergoes ETV along with the biopsy or partial resection of a tumor or again the cauterization of the choroid plexus, regardless the type of approach. Interestingly, no pediatrics study reported occurrence of intra-operative bleeding, even in the presence of choroid plexus cauterization. Moreover, the ability of the flexible endoscope to reach areas out of range for the rigid one, for example, the posterior half of the third ventricle, allows the surgeon to perform deeper maneuvers, hence exposing them to the related inherent risks. Regardless the approach and age group, intraoperative mortality was found to be a very rare event, confirming both flexible and rigid endoscopy as safe techniques.

The  $I^2$  value for most groups was reported to be high. The degree of heterogeneity could be explained by to the presence of other co-variables such as the type of hydrocephalus (communicating, non-communicating, and normal pressure hydrocephalus) and its etiology; however, we could not assess their effect in the determination of the results due to lack of data. Notably, study quality was not found to be a source of heterogeneity as the results were not altered after excluding the low-quality studies.

In the interpretation of the results of this study, a number of limitations needs to be taken into account. First, the presence of reporting imbalance in the two techniques; out of all the studies that were included in the final analysis, only 10 studies reported data on flexible ETV, while 36 studies reported data on rigid ETV. The study design consisted of case series and no other comparative studies. Due to the lack of randomized control trials or comparative (analytical) observational studies in the meta-analysis, results need to be interpreted with caution due to possible confounding bias and other biases typically present in case series. Hence, the  $p$  values comparing the pooled point estimates between the 2 techniques were not derived. A major challenge faced while conducting the study was that only one study (Wang et.al) [57] had data for both intervention arms directly compared in a propensity-score matched cohort study, which were included as separate

groups in this analysis. The study included only pediatrics and reported that rigid endoscopy had worse outcomes of failure as compared with flexible endoscopy, which was discordant with our findings. This begs the need for more well-designed studies in pediatrics and adults in order to accurately discern these differences. Notably, the type of hydrocephalus and its etiology could not be taken into account in the analysis due to lack of data, whereas in clinical practice, these two factors are part of the decision-making process in the choice of treatment strategy. Regardless, our aim was to evaluate efficacy and safety of two approaches that are both endoscopic in nature, therefore specific considerations about indications for alternative treatments as, for example, shunt diversion, were out the scope of this work.

Despite these limitations, our study had some strengths. To our knowledge, this was the first meta-analysis performed with the aim to evaluate efficacy and safety of flexible vs rigid ETV for the treatment of hydrocephalus. Another strength is the stratification of all safety and efficacy outcomes by age category, while shedding light on the available data in the entire neurosurgery literature and suggesting steps needed for better designed studies to address some uncertainties.

In conclusion, while our analysis could not depict a clear superiority in terms of efficacy with regard to flexible vs rigid endoscopy in the treatment of hydrocephalus, our results suggested that both approaches presented acceptable safety profiles, with some degree of variability between age categories. Moving forward, well-designed randomized controlled trials and comparative observational studies with larger sample sizes including patients of different ages, types, and etiology of hydrocephalus are needed in order to assess the optimal treatment options between rigid ETV and flexible ETV for hydrocephalus treatment.

**Supplementary Information** The online version contains supplementary material available at <https://doi.org/10.1007/s10143-021-01590-6>.

**Authors' contribution** AB was the proponent of the idea for this article and contributed to manuscript draft and review. BM performed the literature search and manuscript drafting; data analysis was performed by BM and SC under the supervision of RAM. AP, FS, SD, AMA contributed to paper screening and manuscript review. A Feletti, A Fiorindi, PL, and FS contributed to critical revision of the manuscript. TRS and RAM contributed to data analysis, critical revision, and supervision of the work.

**Funding** Open access funding provided by Università degli Studi di Verona within the CRUI-CARE Agreement. No funding was received to assist with the preparation of this manuscript.

**Data availability** Not applicable.

**Code availability** Not applicable.



## Declarations

**Ethics approval** Not applicable.

**Consent to participate** Not applicable.

**Consent for publication** Not applicable.

**Conflict of interest** No conflict of interest or competing interests to report related to this work.

**Open Access** This article is licensed under a Creative Commons Attribution 4.0 International License, which permits use, sharing, adaptation, distribution and reproduction in any medium or format, as long as you give appropriate credit to the original author(s) and the source, provide a link to the Creative Commons licence, and indicate if changes were made. The images or other third party material in this article are included in the article's Creative Commons licence, unless indicated otherwise in a credit line to the material. If material is not included in the article's Creative Commons licence and your intended use is not permitted by statutory regulation or exceeds the permitted use, you will need to obtain permission directly from the copyright holder. To view a copy of this licence, visit <http://creativecommons.org/licenses/by/4.0/>.

## References

- Abbassy M, Aref K, Farhoud A, Hekal A. (2018) Outcome of single-trajectory rigid endoscopic third ventriculostomy and biopsy in the management algorithm of pineal region tumors: a case series and review of the literature. *Childs Nerv Syst.* 1–10.
- Ali M, Usman M, Khan Z et al (2013) Endoscopic third ventriculostomy for obstructive hydrocephalus. *J Coll Physicians Surg Pak* 23(5):338–341
- Aranha A, Choudhary A, Bhaskar S, Gupta LN (2018) A Randomized Study Comparing Endoscopic Third Ventriculostomy versus Ventriculoperitoneal Shunt in the Management of Hydrocephalus Due to Tuberculous Meningitis. *Asian J Neurosurg* 13(4):1140–1147
- Aref M, Martyniuk A, Nath S et al (2017) Endoscopic Third Ventriculostomy: Outcome Analysis of an Anterior Entry Point. *World Neurosurg* 104:554–559
- Azab WA, Nasim K, Salaheddin W (2014) An overview of the current surgical options for pineal region tumors. *Surg Neurol Int* 5:39
- Baldauf J, Oertel J, Gaab MR, Schroeder HW (2006) Endoscopic third ventriculostomy for occlusive hydrocephalus caused by cerebellar infarction. *Neurosurgery* 59(3):539–544
- Baldauf J, Oertel J, Gaab MR, Schroeder HW (2007) Endoscopic third ventriculostomy in children younger than 2 years of age. *Childs Nerv Syst* 23(6):623–626
- Baykan N, Isbir O, Gercek A et al (2005) Ten years of experience with pediatric neuroendoscopic third ventriculostomy: features and perioperative complications of 210 cases. *J Neurosurg Anesthesiol* 17(1):33–37
- Begg CB, Mazumdar M (1994) Operating characteristics of a rank correlation test for publication bias. *Biometrics* 50(4):1088–1101
- Bisht A, Suri A, Bansal S et al (2014) Factors affecting surgical outcome of endoscopic third ventriculostomy in congenital hydrocephalus. *J Clin Neurosci* 21(9):1483–1489
- Bouramas D, Paidakakos N, Sotiriou F et al (2012) Endoscopic third ventriculostomy in obstructive hydrocephalus: surgical technique and pitfalls. *Acta Neurochir Suppl* 113:135–139
- Brusius CV, Cavalheiro S (2013) Endoscopic third ventriculostomy is a safe and effective procedure for the treatment of Blake's pouch cyst. *Arq Neuropsiquiatr* 71(8):545–548
- Buxton N, Ho KJ, Macarthur D et al (2001) Neuroendoscopic third ventriculostomy for hydrocephalus in adults: Report of a single unit's experience with 63 cases. *Surg Neurol* 55(2):74–78
- Chan K, Bhandari M (2011) Three-minute critical appraisal of a case series article. *Indian J Orthop* 45(2):103–104
- Chiba K, Aihara Y, Kawamata T (2018) A new optimal marker to evaluate the effectiveness of endoscopic third ventriculostomy during operation: "Folding Sign." *World Neurosurg* 119:e138–e144
- Chowdhry SA, Cohen AR (2013) Intraventricular neuroendoscopy: complication avoidance and management. *World Neurosurg* 79(2 Suppl):e11–10
- Covidence systematic review software, Veritas Health Innovation, Melbourne, Australia. Available at [www.covidence.org](http://www.covidence.org). Accessed 13 Nov 2019
- Demerdash A, Rocque BG, Johnston J et al (2017) Endoscopic third ventriculostomy: A historical review. *Br J Neurosurg* 31(1):28–32
- Durnford AJ, Kirkham FJ, Mathad N, Sparrow OC (2011) Endoscopic third ventriculostomy in the treatment of childhood hydrocephalus: validation of a success score that predicts long-term outcome. *J Neurosurg Pediatr* 8(5):489–493
- Egger D, Balmer B, Altermatt S, Meuli M (2010) Third ventriculostomy in a single pediatric surgical unit. *Childs Nerv Syst* 26(1):93–99
- Ersahin Y, Arslan D (2008) Complications of endoscopic third ventriculostomy. *Childs Nerv Syst* 24(8):943–948
- Friedman GN, Grannan BL, Nahed BV, Codd PJ (2015) Initial Experience with High-Definition Camera-On-a-Chip Flexible Endoscopy for Intraventricular Neurosurgery. *World Neurosurg* 84(6):2053–2058
- Gangemi M, Donati P, Maiuri F et al (1999) Endoscopic third ventriculostomy for hydrocephalus. *Minim Invasive Neurosurg* 42(3):128–132
- Grand W, Leonardo J, Chamczuk AJ, Korus AJ (2016) Endoscopic Third Ventriculostomy in 250 Adults With Hydrocephalus: Patient Selection, Outcomes, and Complications. *Neurosurgery* 78(1):109–119
- Hailong F, Guangfu H, Haibin T et al (2008) Endoscopic third ventriculostomy in the management of communicating hydrocephalus: a preliminary study. *J Neurosurg* 109(5):923–930
- Higgins JPT, Thomas J, Chandler J, et al. (2019) *Cochrane Handbook for Systematic Reviews of Interventions*.
- Higgins JP, Thompson SG, Deeks JJ, Altman DG (2003) Measuring inconsistency in meta-analyses. *BMJ* 327(7414):557–560
- Higgins JP, Thompson SG (2002) Quantifying heterogeneity in a meta-analysis. *Stat Med* 21(11):1539–1558
- Idowu O, Doherty A, Tiamiyu O (2008) Initial experience with endoscopic third ventriculostomy in Nigeria. *West Africa Childs Nerv Syst* 24(2):253–255
- Kawsar KA, Haque MR, Chowdhury FH (2015) Avoidance and management of perioperative complications of endoscopic third ventriculostomy: the Dhaka experience. *J Neurosurg* 123(6):1414–1419
- Kulkarni AV, Drake JM, Kestle JR, Mallucci CL, Sgouros S, Constantini S, Canadian Pediatric Neurosurgery Study Group (2010) Predicting who will benefit from endoscopic third ventriculostomy compared with shunt insertion in childhood hydrocephalus using the ETV Success Score. *J Neurosurg Pediatr* 6(4):310–5

32. Kulkarni AV, Drake JM, Mallucci CL, Sgouros S, Roth J, Constantini S, Canadian Pediatric Neurosurgery Study Group (2009) Endoscopic third ventriculostomy in the treatment of childhood hydrocephalus. *J Pediatr* 155(2):254–9.e1
33. Lipina R, Reguli S, Dolezilova V et al (2008) Endoscopic third ventriculostomy for obstructive hydrocephalus in children younger than 6 months of age: is it a first-choice method? *Childs Nerv Syst* 24(9):1021–1027
34. Longatti PL, Barzoi G, Paccagnella F et al (2004) A simplified endoscopic third ventriculostomy under local anesthesia. *Minim Invasive Neurosurg* 47(2):90–92
35. Longatti PL, Fiorindi A, Martinuzzi A (2004) Failure of endoscopic third ventriculostomy in the treatment of idiopathic normal pressure hydrocephalus. *Minim Invasive Neurosurg* 47(6):342–345
36. McGirt MJ, Woodworth G, Coon AL et al (2005) Diagnosis, treatment, and analysis of long-term outcomes in idiopathic normal-pressure hydrocephalus. *Neurosurgery* 57(4):699–705
37. Melot A, Curey-Leveque S, Derrey S et al (2013) Endoscopic 3rd ventriculocisternostomy: Procedural complications and long-term dysfunctions? *Neurochirurgie* 59(4–5):165–170
38. Morgenstern PF, Osbun N, Schwartz TH et al (2011) Pineal region tumors: an optimal approach for simultaneous endoscopic third ventriculostomy and biopsy. *Neurosurg Focus* 30(4):E3
39. Niknejad HR, Depreitere B, De Vleeschouwer S et al (2015) Results of endoscopic third ventriculostomy in elderly patients >=65 years of age. *Clin Neurol Neurosurg* 130:48–54
40. Obaid S, Weil AG, Rahme R, Bojanowski MW (2015) Endoscopic third ventriculostomy for obstructive hydrocephalus due to intraventricular hemorrhage. *J Neurol Surg A Cent Eur Neurosurg* 76(2):99–111
41. O'Brien DF, Hayhurst C, Pizer B, Mallucci CL (2006) Outcomes in patients undergoing single-trajectory endoscopic third ventriculostomy and endoscopic biopsy for midline tumors presenting with obstructive hydrocephalus. *J Neurosurg* 105(3 Suppl):219–226
42. O'Brien DF, Javadpour M, Collins DR et al (2005) Endoscopic third ventriculostomy: an outcome analysis of primary cases and procedures performed after ventriculoperitoneal shunt malfunction. *J Neurosurg* 103(5 Suppl):393–400
43. Oertel J, Vulcu S, Eickele L et al (2017) Long-term follow-up of repeat endoscopic third ventriculostomy in obstructive hydrocephalus. *World Neurosurg* 99:556–565
44. Oertel JMK, Mondorf Y, Baldauf J et al (2009) Endoscopic third ventriculostomy for obstructive hydrocephalus due to intracranial hemorrhage with intraventricular extension: Clinical article. *J Neurosurg* 111(6):1119–1126
45. Ogiwara H, Dipatri AJ Jr, Alden TD et al (2010) Endoscopic third ventriculostomy for obstructive hydrocephalus in children younger than 6 months of age. *Childs Nerv Syst* 26(3):343–347
46. Romeo A, Naftel RP, Griessenauer CJ et al (2013) Long-term change in ventricular size following endoscopic third ventriculostomy for hydrocephalus due to tectal plate gliomas: Clinical article. *J Neurosurg Pediatr* 11(1):20–25
47. Salvador SF, Oliveira J, Pereira J et al (2014) Endoscopic third ventriculostomy in the management of hydrocephalus: Outcome analysis of 168 consecutive procedures. *Clin Neurol Neurosurg* 126:130–136
48. Sanchez Rodriguez JJ, Torres-Corzo J, Cervantes DS et al (2017) Influence of the State of the Subarachnoid Space of the Cranial Base in Hydrocephalus Resolution after Endoscopy. *J Neurol Surg A Cent Eur Neurosurg* 78(3):255–259
49. Santamarta D, Diaz Alvarez A, Goncalves JM, Hernandez J (2005) Outcome of endoscopic third ventriculostomy Results from an unselected series with noncommunicating hydrocephalus. *Acta Neurochir (Wien)* 147(4):377–382
50. Stachura K, Grzywna E, Kwinta BM, Moskala MM (2014) Endoscopic third ventriculostomy - Effectiveness of the procedure for obstructive hydrocephalus with different etiology in adults. *Wideochir Inne Tech Maloinwazyjne* 9(4):586–595
51. Sufianov AA, Kasper EM, Sufianov RA (2018) An optimized technique of endoscopic third ventriculocisternostomy (ETV) for children with occlusive hydrocephalus. *Neurosurg Rev* 41(3):851–859
52. Torres-Corzo JG, Islas-Aguilar MA, Cerecedo-Lopez CD (2018) Flexible Neuroendoscopic diagnosis and management of ventricular tumors: a retrospective cohort study. *World Neurosurg* 118:e707–e712
53. Torres-Corzo JG, Tapia-Perez JH, Vecchia RRD et al (2010) Endoscopic management of hydrocephalus due to neurocysticercosis. *Clin Neurol and Neurosurg* 112(1):11–16
54. Uche EO, Okorie C, Iloabachie I et al (2018) Endoscopic third ventriculostomy (ETV) and ventriculoperitoneal shunt (VPS) in non-communicating hydrocephalus (NCH): comparison of outcome profiles in Nigerian children. *Childs Nerv Syst* 34(9):1683–1689
55. Vogel TW, Bahuleyan B, Robinson S, Cohen AR (2013) The role of endoscopic third ventriculostomy in the treatment of hydrocephalus. *J Neurosurg Pediatr* 12(1):54–61
56. Vulcu S, Eickele L, Cinalli G et al (2015) Long-term results of endoscopic third ventriculostomy: an outcome analysis. *J Neurosurg* 123(6):1456–1462
57. Wang S, Stone S, Weil AG et al (2017) Comparative effectiveness of flexible versus rigid neuroendoscopy for endoscopic third ventriculostomy and choroid plexus cauterization: A propensity score-matched cohort and survival analysis. *J Neurosurg Pediatr* 19(5):585–591
58. Warf BC, Tracy S, Mugamba J (2012) Long-term outcome for endoscopic third ventriculostomy alone or in combination with choroid plexus cauterization for congenital aqueductal stenosis in African infants: Clinical article. *J Neurosurg Pediatr* 10(2):108–111
59. Wu Y, Li C, Zong X et al (2018) Application of endoscopic third ventriculostomy for treating hydrocephalus-correlated Chiari type I malformation in a single Chinese neurosurgery centre. *Neurosurg Rev* 41(1):249–254
60. Zhao R, Shi W, Yang H, Li H (2016) Endoscopic Third Ventriculostomy Instead of Shunt Revision in Children Younger Than 3 Years of Age. *World Neurosurg* 88:92–96

**Publisher's note** Springer Nature remains neutral with regard to jurisdictional claims in published maps and institutional affiliations.