
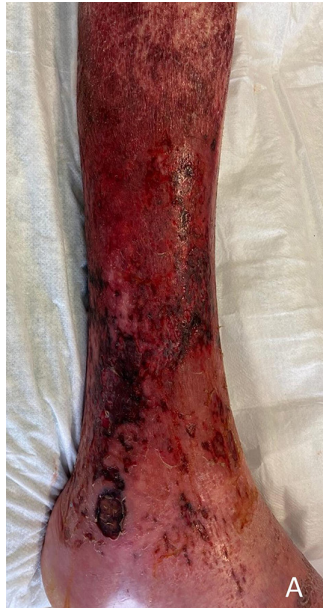
Scurvy as Presenting Sign of Anorexia Nervosa

Paolo Gisondi¹ and Francesco Bellinato¹ 


Journal of Cutaneous Medicine and Surgery
2022, Vol. 26(6) 645
© The Author(s) 2022
Article reuse guidelines:
sagepub.com/journals-permissions
DOI: 10.1177/12034754221100193
journals.sagepub.com/home/cms



A 59-year-old woman with history of anorexia nervosa presented with striped purpura and ecchymoses on the legs. Deficiency in serum vitamin C with levels <0.1 mg/dl (N.V. 0.2-2mg/dL) was found.

¹Department of Medicine, Section of Dermatology and Venereology, University of Verona, Verona, Italy. **Corresponding Author:** Francesco Bellinato, Section of Dermatology and Venereology, Department of Medicine, University of Verona, Piazzale A. Stefani 1, 37126 Verona, Italy; Email: francesco.bellinato@univr.it. The author has no conflicts of interest regarding this article, and has received no funding for this work.

ORCID iD

Francesco Bellinato  <https://orcid.org/0000-0002-6163-6921>