

# Leiomyosarcoma of the Larynx: A Complex Diagnosis

**Gabriele Molteni, MD<sup>1</sup>, Davide Soloperto, MD, PhD<sup>1</sup>,  
Cristoforo Fabbris, MD<sup>1</sup>, Luca Gazzini, MD<sup>1</sup>, Stefano De Rossi, MD<sup>1</sup>,  
Giovanni Valotto, MD<sup>2</sup>, and Daniele Marchioni, MD<sup>1</sup>**

## Case Report

An 84-year-old man was referred to our institution for dysphonia present for 2 months. Fiberoptic laryngoscopy demonstrated a polypoid lesion of the right true vocal fold with normal motility.

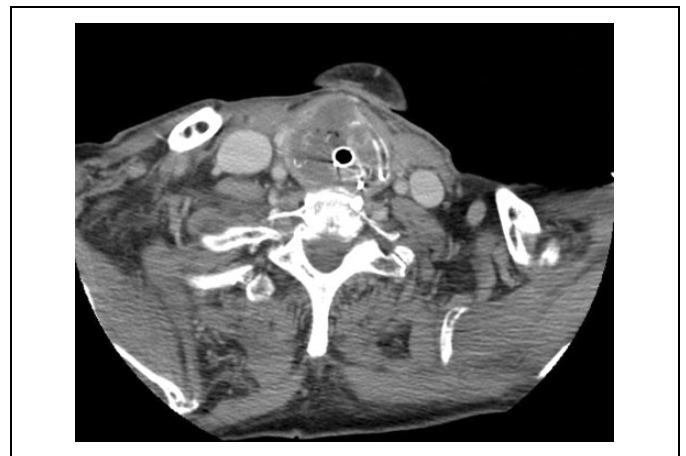Excisional biopsy of a submucosal thickening of the right vocal fold with vocal ligament calcification was performed. Histology revealed squamous cell epithelium without malignancy. Postoperative endoscopic follow-up was regular.

Six months after surgery, dysphonia and dyspnea occurred. Flexible laryngoscopy demonstrated right hemilaryngeal paralysis, edema, and partial airway obstruction. Necrotic tissue and purulent secretions were visible at the anterior commissure, right vocal fold, and ipsilateral vestibule. A second microlaryngoscopic surgery included multiple biopsies and debridement of the necrotic tissue. Histological report was negative for malignancy, and purulent chondritis was diagnosed. Intravenous antibiotic therapy was administered with improvement of infection, inflammation, dysphonia, and dyspnea. The patient was discharged.

Two months later, a new sudden and severe dyspnea occurred. He was admitted to the emergency department, and oropharyngeal intubation was necessary because of respiratory failure.

Computed tomography (CT) scan showed thickening of the right laryngeal wall with wide fluid collection (48-43 mm diameter) that almost completely obstructed the airway, with erosion of the right thyroid and cricoid cartilage (Figure 1).

Debridement of the necrotic tissue and drainage of the purulent collection was performed with direct laryngoscopy. Culture was positive for *Staphylococcus epidermidis* and *Candida albicans*. Intravenous antibiotic, antimicrobial, and corticosteroid therapy was administered, and other 3 surgical debridements and drainage were performed, but without clinical or radiological improvements. Moreover, patient developed signs of sepsis. Since no improvement had been achieved, total laryngectomy was planned even without a positive histologic biopsy. Intraoperative findings showed transglottic extension of the ulcerated material with full-thickness infiltration of the laryngeal wall and external spread through the thyroid



**Figure 1.** Computed tomography image showing an almost complete erosion of the laryngeal framework cartilages due to LLMS. Residual airway is minimal therefore an emergency oropharyngeal intubation is needed.

cartilage, with invasion of prelaryngeal tissues (Figure 2). The patient's clinical condition improved, and he started oral feeding without pharyngocutaneous fistula. Morphological and immunohistochemical features were consistent with leiomyosarcoma (Fédération Nationale des Centres de Lutte Contre Le Cancer [FNCLCC] grade 3; Figure 3).

Multidisciplinary consultation suggested adjuvant radiation therapy, but preirradiation staging CT scan showed rapid local recurrence and lung metastasis. The poor clinical condition of the patient contraindicated first-line chemotherapy.

<sup>1</sup> Otolaryngology Department, University Hospital of Verona, Verona, Italy

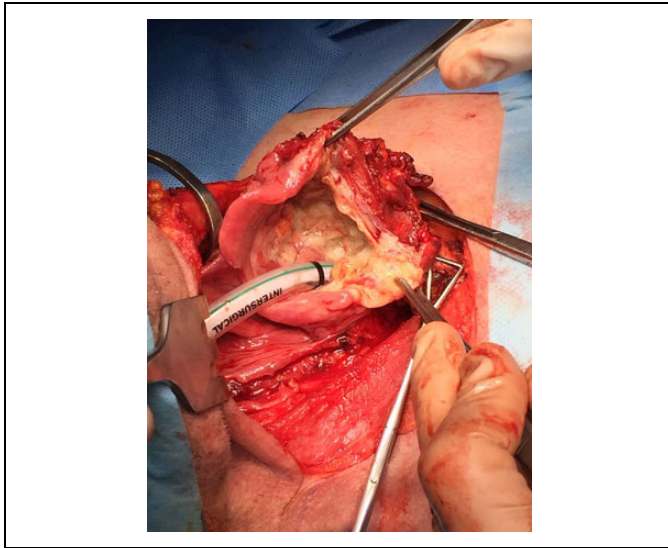
<sup>2</sup> Pathology Department, University Hospital of Verona, Verona, Italy

Received: August 19, 2018; revised: August 27, 2018; accepted: August 28, 2018

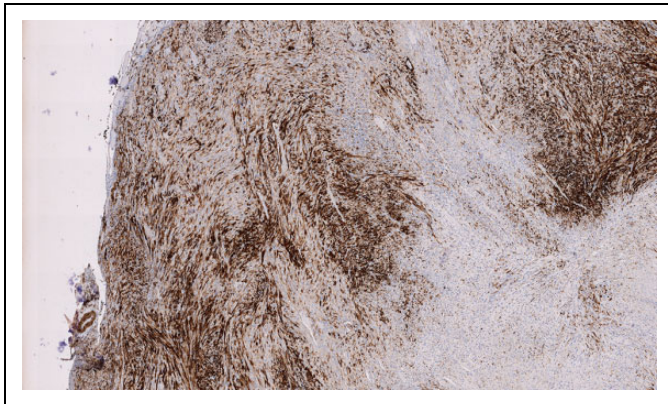
### Corresponding Author:

Cristoforo Fabbris, MD, Otolaryngology Department, University Hospital of Verona, Piazzale Aristide Stefani 1, Verona 37126, Italy.

Email: cristoforo.fabbris@gmail.com



**Figure 2.** Intraoperative picture showing the almost complete erosion of laryngeal cartilages with necrotic material substituting normal laryngeal tissue.



**Figure 3.** Histopathology of the lesion: SMA (smooth muscle specific actin) positivity demonstrates the smooth muscle nature of the neoplastic population. Written histological report shows a malignant neoplasm with spindle cells, high mitotic index (10-14 mitosis  $\times$  10HPF), and large areas of tissue necrosis (>50%).

At 3-month follow-up, the patient was alive and receiving best supportive care.

## Discussion

The first case of laryngeal leiomyosarcoma (LLMS) was reported by Jackson et al in 1939.<sup>1</sup> After that, fewer than 50 cases of LLMS have been reported in international literature,<sup>2</sup> including an 87-year-old man with laryngopyoceles and LLMS who was treated with total laryngectomy.<sup>3</sup>

Simultaneous presence of laryngeal carcinoma, laryngopyocoele, and laryngomucocele was described by Cassano et al,<sup>4</sup>

and Mitro et al,<sup>5</sup> but no leiomyosarcoma was found in these patients or in cases reviewed in similar articles.

Purulent chondritis of laryngeal cartilages (PCLC) is a very uncommon abscess that grows between inner and outer perichondria of the laryngeal framework. To date, only 5 cases have been described in the literature,<sup>6-8</sup> and none of them was associated with neoplasm.

In our case, radiological suspicion of laryngeal abscess and no clear radiological signs of malignant tumor were detectable. Laryngeal biopsies were negative for malignancy, and cultures were consistent with PCLC, but combined antibiotic therapy, surgical drainage, and debridement did not improve the clinical condition, and the patient developed sepsis. Fortunately, after total laryngectomy, his clinical condition improved quickly with complete sepsis resolution.

Etiology of LLMS is still unclear. A possible factor is an abnormal postoperative healing process.<sup>9</sup> In our case, the patient developed worsening dysphonia and dyspnea, 6 months after his first vocal fold biopsy with negative findings.

Treatment guidelines for LLMS are lacking due to its rarity. First-line treatment should be tumor resection with wide margins, reserving radiotherapy as adjuvant treatment or in case of recurrence or persistent tumor.<sup>10,11</sup> Chemotherapy usually is suggested for distant metastases.<sup>12</sup>

Even though if LLMS is a very rare laryngeal malignancy, it should be considered when dealing with laryngeal abscess, especially with cartilage involvement.

## Authors' Note

The human participant involved in this research signed an informed consent before any further treatment. All procedures performed were in accordance with the ethical standards of the institutional and/or national research committee and with the 1964 Helsinki declaration and its later amendments or comparable ethical standards.

## Declaration of Conflicting Interests

The author(s) declared no potential conflicts of interest with respect to the research, authorship, and/or publication of this article.

## Funding

The author(s) received no financial support for the research, authorship, and/or publication of this article.

## References

1. Jackson C, Jackson CL. Sarcoma of the larynx. In: Jackson C. (ed). *Cancer of the larynx*. Philadelphia: W. B. Saunders; 1939:164-168.
2. Yadav J, Bakshi J, Chouhan M, Modi R. Head and Neck Leiomyosarcoma. *Indian J Otolaryngol Head Neck Surg*. 2013; 65(Suppl 1):S1-S5.
3. Helmlinger RC, Croker BP, Mancuso AA. Leiomyosarcoma of the Larynx Presenting as a Laryngopyocoele. *AJNR Am J Neuroradiol*. 1996;17(6):1112-1114.
4. Cassano L, Lombardo P, Marchese-Ragona R, Pastore A. Laryngopyocoele: three new clinical cases and review of the literature. *Eur Arch Otorhinolaryngol*. 2000;257(9):507-511.

5. Mitroi M, Căpitănescu A, Popescu FC, et al. Laryngocele associated with laryngeal carcinoma. *Rom J Morphol Embryol*. 2011; 52(1):183-185.
6. Eliashar R, Gross M, Goldfarb A, Sichel JY. Purulent chondritis of the laryngeal framework cartilages. *Ann Otol Rhinal Laryngol*. 2005;114(3):219-222.
7. Lee JK, Cho HH, Kim HD, Lim SC. Purulent chondritis of the thyroid cartilage. *Am J Otolaryngol*. 2007;28(1):64-66.
8. Leiva-Salinas C, Mukherjee S. Purulent chondritis of the cricoid. *Eur Ann Otorhinolaryngol Head Neck Dis*. 2016;133(2):137-139.
9. Khadivi E, Taziky MH, Jafarian AH, Nasser Sadr M. Laryngeal leiomyosarcoma, a case report and review of articles. *Iran J Otorhinolaryngol*. 2013;25(73):253-258.
10. Abbas A, Ikram M, Yagoob N. Leiomyosarcoma of the larynx: A case report. *Ear Nose Throat J*. 2005;84(7):435-436.
11. Kleinsasser O., Glanz H. Myogenic tumors of the larynx. *Arch Otorhinolaryngol*. 1979;225(2):107-119.
12. Ismi O, Arpacı RB, Puturgeli T, Özcan C, Gorur K. Leiomyosarcoma of Larynx as a Metachronous Tumor of Squamous Cell Carcinoma: An Unusual Case. *J Voice*. 2016;30(2):242-245.