

# Diabetic foot complicated by vertebral osteomyelitis and epidural abscess

Alessandro Mantovani<sup>1</sup>, Maddalena Trombetta<sup>1</sup>, Chiara Imbriaco<sup>1</sup>, Riccardo Rigolon<sup>1</sup>, Lucia Mingolla<sup>1</sup>, Federica Zamboni<sup>1</sup>, Francesca Dal Molin<sup>1</sup>, Dario Cioccoloni<sup>1</sup>, Viola Sanga<sup>1</sup>, Massimiliano Bruti<sup>2</sup>, Enrico Brocco<sup>3</sup>, Michela Conti<sup>4</sup>, Giorgio Ravenna<sup>5</sup>, Fabrizia Perrone<sup>1</sup>, Vincenzo Stoico<sup>1</sup> and Enzo Bonora<sup>1</sup>

<sup>1</sup>Division of Endocrinology, Diabetes and Metabolism, Department of Medicine, <sup>2</sup>Division of Plastic Surgery, Department of Surgery, University and Azienda Ospedaliera Universitaria Integrata of Verona, Verona, Italy, <sup>3</sup>Regional Referral Center for the Treatment of Diabetic Foot, Policlinico Abano Terme, Padova, Italy, <sup>4</sup>Division of Infectious Disease, Department of Medicine, and <sup>5</sup>Division of Neurosurgery, Department of Surgery, University and Azienda Ospedaliera Universitaria Integrata of Verona, Verona, Italy

Correspondence should be addressed to A Mantovani

**Email**  
[alessandro.mantovani24@gmail.com](mailto:alessandro.mantovani24@gmail.com)

## Summary

Vertebral osteomyelitis (or spondylodiscitis) is steadily increasing in Western countries and often results from hematogenous seeding, direct inoculation during spinal surgery, or contiguous spread from an infection in the adjacent soft tissue. We present the case of a 67-year-old white patient with type 2 diabetes who went to Hospital for high fever, back pain, and worsening of known infected ulcers in the left foot. Despite intravenous antibiotic treatment and surgical debridement of the foot infection, high fever and lower back pain continued. Bone biopsy and two consecutive blood cultures were positive for *Staphylococcus aureus*. A spinal magnetic resonance imaging (MRI) was performed, revealing serious osteomyelitis in L4 and L5 complicated by an epidural abscess. Contiguous or other distant focuses of infection were not identified. In this case, diabetic foot could be considered as a primary distant focus for vertebral osteomyelitis. Clinicians should consider vertebral osteomyelitis as a 'possible' diagnosis in patients with type 2 diabetes complicated by foot infection that is associated with fever and lower back pain.

## Learning points:

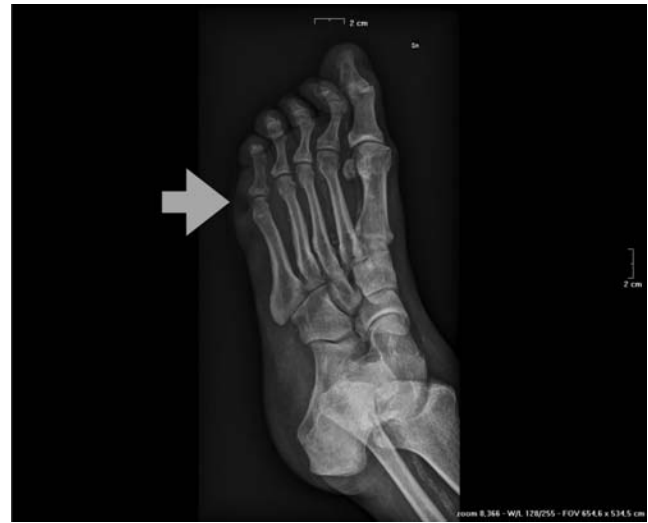- Vertebral osteomyelitis is increasing in Western countries, especially in patients with type 2 diabetes.
- The primary focus of infection is the genitourinary tract followed by skin, soft tissue, endocarditis, bursitis, septic arthritis, and intravascular access.
- Diabetic foot could be a rare primary focus of infection for vertebral osteomyelitis, and, however, vertebral osteomyelitis could be a serious, albeit rare, complication of diabetic foot.
- Clinicians should keep in mind the many potential complications of diabetic foot ulcerations and consider vertebral osteomyelitis as a "possible" diagnosis in patients with type 2 diabetes and foot ulcers associated with nonspecific symptoms such as lower back pain.
- Early diagnosis and correct management of vertebral osteomyelitis are crucial to improve clinical outcomes.

## Background

Vertebral osteomyelitis (or spinal osteomyelitis, spondylodiscitis, septic diskitis, disk-space infection) is an infection of the disk space and the adjacent vertebral bodies clinically characterized by back pain, fever, and, sometime neurological disorders (1). Over the last decade, there has been an increased incidence of vertebral osteomyelitis in Western countries. This rising is secondary to increase in elderly, immunocompromised populations and invasive spinal procedures (1, 2). The age distribution of this disease is bimodal: one peak at age less than 20 years and a second peak in the subjects aged 50–70 years (1). Males seem to be more affected than females (1). Vertebral osteomyelitis often results from hematogenous seeding, direct inoculation during spinal surgery, or contiguous spread from an infection in the adjacent soft tissue (1). The most common microorganism implicated in the pyogenic vertebral osteomyelitis is *Staphylococcus aureus* (1, 3). Usually, the primary focus of infection is the genitourinary tract, skin, soft tissue, endocarditis, bursitis, septic arthritis, or a site of vascular access (1). In some cases, vertebral osteomyelitis could be complicated by paravertebral, epidural, or psoas abscesses (1). To date, very little information (4, 5, 6) is available regarding the foot as a primary focus of infection for vertebral osteomyelitis in patients with type 2 diabetes. In this report, we presented the case of a white adult patient with type 2 diabetes and vertebral osteomyelitis as a complication of the diabetic foot.

## Case presentation

A 67-year-old white male patient with type 2 diabetes was admitted to our department for fever, lower back pain, and severe infected ulcers in the left foot as shown in Fig. 1. In addition to diabetes, his medical history included the following: hypertension, chronic kidney disease, peripheral arteriopathy, dyslipidemia, and a previous history of vertebral osteomyelitis. The diabetic foot ulcers appeared since 1 month, and had been treated, in the first instance, with a conservative approach by dressings with topical antiseptic and oral antibiotic therapy such as amoxicillin, according to *Staphylococcus aureus* methicillin-sensitive isolated by bone biopsy performed in an ambulatory setting. Nevertheless, the infection further progressed involving the deep layers of the foot, also causing systemic symptoms. On admission, the patient's body temperature was 38°C and his left foot was malodorous, hot, erythematous, and edematous up to the level of the



**Figure 1**  
Osteomyelitis of the head of fifth metatarsus in the left foot.

forefoot. Moreover, the patient reported lower back pain extending to the right thigh. The physical examination revealed back stiffness around the lower lumbar spine and superior anterior right thigh. The patient was unable to perform hip flexion on the right secondary to pain. On the basis of the clinical and laboratory findings, parenteral antibiotic therapy with piperacillin/tazobactam was instantly started and the surgical debridement of the foot infection was performed 2 days later. In the following days, the infection in the foot improved step by step, but the fever increased and the back pain worsened.

## Investigation

Blood tests carried out at the time of admission revealed the following: white blood cells (WBC)  $7.15 \times 10^9/L$  (normal range (NR): 4.3–10), hemoglobin 89 g/L (NR: 135–170), platelets  $119 \times 100\,000/mm^3$  (NR: 150–450), fasting glucose 8.6 mmol/L (NR: 3.5–5.5), HbA1c 36 mmol/mol, ALT 14 U/L (NR: 6–50), GGT 116 U/L (NR: 4–60), creatinine 130  $\mu\text{mol}/L$  (NR: 53–115), C-reactive protein (CRP) 159 mg/L (normal value: <5), and procalcitonin 0.13 ng/mL (normal value: <0.05). In the following days, coinciding with the worsening of fever, systemic symptoms, and back pain, CRP (334 mg/L) and WBC ( $17 \times 10^9/L$ ) significantly increased. Foot bone biopsy and two sets of blood cultures indicated *Staphylococcus aureus* infection. The antimicrobial sensitivities showed that the isolated microorganism was susceptible to all beta-lactam antibiotics, including piperacillin/tazobactam. To keep out other sites of infection, urinalysis and urine

culture, as well as chest X-ray, ultrasound abdomen, and transthoracic echocardiogram (TTE) had been performed. All investigations were negative. However, as TTE could not assess very little vegetations (i.e. <2 mm in diameter) and detects vegetations only in 65% of patients with endocarditis, a transesophageal echocardiogram (TEE) was also performed. The TEE was negative for vegetations on the valves and kept out decisively an endocarditis. Given the previous history of vertebral osteomyelitis and the worsening of back pain, a spinal magnetic resonance imaging (MRI) was performed. The radiological investigation revealed serious alterations of signal into the bodies of L4 and L5, which appeared heterogeneously hyperintense on T2 after the administration of gadolinium. Moreover, an enhancement of the muscles ileum psoas bilaterally and the enhancement in the intracanal epidural tract from L4 to S1 were also recognized (Fig. 2, Panel A). These findings suggested a serious osteomyelitis in L4 and L5 complicated by an epidural abscess.

## Treatment

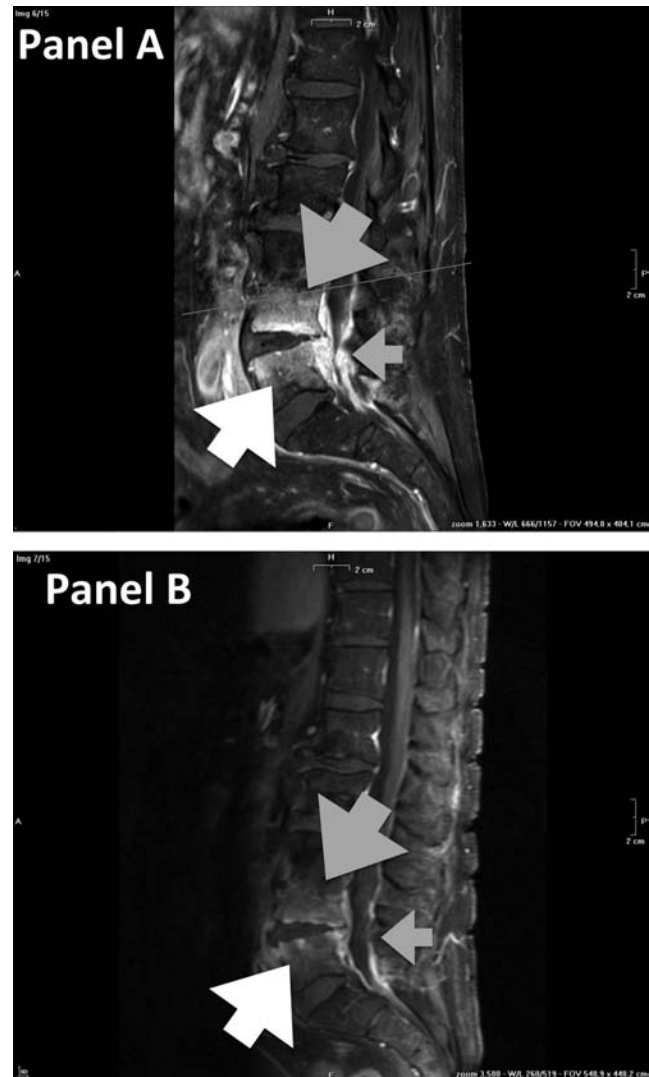
The clinical case was discussed with the neurosurgeon and the infectivologist: there were no indications for surgical intervention, and conservative treatment with high doses of piperacillin/tazobactam was continued at the Infectious Diseases Department. The intravenous antibiotic therapy lasted for 12 weeks.

## Outcome and follow-up

There are some evidences suggesting that MRI alterations may persist or even worsen during antibiotic therapy irrespective of clinical improvement as reported in our patient (Fig. 2, Panel B). The mean treatment duration of antimicrobial therapy ranges from 6 to 8 weeks, and in our case, given the detection of the epidural abscess, the duration of the antibiotic therapy was extended for an other 4 weeks (7, 8). To carry on the intravenous therapy with piperacillin/tazobactam, the patient was transferred to the Infectious Diseases Department. During hospitalization, and after surgical debridement, a cycle of VAC-therapy (Vacuum-Assisted Closure Therapy System) and, subsequently, an autologous skin graft were performed. Finally, the foot ulcer and the vertebral osteomyelitis were completely healed.

## Discussion

The incidence of vertebral osteomyelitis is steadily increasing in Western countries (1, 2) and the hematogenous



**Figure 2**

(Panel A) Vertebral osteomyelitis in L4 (gray arrow) and L5 (white arrow) complicated by epidural abscess (small gray arrow) evaluated with MRI. (Panel B) Persistence of radiological signs (gray arrow in L4 and white arrow in L5) of vertebral osteomyelitis and epidural abscess (small gray arrow) evaluated with MRI performed after 1 month of antibiotic therapy.

seeding is the most predominant route for spreading the infection (1). Contiguous spread is not common and, most frequently, the primary focus of infection is genitourinary tract, skin, soft tissue, infective endocarditis, septic arthritis, or intravascular access (1). Currently, although diabetes mellitus is an important risk factor, there is very little data about diabetic foot ulcerations as a primary site responsible for vertebral osteomyelitis.

Our patient was a 67-year-old male with type 2 diabetes complicated by foot ulcerations and reported a previous history of vertebral osteomyelitis. The lower back

pain and fever had developed after worsening of diabetic foot infection. Both bone and blood cultures were positive for *Staphylococcus aureus*, which is the most frequent pathogen isolated in vertebral osteomyelitis (1, 2, 3). Notably, other investigations to display the primary focus of infection were negative. Therefore, we speculated that the foot ulcerations could be identified as the distant site responsible for this case of vertebral osteomyelitis. The reasonable assumptions for our hypothesis were as follows:

1. foot infection was prior to the lower back pain and fever;
2. neither contiguous nor distant focus had been identified;
3. *Staphylococcus aureus* was the only microorganism isolated and it is well known as the most common organism isolated in vertebral osteomyelitis (1) (3);
4. this microorganism is able to colonize human tissues for long time and produces several factors facilitating attachment to extracellular matrix proteins (i.e. adhesins) and escaping from host defenses (i.e. protein A, toxins, capsular polysaccharides) (9);
5. diagnosis of vertebral osteomyelitis is often delayed due to the low incidence, the insidious onset, and the nonspecific symptoms (1).

For these reasons, as suggested by Zimerli, the 'possible' diagnosis for vertebral osteomyelitis could be speculated when there are clinical suspicions (i.e. fever and lower back pain) and two positive blood cultures (1). Furthermore, the MRI with gadolinium is considered the gold standard for radiological diagnosis, according to the ability to localize infection and identify pyogenic complications, such as epidural, paravertebral, or disk-space abscess (10). As shown in Fig. 2 (Panel A), an MRI performed on our patient highlighted serious alterations of signal into the bodies of L4 and L5, in the muscles ileum psoas bilaterally, and also in the epidural tract from L4 to S1. Collectively, these findings are highly suggestive of vertebral osteomyelitis in L4 and L5 complicated by an epidural abscess. For this reason, the antibiotic therapy was continued for several weeks.

In conclusion, our case report is clinically relevant because it highlighted the role of diabetic foot as a primary distant focus for vertebral osteomyelitis and helped the clinicians to consider vertebral osteomyelitis as a 'possible'

diagnosis in patients with type 2 diabetes complicated by foot infection that is associated with nonspecific symptoms such as lower back pain. Finally, the early diagnosis and management of vertebral osteomyelitis are crucial to improve clinical outcomes.

#### Declaration of interest

The authors declare that there is no conflict of interest that could be perceived as prejudicing the impartiality of the research reported.

#### Funding

This research did not receive any specific grant from any funding agency in the public, commercial or not-for-profit sector.

#### References

- 1 Zimerli W 2010 Vertebral osteomyelitis. *New England Journal of Medicine* **362** 1022–1029. (doi:10.1056/NEJMc0910753)
- 2 Grammatico L, Baron S, Rusch E, Lepage B, Surer N, Desenclos JC & Besnier JM 2008 Epidemiology of vertebral osteomyelitis in France: analysis of hospital discharge data 2002–2003. *Epidemiology and Infection* **136** 653–660. (doi:10.1017/S0950268807008850)
- 3 Lew DP & Waldvogel FA 2004 Osteomyelitis. *Lancet* **364** 369–379. (doi:10.1016/S0140-6736(04)16727-5)
- 4 Ceilley R 1977 Foot ulceration and vertebral osteomyelitis with *Corynebacterium haemolyticum*. *Archives of Dermatology* **113** 646–647. (doi:10.1001/archderm.1977.01640050106018)
- 5 Cechurova D, Lacigova S, Zourek M, Gruberova J, Haladova I, Tomesova J & Rusavy Z 2013 Spondylodiscitis and epidural empyema as a complication of diabetic foot. *Vnitřní Lékarství* **59** 412–415.
- 6 Nicolosi N & Pratt C 2014 Infectious spondylodiscitis, epidural Phlegmon, and psoas abscess complicating diabetic foot a case report. *Journal of Foot and Ankle Surgery* **55** 267–271. (doi:10.1053/j.jfas.2014.06.022)
- 7 Legrand E, Flipo RM, Guggenbuhl P, Masson C, Maillefert JF, Soubrier M, Noël E, Saraux A, Di Fazano CS, Sibilia J, et al. 2001 Management of nontuberculous infectious discitis. Treatments used in 110 patients admitted to 12 teaching hospitals in France. *Joint Bone Spine* **68** 504–509. (doi:10.1016/S1297-319X(01)00315-3)
- 8 Butler JS, Shelly MJ, Timlin M, Powderly WG & O'Byrne JM 2006 Nontuberculous pyogenic spinal infection in a 12-year experience from a tertiary referral center. *Spine* **31** 2695–2700. (doi:10.1097/01.brs.0000244662.78725.37)
- 9 Proctor RA, van Langevelde P, Kristjansson M, Maslow JN & Arbeit RD 1995 Persistent and relapsing infections associated with small-colony variants of *Staphylococcus aureus*. *Clinical Infectious Diseases* **20** 95–102. (doi:10.1093/clinids/20.1.95)
- 10 Palestro CJ, Love C & Miller TT 2006 Infection and musculoskeletal imaging of musculoskeletal infections. *Best Practice & Research: Clinical Rheumatology* **20** 1197–1218. (doi:10.1016/j.berh.2006.08.009)

Received in final form 14 March 2016

Accepted 21 April 2016