

Ultrasound prenatal diagnosis of a lateral facial cleft (Tessier number 7)

F. PRESTI*, C. CELENTANO‡, L. MARCAZZÒ†, G. DOLCETTA* and F. PREFUMO§

Departments of *Obstetrics and Gynaecology and †Paediatrics, Ospedale Civile, Arzignano, ‡Department of Obstetrics and Gynaecology, Ospedale 'S. Massimo', Penne and §Department of Obstetrics and Gynaecology, Istituto 'G. Gaslini', University of Genova, Genova, Italy

KEYWORDS: atypical cleft; lateral facial cleft; macrostomia; prenatal diagnosis; ultrasound

ABSTRACT

Lateral facial clefting may occur as an isolated phenomenon or in association with other disorders. It may originate from a failed penetration of ectomesenchyme between the developing maxillary and mandibular prominences, but disruptive factors may also occur in a proportion of cases. The frequency of this abnormality is estimated as 1 in 50 000–175 000 live births. We describe a case of isolated symmetrical lateral facial cleft (number 7 according to the Tessier classification) diagnosed prenatally on ultrasound examination at 26 weeks of gestation. Copyright © 2004 ISUOG. Published by John Wiley & Sons, Ltd.

INTRODUCTION

Lateral facial clefting (macrostomia) is a rare congenital malformation. It may occur either as an isolated phenomenon or in combination with other congenital anomalies. We present a case of lateral facial clefting diagnosed by antenatal ultrasound at 26 weeks of gestation.

CASE REPORT

A 33-year-old African patient, gravida 3 para 0, presented for antenatal care for the first time at 24 weeks of gestation. In her two previous pregnancies she had a late miscarriage at 20 weeks and a stillbirth at 26 weeks in another country. Uterine curettage was needed after each pregnancy loss. No specific investigation for these two previous pregnancy failures had been carried out.

The ultrasound examination at 26 weeks showed normal fetal growth and mild polyhydramnios. An

abnormality of the fetal face was identified, with the lips appearing prominent and the lateral commissures of the mouth widened (Figure 1a). No cleft lip was identified and the alveolar ridges appeared intact. A diagnosis of lateral facial clefting was made. An intrauterine synechia was also observed.

At 29 weeks of gestation tense polyhydramnios was present together with a small stomach bubble, and an amniodrainage procedure was performed. Examination of the amniotic fluid revealed a normal female karyotype. At 34 weeks of gestation the patient went into spontaneous labor. Due to fetal heart rate abnormalities in the first stage of labor, a female infant weighing 2280 g was delivered by Cesarean section. At examination, the baby had macrostomia, with a bilateral cleft running from one cheek to the other and passing through the lateral angles of the mouth (Figure 2). The oral commissures had lateral and symmetric displacement of 12 mm. Chest and abdominal X-ray, in addition to total body magnetic resonance imaging scan, were normal. No midline problems were noted. Pathological examination of the placenta did not disclose any abnormality. Surgical correction of the cleft was successfully performed at 6 months of age. At 1 year of age, the baby is showing normal growth and neurological development.

DISCUSSION

Isolated lateral facial clefts are rare congenital deformities with an estimated frequency of 1 in 50 000–175 000 live births^{1,2}. While typical cleft lip and palate are due to a failure of union of the frontonasal process of the face with the lateral maxillary prominences at about 3–4 weeks' gestation³, the etiopathogenesis of atypical craniofacial clefts is still unclear. It remains unknown whether cleft palate formation is due to intrinsic biomolecular defects in

Correspondence to: Dr F. Prefumo, U. O. Ostetricia e Ginecologia, Istituto 'G. Gaslini', Largo G. Gaslini 5, 16147 Genova, Italy (e-mail: fprefumo@sghms.ac.uk)

Accepted: 20 December 2003

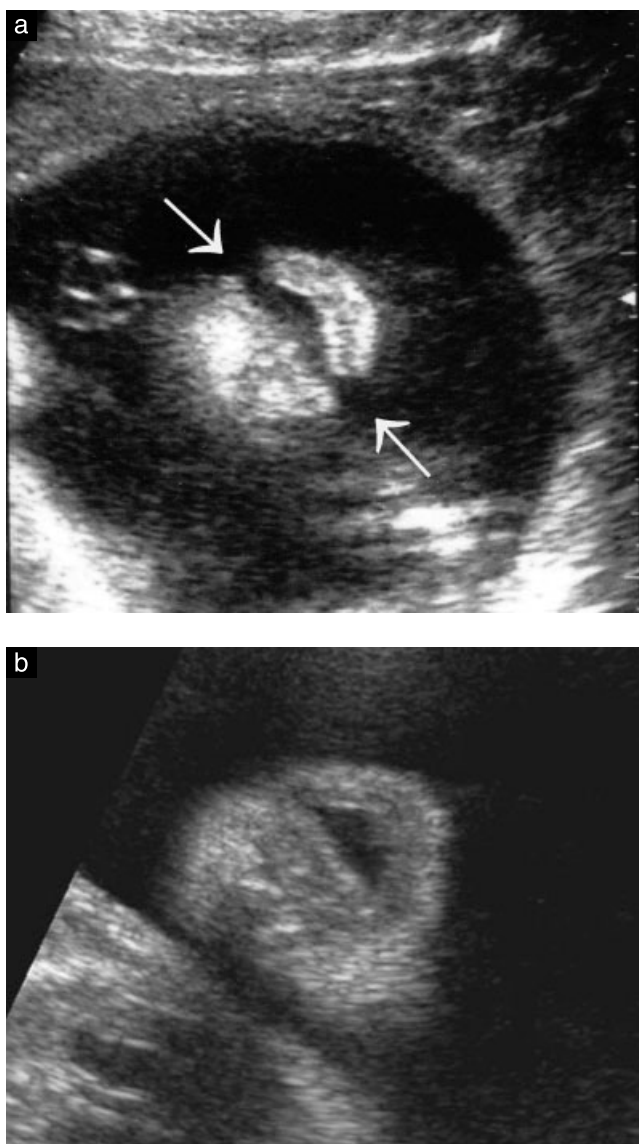


Figure 1 (a) Ultrasonographic coronal view of the fetal lips in the present case showing prominent lips and widened lateral commissures with bilateral facial cleft (arrows). (b) A similar ultrasound plane is shown in a case with normal facial anatomy.

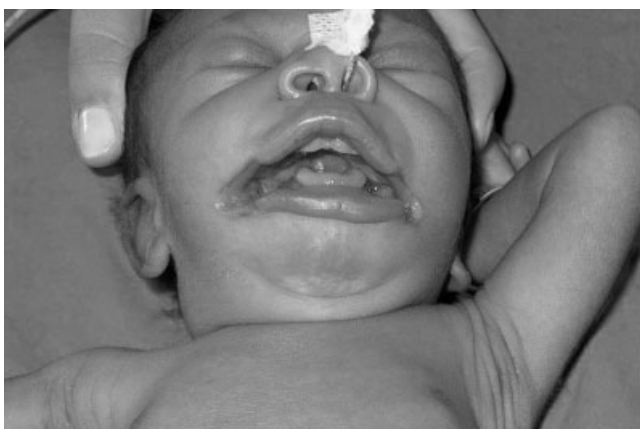

Figure 2 Appearance of the bilateral facial cleft in the newborn.

the embryonic elevating palatal shelves or to an inability of the shelves to overcome a mechanical obstruction to normal fusion⁴.

Atypical clefts represent only 3.1% of all facial clefts. They have an incidence of 1.8–2.5 : 10 000 deliveries and are more common in males. The unilateral form is six times more common than the bilateral one⁵. Bilateral lateral facial clefts are usually symmetrical and may extend from the angle of the mouth in a horizontal direction or slightly sweep upwards. They can have a variable extension, and the most severe forms can reach the ear. According to the Tessier classification system, they are classified as number 7⁵. Lateral facial clefts can either appear in isolation or be associated with other abnormalities such as hand anomalies, micrognathia, facial dysmorphisms and bifid uvula. Lateral clefts are also present in mandibulofacial dysostosis and in the oculo-auriculo-vertebral spectrum^{1,3}.

The most remarkable antenatal finding in the present case was the macrostomia detected on coronal views at 26 weeks' gestation. The images showed odd, bigger lips (Figure 1a) but we were unable to show a protrusion of the tongue through the lips. A coronal view of normal fetal lips is shown in Figure 1b for comparison, demonstrating how the lateral commissures of the mouth appear narrower and better defined in cases with normal anatomy. The ultrasound findings of the lateral cleft are subtle, and may appear very similar to those of an open mouth in a normal fetus. However, the findings will be persistent in the case of lateral cleft, as opposed to the transient widening observed in the latter case. We did not find lateral or transverse views particularly helpful in the diagnosis, given the lack of landmarks to determine the position of the lateral commissures.

The absence of further fetal abnormalities suggested the diagnosis of an isolated facial cleft. Polyhydramnios was also observed in combination with a small stomach bubble. Given the normal gastrointestinal tract anatomy and function demonstrated postnatally, this was most likely due to the partly impaired swallowing mechanism that is often seen in fetuses with facial clefts⁶. Amniotic tenting in association with an intrauterine synechia was seen, but no clear evidence of amniotic bands was present either at ultrasound or postnatal examination of the newborn and placenta.

A rupture of the amnion in early pregnancy can lead to an entrapment of fetal structures by sticky mesodermal bands that originate from the chorionic side of the amnion followed by disruption^{7,8}. Recent data demonstrate that lateral facial clefts may occur during the postorganogenesis period rather than during primary facial morphogenesis as the result of amniotic bands⁸. Some authors have demonstrated a relationship between the presence of restricting forces and the development of atypical clefts using an *in-utero* animal model⁸. In this model a 2-0 nylon suture attached to the zygomatic arch or externally to the fronto-orbital rim in fetal lambs (less than 140 days) created artificial constricting forces leading to a lateral cleft and macrostomia in all animals treated.

The same authors showed that the intrauterine lysis of these forces (sutures) was able to prevent the abnormal growth of the facial commissure⁹. More recently, it was demonstrated that *in-utero* cleft repair is technically possible in a goat model^{10,11}.

As reported in the literature^{12–15}, amniotic bands can create incomplete forms of development of facial structures in humans. However, in the present case no clear evidence of amniotic bands was found. The observation of amniotic tenting was explained by the presence of an uterine synechia, confirmed at Cesarean section. The two dilatation and curettage procedures performed in the patient after mid-gestation miscarriage can explain the presence of the adhesion.

Independent of the etiology, this is the first report of an isolated symmetrical Tessier number 7 lateral facial cleft diagnosed prenatally at ultrasound examination. This case emphasizes the importance of obtaining coronal views of the fetal face on routine scans. However, the defect described presented with very subtle findings and no conclusion can be drawn regarding the sensitivity of antenatal ultrasound for its detection. Three-dimensional ultrasound is potentially of great value in the diagnosis of this condition.

REFERENCES

1. De Die Smulders CEM, Moog U, Engelen JJM, Peters JJM, Damen A, Vos W, Fryns JP. Lateral facial clefts: a case report. *Genet Couns* 2001; **12**: 163–165.
2. Kara IG, Ocsel H. The Tessier number 5 cleft with associated extremity anomalies. *Cleft Palate Craniofac J* 2001; **38**: 529–532.
3. Gorlin RJ, Cohen MM, Stefan Levin L. Orofacial clefting syndromes. In *Syndromes of the Head and Neck*, 3rd edn. Oxford Monographs on Medical Genetics no. 19. Oxford University Press: New York, NY, 1990.
4. Erfani S, Maldonato TS, Crisera CA, Warren SM, Lee S, Longaker MT. An *in vitro* mouse model of cleft palate: defining a critical distance necessary for palate clefting. *Plast Reconstr Surg* 2001; **108**: 403–410.
5. Tessier P. Anatomical classification of facial cranio-facial and lateral-facial clefts. *J Maxillofac Surg* 1976; **4**: 69–92.
6. Dashe JS, McIntire DD, Ramus RM, Santos-Ramos R, Twickler DM. Hydramnios: anomaly prevalence and sonographic detection. *Obstet Gynecol* 2002; **100**: 134–139.
7. Tadmor OP, Kreisberg GA, Achiron R, Porat S, Yagel S. Limb amputation in amniotic band syndrome: serial ultrasonographic and Doppler observations. *Ultrasound Obstet Gynecol* 1997; **10**: 312–315.
8. Stelnicki EJ, Hoffman WY, Vanderwall K, Harrison MR, Foster R, Longaker MT. A new *in utero* model for lateral facial clefts. *J Craniofac Surg* 1997; **8**: 460–465.
9. Stelnicki EJ, Hoffman WY, Foster R, Lopoo J, Longaker M. The *in utero* repair of Tessier number 7 lateral facial clefts created by amniotic band-like compression. *J Craniofac Surg* 1998; **9**: 557–562.
10. Weinzwieg J, Panter KE, Spangenberg A, Harper JS, McRae R, Edstrom LE. The fetal cleft palate: ultrastructural and functional analysis of palatal development following *in utero* repair of the congenital model. *Plast Reconstr Surg* 2002; **109**: 2355–2362.
11. Weinzwieg J, Panter KE, Pataloni M, Spangenberg A, Harper JSF, Gardner D, Wierenga TL, Edstrom LE. The fetal cleft palate. I: Characterization of a congenital model. *Plast Reconstr Surg* 1999; **103**: 419–428.
12. Moore MH. Rare craniofacial clefts. *J Craniofac Surg* 1996; **7**: 408–411.
13. Bronshtein M, Zimmer EZ. Do amniotic bands amputate fetal organs? *Ultrasound Obstet Gynecol* 1997; **10**: 309–311.
14. Jabor MA, Cronin ED. Bilateral cleft lip and palate and limb deformities: a presentation of amniotic band sequence? *J Craniofac Surg* 2000; **11**: 388–393.
15. Eppley BL, David L, Li M, Moore CA, Sadove AM. Amniotic band facies. *J Craniofac Surg* 1998; **9**: 360–365.