

# Botryoid rhabdomyosarcoma of the biliary tract in children: a unique case report

N. ZAMPIERI, MD, PHD, *Department of Surgical Sciences, Pediatric Surgical Unit, University of Verona, Verona*, F. CAMOGLIO, PHD, PROFESSOR, *Department of Surgical Sciences, Pediatric Surgical Unit, University of Verona, Verona*, M. CORROPOLO, PHD, DOCTOR, *Department of Surgical Sciences, Pediatric Surgical Unit, University of Verona, Verona*, M. CECCHETTO, PHD, DOCTOR, *Department of Surgical Sciences, Pediatric Surgical Unit, University of Verona, Verona*, S. ORNIS, PHD, DOCTOR, *Department of Woman and Children, King's College Hospital NHS Trust, Denmark Hill, London, UK*, & A. OTTOLENGHI, PHD, PROFESSOR, *Department of Surgical Sciences, Pediatric Surgical Unit, University of Verona, Verona, Italy*

ZAMPIERI N., CAMOGLIO F., CORROPOLO M., CECCHETTO M., ORNIS S. & OTTOLENGHI A. (2006) *European Journal of Cancer Care* **15**, 463–466

## Botryoid rhabdomyosarcoma of the biliary tract in children: a unique case report

Rhabdomyosarcoma (RMS) is the most common tumour of the biliary tree in childhood. In children, it is a rare lesion, accounting for about 1% of all RMS. Hepatobiliary botryoid RMS is a disease affecting young children at a median age of about 3 years. In literature, the radiological findings of hepatobiliary RMS have been described in small series and some case reports. In this case report, we present a rare case of RMS of the extrahepatic biliary tree initially diagnosed as a choledochal cyst.

*Keywords:* rhabdomyosarcoma, biliary tree, botryoid.

## INTRODUCTION

Rhabdomyosarcoma (RMS), a soft tissue malignant musculoskeletal tumour, accounts for approximately 1% of the cases of cancer among children aged 0–14 years and 2% of the cases among adolescents and young adults aged between 15 and 18 years (Iwai *et al.* 1990).

In most children, it develops as a localized disease curable with combined modality therapy, with a survival rate of >75% after 5 years from diagnosis.

Rhabdomyosarcoma is the most common tumour of the biliary tree in childhood, accounting for 1% of all paediatric RMS (Martinez *et al.* 1982).

Rhabdomyosarcoma occurs infrequently in the liver and biliary tree with only 45 cases reported since 1975. The management and prognosis of this tumour is constantly changing as new imaging techniques and chemotherapy as initial treatment become available (Maurer *et al.* 1988; Crist *et al.* 2001).

## CASE REPORT

In March 2002, O.A.M., a 3-year-old Nigerian girl, was hospitalized for jaundice, anemia and hepatomegaly, with WBC 17 000, AST 170, ALT 139 and total Bilirubin 16.54 mg/mL.

Objective examination showed a distended abdomen, with no pain during both superficial and deep palpation. There was no report of either hereditary diseases or previous episodes of abdominal pain.

An abdominal US scan showed an expansive formation with a diameter of about 6 cm and a mixed (solid and liquid) echostructure at the site of the hepatic hilum.

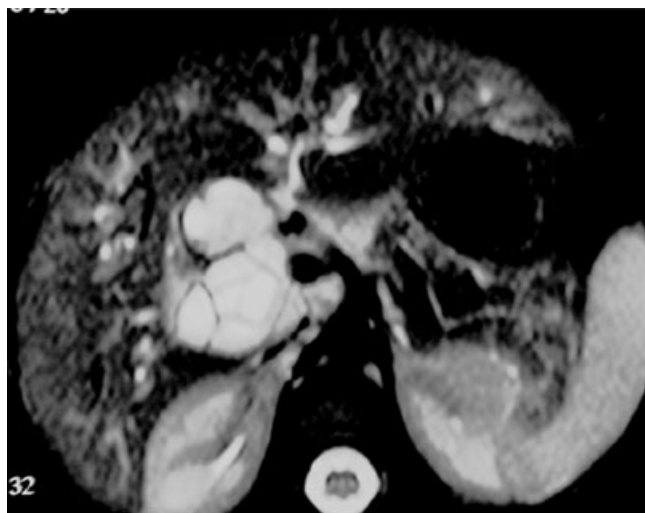---

Correspondence address: Nicola Zampieri, Pediatric Surgical Unit, Policlinico 'G. B. Rossi', Piazzale L.A. Scuro, 37134 Verona, Italy (e-mail: zampius@libero.it).

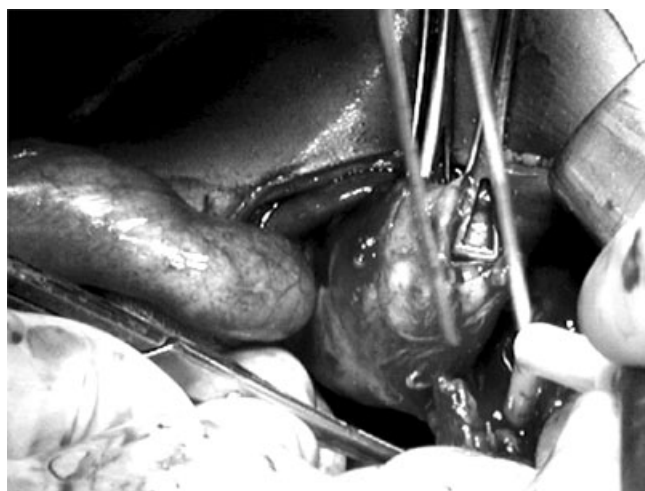
Accepted 24 February 2006

DOI: 10.1111/j.1365-2354.2006.00683.x

*European Journal of Cancer Care*, 2006, **15**, 463–466



**Figure 1.** Abdominal MRI at the level of the hepatic hilum. MRI, magnetic resonance imaging.



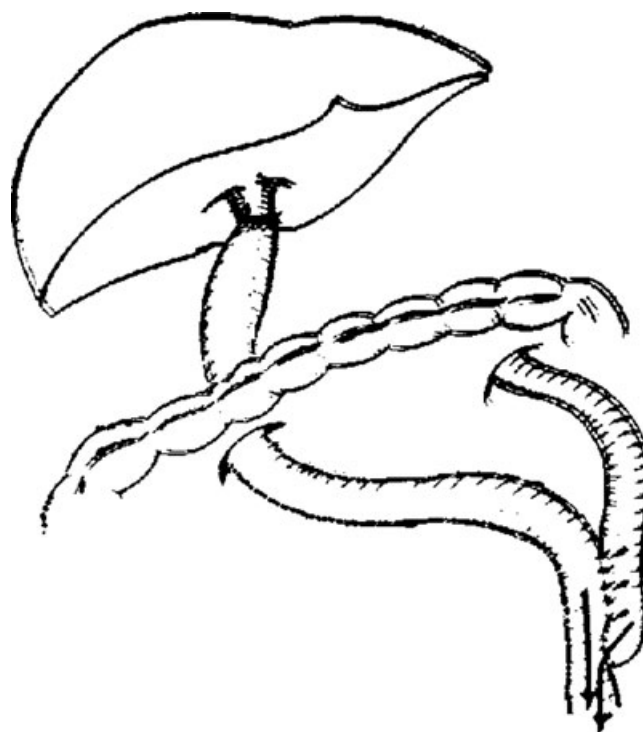
**Figure 2.** Choledochal mass.

It also showed significant cystic duct ectasia, with small gallstones in the duct lumen.

Nuclear magnetic resonance showed a dilation of the common hepatic duct as well as a significant dilation of the choledochus duct up to its extra-pancreatic tract (Fig. 1).

The patient was then transferred to our Department with a diagnosis of choledochal cyst to undergo corrective surgery.

During super-umbilical transverse laparotomy, we found a major choledochal cystic formation which was difficult to isolate and remove (Fig. 2). The gallbladder appeared distended with tense neof ormation surrounded by inflammatory tissue. Complete avulsion of the extra-hepatic duct and a Roux-en-Y hepatico-jejunostomy, without antireflux jejunum valve, was therefore performed (Fig. 3).



**Figure 3.** Excision of the mass and hepaticojejunostomy and Roux-en-Y anastomosis.

**Table 1.** Intergroup Rhabdomyosarcoma Clinical Groups

Group	Residual tumor after resection
I	None (gross or microscopic)
IIa	Microscopic residual tumour at primary site; pathologic negative nodes
IIb	No residual tumour at primary site; pathologic positive nodes
IIc	Microscopic residual tumour at primary site and pathologic positive nodes
III	Gross residual tumour
IV	Distant metastasis

Histology revealed a botryoid RMS of the extra-hepatic bile duct (with a diameter of 5 cm) affecting both the choledochus and the common hepatic duct. There was also evidence of translucent polypoid formations both in the choledochus and in the common hepatic duct. The neoplasia developed near the margin of the proximal resection (hepatic duct), with a report of chronic cholecystitis.

Pericyclic lymph nodes did not show significant structural changes.

Ten days after surgery, the patient was then transferred to the Paediatric Oncohaematology Unit and therefore discharged after 20 days.

The patient was included in to the IIa group of the Intergroup Rhabdomyosarcoma Clinical Groups Classification (Table 1). She received three chemotherapy cycles with

Vincristine, Actinomycin D, Ifosfamide and Adriamycin (V.A.I.A), in accordance with Intergroup Rhabdomyosarcoma Study Group IV. A CT scan carried out 8 and 18 months after surgery confirmed that distant metastasis did not develop. At present, the patient is being followed by our staff and is disease free.

## DISCUSSION

Botryoid RMS of the biliary tree is a very rare tumour and the first case was described by Wilks and Moxon in 1875 (Wilks & Moxon 1875; Aggarwal *et al.* 2004).

It accounts for 1% of all RMSs, occurring predominantly in infants with a clear preponderance of male patients. About 2% of tumours are present at birth. Intermittent jaundice with or without abdominal distension, fever and anorexia is the typical presentation.

In the past few years, the approach to sarcoma botryoides of the biliary tree has apparently changed. Recently, all patients classified as stage I, including those treated at our Department, have undergone aggressive surgical resection and subsequent adjuvant therapy. After diagnosis, their mean survival rate is 5 years (80%) (Neville *et al.* 2000).

The Intergroup Rhabdomyosarcoma Study Group (IRSG), the National Wilms' Tumor Study Group and other two large cooperative paediatric cancer treatment groups have recently merged to form the Children's Oncology Group (COG). Within COG, the Soft Tissue Sarcoma Committee (STS-COG) has developed new protocols for children with soft tissue sarcoma. In addition to IRSG, current STS-COG protocols also use a Tumour-Node-Metastasis (TNM)-based pre-treatment staging sys-

tem. The disease stage is clinically determined by primary tumour site and size, regional lymph node status, with or without metastases (Table 2) (Lawrence *et al.* 1987, 1997).

The STS-COG includes patients into different treatment protocols using a risk classification scheme combining the information about clinical group and disease stage described in this report. For protocol purposes, patients are classified as low, intermediate, or high risk (Table 3) (Breneman *et al.* 2001; Raney *et al.* 2001).

The extent of surgical resection currently recommended depends on primary tumour site, and initial complete resection is generally recommended if it does not involve loss of organ function. Undetectable distant metastases at diagnosis, grossly complete surgical removal of localized tumour, botryoid histology, tumour size < 5 cm and patient's age < 10 years at the time of diagnosis are favourable prognostic factors. We also want to stress the importance of assessing regional lymph nodes since histological evaluations showed that more than 75% of patients with clinically negative regional nodes also developed microscopic tumour. This finding is important for staging and grouping purposes, affecting also chemotherapy regimen, follow-up and prognosis (Lack *et al.* 1981; Geoffroy *et al.* 1987; Derek *et al.* 1998; Spunt *et al.* 2000).

Some authors recommend surgical exploration at the time of diagnosis only to confirm the diagnosis and to determine the extent of the regional disease. To this purpose, they suggest to perform a suitable incisional biopsy of the tumour and to explore the abdomen thoroughly to search for evidence of metastatic disease.

These authors also recommend minimally invasive biliary tract drainage procedures at diagnosis, like the place-

**Table 2.** Stage classification

- *Stage 1:* Localized disease involving the orbit or head and neck (excluding parameningeal sites), or genitourinary region (excluding bladder/prostate sites), or biliary tract (favourable sites).
- *Stage 2:* Localized disease of any other primary site not included in the stage 1 category (unfavourable sites). Primary tumours must be ≤ 5 cm in diameter, and there must be no clinical regional lymph node involvement by tumour.
- *Stage 3:* Localized disease of any other primary site. These patients differ from stage 2 patients by having primary tumours greater than 5 cm and/or regional node involvement.
- *Stage 4:* Metastatic disease at diagnosis.

The disease stage is clinically determined by primary tumour site and size, regional lymph node status, with or without metastases.

**Table 3.** Risk classification scheme

- *Low risk:* patients with localized embryonal rhabdomyosarcoma occurring at favourable sites (i.e. stage 1) (Groups I, II and III) and patients with embryonal rhabdomyosarcoma occurring at unfavourable sites with either completely resected disease (i.e. Group I) or microscopic residual disease (i.e. Group II).
- *Intermediate risk:* patients with embryonal rhabdomyosarcoma occurring at unfavourable sites with gross residual disease (i.e. Group III), patients with metastatic embryonal rhabdomyosarcoma who are younger than 10 years, and patients with non-metastatic alveolar rhabdomyosarcoma or undifferentiated sarcoma at any site.
- *High risk:* patients with metastatic rhabdomyosarcoma or undifferentiated sarcoma at presentation excepting embryonal cases in children younger than 10 years.

ment of an endoscopic stent. If stent placement is not possible, chemotherapy should be immediately started to try and decompress the biliary tract (Sanz *et al.* 1997; Pollono *et al.* 1998; Spunt *et al.* 2000).

We do agree with these authors, but we also believe that when treating children with the most favourable prognosis, like those under treatment at our Department, it is important to ensure high survival rates (>90%) and minimize long-term consequences of chemotherapy (Maurer *et al.* 1988, 1993; Crist *et al.* 1995).

## CONCLUSION

In the last 20 years, the rate of disease-free survival for patients affected by RMS of the hepatic bile tree has significantly increased.

Oncologic surgery certainly plays a key role in the survival of these patients and disease staging. The introduction of chemotherapy and radiotherapy has certainly improved the treatment timing of RMS. At Stage I, aggressive surgical therapies together with chemotherapy have increased the survival rate of patients after 5 years up to 80%.

## REFERENCES

- Aggarwal K., Pahuja S. & Chadha R. (2004) Botryoid Rhabdomyosarcoma of common bile duct. *Indian Journal of Pediatrics* **71**, 363–364.
- Breneman J., Anderson J., Donaldson S., Wharam M., Baker S., Maurer H., Pappo A., Link M., Meyer W. & Crist W. (2001) Prognostic factors and outcome in children with metastatic rhabdomyosarcoma – a report from the Intergroup Rhabdomyosarcoma Study IV. *International Journal of Radiation Oncology, Biology, Physics* **51** (Suppl. 1), A–210, 118.
- Crist W., Gehan E.A., Ragab A.H., Dickman P.S., Donaldson S.S., Fryer C., Hammond D., Hays D.M., Hermann J. & Heyn R. (1995) The third intergroup rhabdomyosarcoma study. *Journal of Clinical Oncology* **13**, 610–630.
- Crist W.M., Anderson J.R., Meza J.L., Fryer C., Raney R.B., Ruyman F.B., Brenemann J., Qualman S.J., Wiener E., Wharam M., Lobe T., Webber B., Maurer H.M. & Donaldson S. (2001) Intergroup rhabdomyosarcoma study-IV: results for patients with nonmetastatic disease. *Journal of Clinical Oncology* **19**, 3091–3102.
- Derek J.R., Wei T.Y., Wynnie W.M. & Stanley P. (1998) Hepatobiliary rhabdomyosarcoma in children: diagnostic radiology. *Pediatric Radiology* **28**, 101–108.
- Geoffroy A., Couanet D., Montagne J.P., Leclere J. & Flamant F. (1987) Ultrasonography and computed tomography for diagnosis and follow-up of biliary duct rhabdomyosarcomas in children. *Pediatric Radiology* **17**, 127–131.
- Iwai N., Deguchi E., Yanagihara J., Iwai M., Matsuo H., Todo S. & Imashuku S. (1990) Cancer arising in a choledochal cyst in a 12-year-old girl. *Journal of Pediatric Surgery* **12**, 1261–1263.
- Lack E.E., Perez-Atayde A.R. & Schuster S.R. (1981) Botryoid rhabdomyosarcoma of the biliary tract. *American Journal of Surgical Pathology* **5**, 643–652.
- Lawrence W. Jr, Gehan E.A., Hays D.M., Beltangady H. & Maurer H.M. (1987) Prognostic significance of staging factors of the UICC staging system in childhood rhabdomyosarcoma: a report from the Intergroup Rhabdomyosarcoma Study (IRS-II). *Journal of Clinical Oncology* **5**, 46–54.
- Lawrence W. Jr, Anderson J.R., Gehan E.A. & Maurer H. (1997) Pretreatment TNM staging of childhood rhabdomyosarcoma: a report of the Intergroup Rhabdomyosarcoma Study Group. Children's Cancer Study Group. Pediatric Oncology Group. *Cancer* **80**, 1165–1170.
- Martinez F.L.A., Haase G.M., Koep L.J. & Akers D.R. (1982) Rhabdomyosarcoma of the biliary tree: the case for aggressive surgery. *Journal of Pediatric Surgery* **5**, 508–511.
- Maurer H.M., Beltangady M. & Gehan E.A. (1988) The Intergroup Rhabdomyosarcoma Study I: a final report. *Cancer* **61**, 209–220.
- Maurer H.M., Gehan E.A., Beltangady M., Crist W., Dickman P.S., Donaldson S.S., Fryer C., Hammond D., Hays D.M. & Hermann J. (1993) The Intergroup Rhabdomyosarcoma Study-II. *Cancer* **71**, 1904–1922.
- Neville H.L., Andrassy R.J., Lobe T.E., Bagwell C.E., Anderson J.R., Womer R.B., Crist W.M. & Wiener E.S. (2000) Preoperative staging, prognostic factors, and outcome for extremity rhabdomyosarcoma: a preliminary report from the intergroup Rhabdomyosarcoma Study IV (1991–1997). *Journal of Pediatric Surgery* **35**, 317–321.
- Pollono D.G., Tomarchio S., Berghoff R., Drut R., Urratia A. & Cedola J. (1998) Rhabdomyosarcoma of the extrahepatic biliary tree: initial treatment with chemotherapy and conservative surgery. *Medical and Pediatric Oncology* **30**, 290–293.
- Raney R.B., Anderson J.R., Barr F.G., Donaldson S.S., Pappo A.S., Qualman S.J., Wiener E.S., Maurer H.M. & Crist W.M. (2001) Rhabdomyosarcoma and undifferentiated sarcoma in the first two decades of life: a selective review of intergroup rhabdomyosarcoma study group experience and rationale for Intergroup Rhabdomyosarcoma Study V. *Journal of Pediatric Hematology/Oncology* **23**, 215–220.
- Sanz N., de Mingo L., Florez F. & Rollan V.V. (1997) Rhabdomyosarcoma of the biliary tree. *Pediatric Surgery International* **12**, 200–201.
- Spunt S.L., Lobe E.T., Pappo A.S., Parham D.M., Wharam M.D. Jr, Arndt C., Anderson J.R., Crist W.M., Paidas C., Wiener E., Andrassy R.J. & Schwartz C.L. (2000) Aggressive surgery is unwarranted for biliary tract rhabdomyosarcoma. *Journal of Pediatric Surgery* **35**, 309–316.
- Wilks S. & Moxon W. (1875) *Lectures on Pathological Anatomy*, 2nd edn. Brown Green, Longmans Robertr, London, UK.