

Wandering spleen with a ten-time twisted vascular pedicle

Marta Peretti, Arianna Mariotto, Gabriella Scirè, Elisa Pani, Silvia Zambaldo, Sanzio Bianchi, Francesco Saverio Camoglio, Luca Giacomello

Paediatric Surgery Unit, Surgery, Dentistry, Paediatrics and Gynaecology Department, University of Verona, Verona, Italy

Abstract

Torsion of a wandering spleen is a rare cause of acute abdomen in children, usually diagnosed with color-Doppler ultrasonography and enhanced computed tomography. We report a pediatric case of torsion of wandering spleen.

Introduction

Torsion of a wandering spleen (WS) is a rare cause of acute abdomen in the pediatric patient.¹ Laxity or absence of the supporting ligaments predispose to spleen's migration in the abdominal cavity and torsion of its vascular pedicle.² Patients with WS can be asymptomatic or experience mild abdominal discomfort; in some cases splenic infarction occurs, representing thus a surgical emergency.³ Hence, an accurate diagnosis is not deferrable. We describe the case of a patient with a 10-time twisted vascular pedicle of the spleen, located in an anomalous position.

Case Report

A 8-year-old child presents at our Department with a 4-day history of crampy abdominal pain in the lower quadrants, worsened in the last hours and associated with vomit and fever. Parents refer chronic constipation and no history of abdominal trauma. Urological symptoms are

absent. On physical examination, palpation of the right iliac fossa is painful; Blumberg, Rovsing and Giordano signs are negative and peristalsis is normal. No abdominal mass is palpable. Blood tests show a white blood cell count of $29.9 \times 10^9/L$ and a C-reactive protein of 179 mg/L; hemoglobin level is 13.8 g/dL and platelet count is $249 \times 10^9/L$. Acute appendicitis is the initial suspicion. Abdominal radiographs find modest bowel distension. An urgent ultrasonography (US) of the abdomen, performed at the Emergency Department, detects a 13x6x8 cm solid tubular mass, located medially in the pelvis. A second US examination is performed to obtain further information about this radiological finding. Limited by meteorism, US reports a normal size spleen in the left hypocondrium and a parenchymatous pelvic mass, poorly vascularized at the colour-Doppler control. A computed tomography (CT) scan reveals an empty splenic fossa and a median unenhanced spleen with a twisted vascular pedicle (Figure 1). Therefore, splenic infarction is suspected. An urgent laparoscopy shows an enlarged ischemic spleen in meso-hypogastrium. Its 15 cm-long vascular pedicle is 10-time twisted and no spleen's supporting ligaments are documented. Because of the increased size of the spleen an open approach is preferred (Figure 2). After detorsion of the twisted pedicle, a splenectomy is performed since the spleen appears necrotic. Histological examination documents thrombosis of splenic vessels. The patient's post-operative course is uneventful and she is discharged 5 days later with a long-term antibiotic prophylaxis.

Discussion

Torsion of a WS is an uncommon clinical condition, characterized by twisted vascular pedicle of a hypermobile spleen, an anomaly due to the absence or laxity of spleen's supporting ligaments.^{1,2} WS accounts for less than 0.2% of splenectomies and its incidence shows a bimodal distribution: children below 10 years old and women of childbearing age.⁴ In children, WS represents more likely a congenital defect, resulted from an abnormal development of the dorsal mesogastrum.⁵ The clinical presentation of WS is variable. It can be an incidental finding in asymptomatic patients or it can cause intermittent pain or mild abdominal discomfort, due to its torsion and spontaneous detorsion. In some cases, persistent torsion leads to splenic infarction, which requires emergency surgical intervention. In our case, the child presented a 4-day history of abdominal pain in the lower quadrants, vomit and fever. On physical examination, an abdominal mass may be palpable in any abdominal quadrant, but this feature is absent in 33% of patients,⁶ as in our case. Imaging represents a useful adjunct in diagnosing such an uncommon condition. Pre-operative evaluation includes plain abdominal radiographs, US with colour-Doppler control and enhanced CT scan. US can reveal absence of the spleen in its normal location and detect a parenchymatous mass, usually located in the pelvis. Moreover, colour-Doppler control evaluates the vascularization of WS.³ However, the exam depends on the operator's skills and it is often limited by meteorism.¹ In our case, the second US misdiagnosed the condition. The

Correspondence: Luca Giacomello, Paediatric Surgery Unit, Surgery Department, University of Verona, G.B. Rossi Hospital, p.le L.A. Scuro 10, 37134 Verona, Italy.
Fax: +39.045.8124725.
E-mail: luca.giacomello@univr.it

Key words: Wandering spleen; Twisted vascular pedicle; Pediatrics.

Received for publication: 17 July 2015.
Revision received: 18 January 2016.
Accepted for publication: 19 July 2016.

This work is licensed under a Creative Commons Attribution NonCommercial 4.0 License (CC BY-NC 4.0).

©Copyright M. Peretti et al., 2016
Licensee PAGEPress, Italy
La Pediatria Medica e Chirurgica 2016; 38:119
doi:10.4081/pmc.2016.119

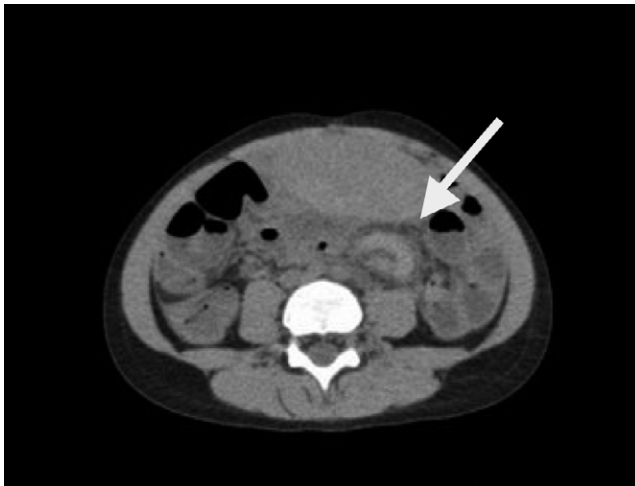

Figure 1. Computed tomography scan showing the spleen in the pelvis. The *whirl sign* (arrow) indicates torsion of the vascular pedicle.

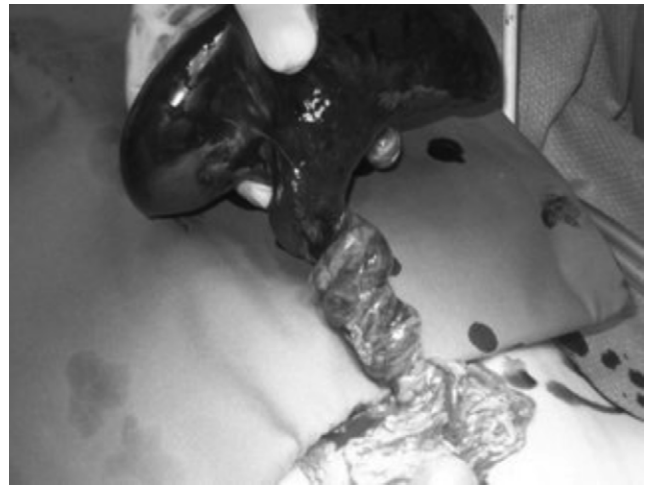


Figure 2. At laparotomy, spleen with a ten-time twisted vascular pedicle is visible.

most common CT findings are evidence of an empty splenic fossa and an ectopic spleen, located in the left mid-abdomen, and the *whirl sign*, a tomographic sign of pedicle torsion.⁶ Contrast-enhanced CT provides crucial information concerning the viability of the spleen. The above-mentioned findings were all documented in the CT scan performed in our case, which suspected the presence of a twisted spleen in the pelvis. Therapeutic options of torsion of WS are splenopexy and splenectomy, by open or laparoscopic approach. In our case, an urgent laparoscopy showed a 10-time twisted spleen, but at that time our laparoscopic skills were improper to complete the procedure.

Conclusions

Torsion of WS is an uncommon condition, but it should be considered in differential diagnosis of acute abdomen in the pediatric patient. For this reason, accurate pre-operative management is mandatory.

References

1. Sheflin JR, Lee CM, Kretchmar KA. Torsion of wandering spleen and distal pancreas. *Am J Roentgenol* 1984;142:100-1.
2. Hussain M, Deshpande R, Bailey ST. Splenic torsion: a case report. *Ann R Coll Surg Engl* 2010;92:51-2.
3. Khalid E, Fatimazahra B, Rachid L, et al. Acute abdomen in a torsion of an ectopic spleen: report of a case. *Pan Afr Med J* 2012;11:62.
4. Priyadarshi RN, Anand U, Kumar B, Prakash V. Torsion in wandering spleen: CT demonstration of whirl sign. *Abdom Imaging* 2013;38:835-8.
5. McHeik JN, Richer JP, Levard G. Torsion of the spleen in children. *Arch Pediatr* 2005;12:1496-9.
6. Fonseca AZ, Ribeiro M Jr, Contrucci O. Torsion of a wandering spleen treated with partial splenectomy and splenopexy. *J Emerg Med* 2013;44:e33-6.