

An alternative method for neonatal cerebro-myocardial perfusion

Giovanni Battista Luciani*, Fabrizio De Rita, Giuseppe Faggian and Alessandro Mazzucco

Division of Cardiac Surgery, University of Verona, Verona, Italy

* Corresponding author. Division of Cardiac Surgery, University of Verona, OCM. Piazzale Stefani 1, 37126 Verona, Italy. Tel: +39-045-8122485; fax: +39-045-8123308; e-mail: giovanni.luciani@univr.it (GB Luciani).

Received 29 August 2011; received in revised form 6 November 2011; accepted 14 November 2011

Abstract

Several techniques have already been described for selective cerebral perfusion during repair of aortic arch pathology in children. One method combining cerebral with myocardial perfusion has also been proposed. A novel technique is reported here for selective and independent cerebro-myocardial perfusion for neonatal and infant arch surgery. Technical aspects and potential advantages are discussed.

Keywords: Cerebral protection • Hypoplastic left heart syndrome • Interrupted aortic arch • Myocardial protection • Neonate • Perfusion (cerebral, myocardial)

Aortic arch repair in the neonate is traditionally accomplished during a period of deep hypothermic circulatory arrest. In order to reduce the potential damage of brain ischaemia, selective, regional low-flow perfusion (RLFP) techniques have been introduced, suggesting favourable neurological outcome [1, 2]. More recently, combined perfusion strategies of cerebral and myocardial circulation, using a Y connector on the arterial line, have been proposed in an attempt to reduce cardiac morbidity and mortality of complex arch surgery [3–5]. An alternative and novel strategy for cerebro-myocardial protection in the neonate is presented here, where RLFP is combined with controlled and independent coronary perfusion.

TECHNIQUE

Via midline sternotomy, the ascending aorta, aortic arch, descending aorta, neck vessels and ductus are dissected and mobilized to allow cannulation and tension-free anastomosis: in ductal-dependent systemic circulation, the branch pulmonary arteries are also isolated (Fig. 1A). An arterial cannula 6 Fr (Medtronic, Inc., Minneapolis, MN, USA) for neonates or 8 Fr for infants is directly inserted into the innominate artery or through a Polytetrafluoroethylene (PTFE) graft (for neonates <2.0 kg), previously anastomosed in end-to-side fashion to the innominate artery. A cardioplegia delivery system is inserted into the aortic root: in ductal-dependent descending aortic circulation, the cardioplegia line is initially inserted into the ductus arteriosus (Fig. 1A) and then relocated into the aortic root after ductus excision. A single-stage atrial cannula is used for venous return and a left ventricular vent (Edwards Lifesciences LLC, Irvine, CA, USA) is then introduced through the right upper pulmonary vein. When concomitant repair of intracardiac anomalies is required, bicaval cannulation (Edwards Lifesciences LLC) is used for venous

return. In the latter cases, the aortic root perfusion system is switched to deliver cardioplegia. A schematic of the cardiopulmonary bypass circuit is presented in Fig. 2. Briefly, a blood-based priming solution for bypass is prepared in order to maintain Hb level > 8.5 g/dl. An α -stat acid-base management strategy is used. Under moderate systemic hypothermia (25°C nasopharynx) and low-flow perfusion (25–50 ml/kg/min), left common carotid and left subclavian arteries are snared down to start selective cerebral perfusion. The descending aorta is cross-clamped and a second aortic cross-clamp is placed immediately above the cardioplegia cannula to start selective, controlled and independent coronary perfusion (Fig. 1B and [Supplementary Video 1](#)). During selective coronary perfusion, the left heart is vented (non-working, beating heart). Mean blood pressure in the right radial artery is maintained between 40 and 45 mmHg, cerebral blood flow rate, via the arterial line, regulated at baseline levels of 30–40 ml/kg/min, while myocardial flow rate, via the rotor of the cardioplegia line through the delivery system, at 15–20 ml/kg/min [5]. Aortic arch repair is performed with beating heart and working brain: in cases of severe arch hypoplasia, extensive and lengthy patch augmentation can be carried out accurately ([Supplementary Video 2](#)). During rewarming, the flow rate is progressively increased (upto 150 ml/kg/min). After cardiopulmonary bypass weaning, modified ultrafiltration is routinely applied (Fig. 2).

RESULTS

The technique herein has been successfully applied in nine neonates and infants (median age 11 days), with body weights ranging from 1.6 to 10 kg (median 3.2 kg), having aortic arch patch augmentation (five patients: severe arch hypoplasia in three, Norwood stage I in two) and end-to-side anastomosis (four patients: IAA+VSD in three, arch hypoplasia and aortic

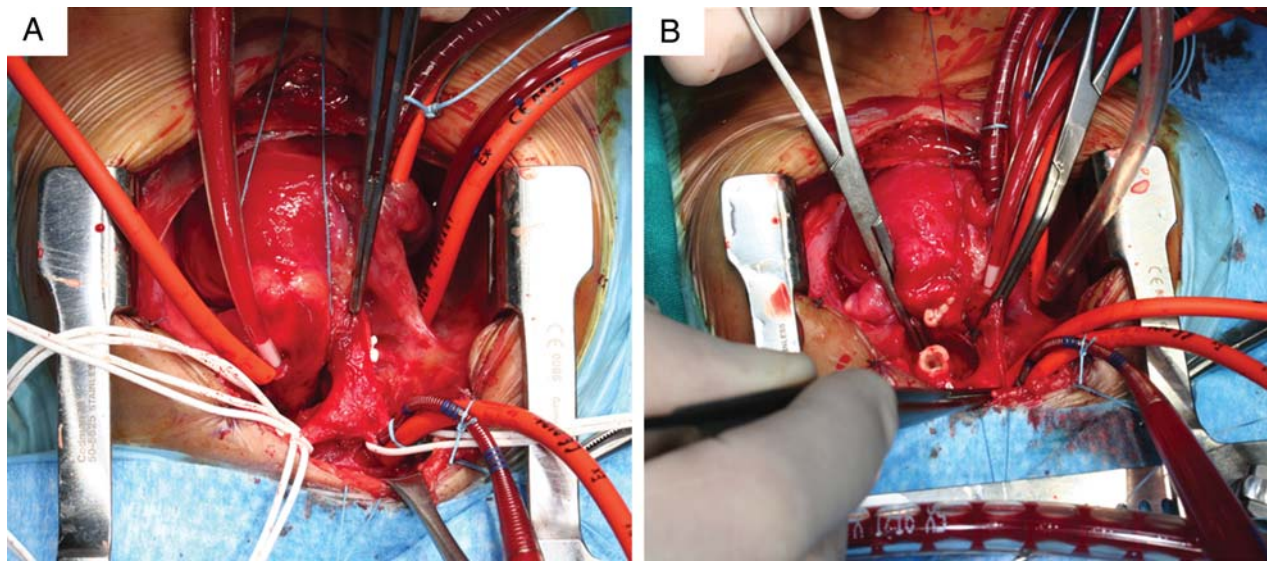


Figure 1. (A) Extracardiac anatomy in newborn with severe arch hypoplasia and coarctation: hypoplastic ascending aorta is also visible. Extensive dissection of ascending and descending aorta, arch vessels and branch pulmonary arteries: snares around the vessels are evident. Innominate artery cannula for systemic (cerebral) perfusion, right atrial for venous return and right superior pulmonary vein for left heart drainage are in place. Cardioplegia delivery system is positioned in ductus arteriosus. Snares around the arch vessels and descending aorta are visible. Branch pulmonary arteries are snared. (B) The innominate artery cannula is advanced distally and snared proximally. An aortic cross-clamp is placed distal to the aortic root cannula, allowing regional myocardial perfusion. An additional aortic cross-clamp is placed in the mid-descending aorta. During selective, independent cerebro-myocardial perfusion, the distal arch has been opened and the ductal tissue resected from the descending thoracic aorta.

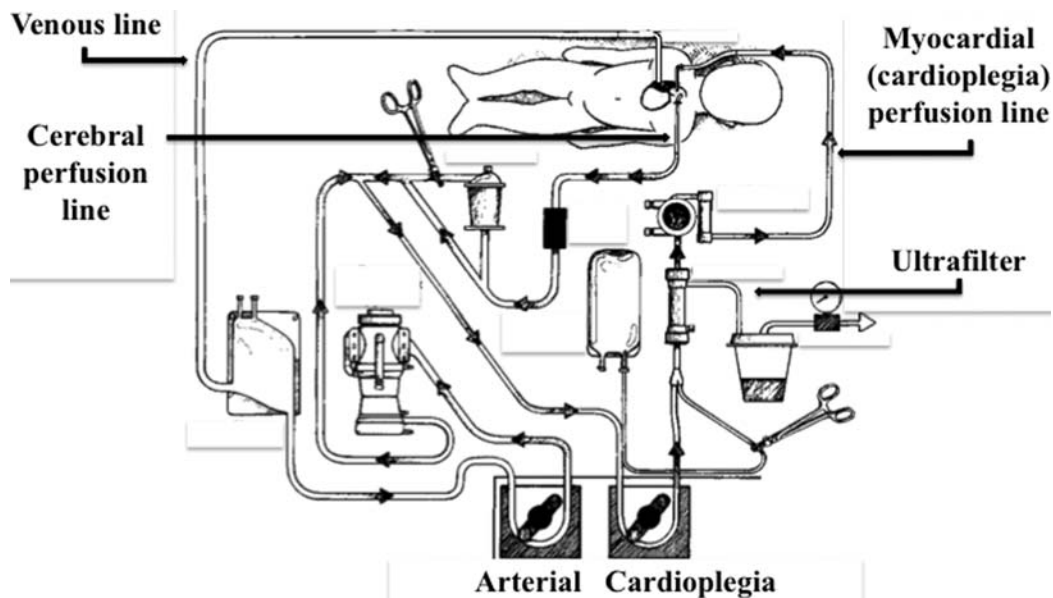


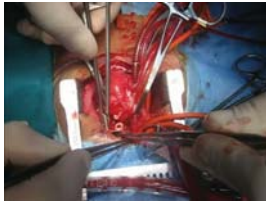
Figure 2. A schematic view of cardiopulmonary bypass circuit for cerebro-myocardial perfusion.

stenosis in one). Peak serum troponin I averaged $16 \pm 42 \mu\text{mol/l}$. Four patients, body weight $<3.0 \text{ kg}$, needed delayed sternal closure (average 7.4 ± 2 days, range 5–10). On early (day 1) post-operative echocardiographic assessment, all but one patient, with hypoplastic left heart syndrome and severe preoperative tricuspid regurgitation, showed preserved left or systemic ventricular function. Average duration of mechanical ventilation was 3.3 ± 5.6 days (range 1–14). One neonate, with IAA+VSD and severe pulmonary hypertension required inhaled nitric oxide administration for 6 days. Average length of ICU stay was 4.8 ± 4.4 days (range 1–13). All patients survived to discharge, but one with

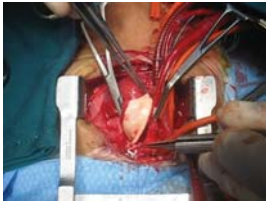hypoplastic left heart syndrome weighing 2.0 kg at stage I palliation, who succumbed to the sequelae of acute limb ischaemia.

COMMENT

The main goal of the current technique is to achieve a separate and controlled management of myocardial and cerebral flows during RLFP. Unlike the dual arterial Y-connected technique previously reported, where relative perfusion properties of brain and heart cannot be regulated [3–5], a novel set-up of simultaneous



Supplementary Video 1: Heart is slowly beating and non-working: during cerebro-myocardial perfusion, the hypoplastic distal aortic arch is opened and ductal tissue is carefully resected.



Supplementary Video 2: During cerebro-myocardial perfusion, on a beating heart, extensive pericardial homograft patch augmentation of the diffusely hypoplastic arch is carefully carried out.

cerebro-myocardial perfusion using two different sources of arterial flow is described here: the cerebral, dependent on the arterial line, and the myocardial, dependent on the cardioplegia delivery system. This method allows independent and controlled regulation of each flow by varying the speed of the individual pump. Advantages of this alternative technique for cerebro-myocardial perfusion include: (i) ability to adjust coronary perfusion in case of signs of ischaemia evident on continuous EKG monitoring; (ii) prompt conversion to cardiac arrest, by switching the perfusate from blood to blood cardioplegia via the same delivery line. This property is particularly advantageous in low body weight (less than 2.0 kg) newborn with hypoplastic ascending aorta (HLHS, IAA), where multiple cannulation of the diminutive arterial vessel may be traumatic, causing adventitial haematoma or even dissection; (iii) facile interface with modified ultrafiltration.

FUNDING

Supported by Institutional Funds from Cariverona Project.

SUPPLEMENTARY MATERIAL

Supplementary material is available at *ICVTS* online.

Conflict of interest: none declared.

REFERENCES

- [1] Pigula FA, Nemoto EM, Griffith BP, Siewers RD. Regional low-flow perfusion provides cerebral circulatory support during neonatal aortic arch reconstruction. *J Thorac Cardiovasc Surg* 2000;119:331–9.
- [2] Visconti KJ, Rimmer D, Gauvreau K, del Nido P, Mayer JE Jr, Hagino I *et al.* Regional low-flow perfusion versus circulatory arrest in neonates: one-year neurodevelopmental outcome. *Ann Thorac Surg* 2006;82:2207–13.
- [3] Kostelka M, Walther T, Geerdts I, Rastan A, Jacobs S, Dähnert I *et al.* Primary repair for aortic arch obstruction associated with ventricular septal defect. *Ann Thorac Surg* 2004;78:2233–9.
- [4] Lim HG, Kim WH, Park CS, Chung ES, Lee CH, Lee JR *et al.* Usefulness of regional cerebral perfusion combined with coronary perfusion during one-stage total repair of aortic arch anomaly. *Ann Thorac Surg* 2010;90:50–7.
- [5] Oppido G, Pace Napoleone C, Turci S, Davies B, Frascaroli G, Martin-Suarez S *et al.* Moderately hypothermic cardiopulmonary bypass and low-flow antegrade selective cerebral perfusion for neonatal aortic arch surgery. *Ann Thorac Surg* 2006;82:2233–9.

eComment. Using selective myocardial perfusion for interrupted aortic arch surgery

Author: Leo A. Bockeria

Bakoulev Scientific Center for Cardiovascular Surgery, Moscow, Russia

doi:10.1093/icvts/ivs120

© The Author 2012. Published by Oxford University Press on behalf of the European Association for Cardio-Thoracic Surgery. All rights reserved.

I have read the article by Luciani *et al.* [1] on an alternative method for neonatal cerebro-myocardial perfusion with great interest. Despite the small number of patients, it is an impressive and stimulating paper, but there are a few points to be considered. The main novelty of this method is the use of the selective pump for independent myocardial perfusion. At the same time, as I understood, in Figure 2, there is an inaccuracy in the direction of blood flow in cerebral perfusion line.

In our opinion, the presented method is convenient and justified only for blood to blood cardioplegia. In all other cases, namely when using crystalloid solutions such as "Custodiol", this only complicates the perfusion circuit and has no visible benefits. In our experience with interrupted aortic arch surgery for neonatals and infants, the traditional method with selective cerebral perfusion and circulatory arrest has been applied. At the same time, complications associated with trauma, dissection, or haematoma of vessels (as described in this article) were not observed.

References

- [1] Luciani GB, De Rita F, Faggian G, Mazzucco A. An alternative method for neonatal cerebro-myocardial perfusion. *Interact CardioVasc Thorac Surg* 2012;14:644–6.