

A complication following ACL reconstruction using bioabsorbable cross-pins

Eugenio Vecchini, Gian Mario Micheloni, Valentina Rita Corbo, Francesco Perusi, Giovanni Dib, Bruno Magnan

University of Verona, Surgery Department - Orthopedic Division, Italy

Summary. This is a case of a proximal pin migration after ACL reconstruction in medial soft tissue with pain, inflammatory reaction and functional reduction. 33-year-old male presented at our clinic with a complete ACL rupture. Reconstruction with autogenous gracilis and semitendinosus hamstring tendons was performed and graft fixed in the femoral canal with two PLLA bioabsorbable pins (RIGIDFIX® Cross Pin System). Two months postoperatively the patient presented swelling and pain on the medial side of the knee, full range of motion and negative results at the Lachman and Pivot shift tests. MRI examination showed the superior femoral tunnel crossing both the lateral and medial cortex lodging the pin in the knee's medial soft tissue corresponding to the swelling area reported by the patient. The tendon graft was properly positioned. After surgical removal of the pin through a small skin incision, the pain and swelling promptly subsided allowing the patient return to normal activities in few weeks without any pain. In our opinion the painful swelling of the knee was due to a displacement of the pin that had been accidentally lodged in the soft tissues instead of the bone causing a foreign-body reaction resulting in granuloma formation with local inflammation. This dislodgement could have been due to an inappropriately long femoral tunnel. (www.actabiomedica.it)

Key words: ACL complication, rigid fix technique, pin migration, bioabsorbable cross-pin

Introduction

ACL injuries are a frequent cause of disability in active individuals and the reconstruction is the sixth most commonly performed orthopedic procedure with more than 100,000 surgeries performed annually in the United States (1,2). Alongside with different graft tissues, a variety of techniques involving different types of fixation have been developed in recent years and are today available and largely used in surgery (3-4). While the choice of graft tissue has received considerable attention for patient outcomes, the method of fixation is of paramount importance in dictating the robustness of the graft construct. The fixation device could represent the weakest link in ACL reconstruction.

Optimal graft fixation should have the following characteristics: structural security, exact replication of the biomechanical properties and biological structure of the original ligament.

Mechanical fixation of the graft can be direct or indirect. On the one hand, direct fixation requires the use of interference screws and staples. On the other, indirect fixation suspends the graft into the bone tunnel and can be categorized in i) cortical, such as Endo Button; ii) cancellous, and iii) cortical-cancellous, such as cross pin fixation. Among these methodologies, the indirect cortical-cancellous fixation delivers the most satisfactory outcome relatively to graft elongation, strength of fixation and stiffness (5-7).

Nowadays, increasing room has been granted to bio-absorbable implants, which are used with signifi-

cant frequency for the internal fixation of fractures, as well as for ACL reconstruction.

In our case we have used the RIGIDFIX® Cross Pin System (Depuy Mitek, Raynham, Massachusetts), which is a bio-absorbable cross pin made of bio-absorbable poly-L-acid (PLLA) used for graft fixation in the femoral system.

This increasingly used system for ACL surgical reconstruction offers many advances over other techniques in terms of reduced operative time, closer joint line fixation and narrower tunnelling for tighter graft fit providing increased pull-out strength, larger graft to bone contact area to maximize bone incorporation thus improving graft stiffness, possibility of different graft choice, undistorted MRI imaging and uncompromised revision surgery (8).

We reported a case of a proximal pin migration in medial soft tissue with pain, inflammatory reaction and functional reduction.

Case report

33-year-old male presented at our clinic because of a sense of right knee instability. Physical examination demonstrated positive Lachman and Pivot shift tests. Three years before he suffered a right knee injury due to motorcycle accident and a complete ACL rupture was later diagnosed with MRI scan. After a short course of rehabilitation he then decided for surgical treatment.

ACL reconstruction with autogenous gracilis and semitendinosus hamstring tendons was performed. After arthroscopic debridement and shaving of the ruptured ACL, tibial and femoral tunnels were prepared using 8-mm reamer, graft inserted and fixed in the femoral canal with two PLLA bioabsorbable pins (RIGIDFIX® Cross Pin System) and with a non-reabsorbable 8 x 30 mm interference screw in the tibial tunnel. Correct placement and tensioning of the new ligament was checked arthroscopically. A concomitant medial meniscus tear was repaired at the time of the operation with bioabsorbable suture.

Two months postoperatively the patient presented at our clinic complaining of a painful swelling on the medial side of the knee, proximal to the supero-

medial edge of the patella that was tender at palpation. On physical examination the knee did not present effusion, had full range of motion and was stable with negative results at the Lachman and Pivot shift tests.

MRI examination showed the superior femoral tunnel crossing both the lateral and medial cortex lodging the pin in the knee's medial soft tissue (Figures 1-3) corresponding to the swelling area reported by the patient. The tendon graft was properly positioned.

After surgical removal of the pin through a small skin incision, the pain and swelling promptly subsided allowing the patient return to normal activities in few weeks without any pain.

Discussion

The RigidFix Cross Pin System (Depuy Mitek) places two bioabsorbable pins across the femur traversing the femoral tunnel for secure femoral fixation of the graft tissue working as transverse suspension bar perpendicular to pullout forces (6,7).

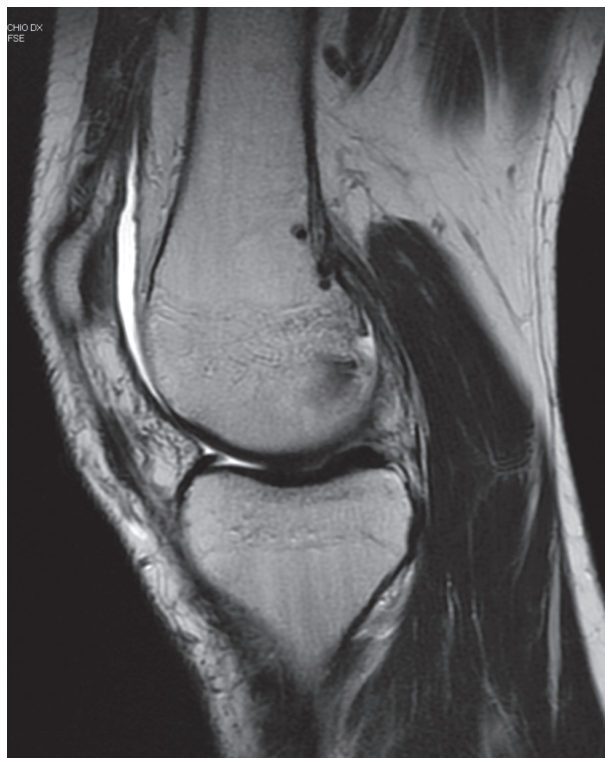

Figure 1. MRI T2 image shows the extremely posterior position of femoral tunnels

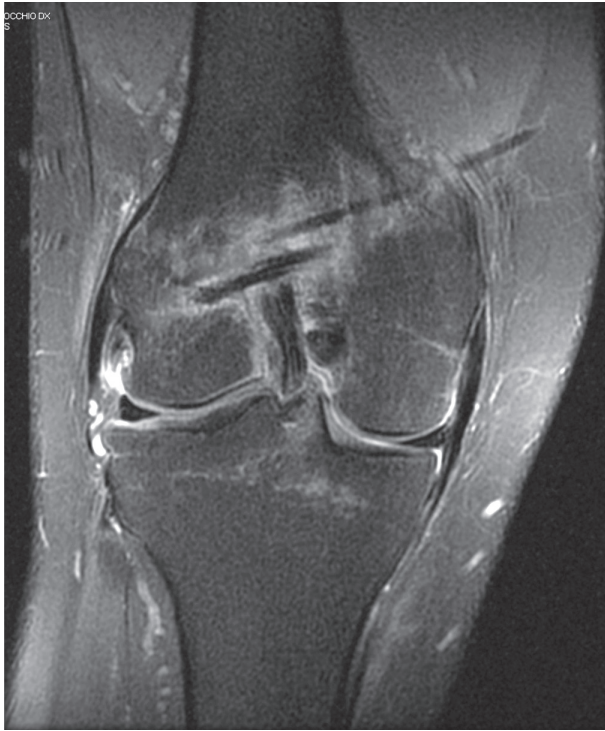

Figure 2. MRI STIR image shows the pin in soft tissues over the proximal femoral pin's tunnel

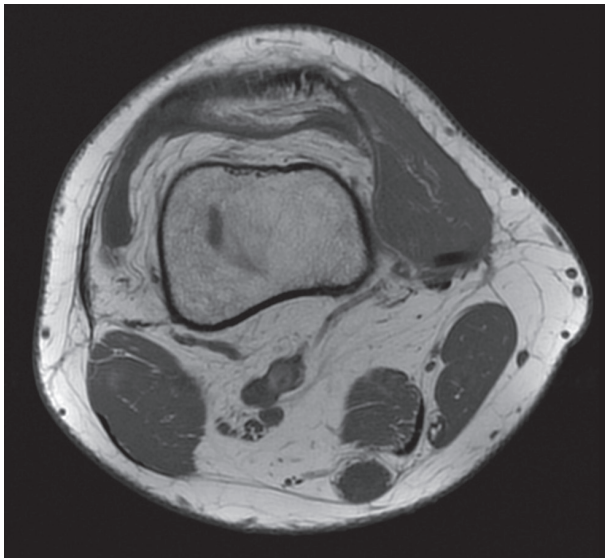


Figure 3. MRI T1 image shows pin complete migration in medial distal femoral soft tissues

The most common materials used for bio-absorbable implants are: polyglycolic acid (PGA), polylactic acid (PLA) including poly-L-lactide (PLLA) and poly-D-lactide (PDLA), and polydioxanone (PDO). PLLA

is the isomer of polylactic acid: it is hydrophobic, crystalline, it degrades more slowly than PGA (i.e. it can take up to 5 years for PLLA to completely degrade) and induces fewer inflammatory processes (9-12).

Biomechanical studies support the use of re-absorbable pin fixation, that provide high fixation strength and sufficient resistance against slippage in comparison with interference screw fixation and other similar devices (5). PLLA pins offer compatible results in terms of elongation, fixation strength and stiffness (13) compared to titanium pins, furthermore allow undistorted MRI imaging, uncompromised revision surgery, avoiding fatigue fracture at the graft implant interface (14).

Regarding clinical studies with long-term follow up there is a paucity of evidence in literature. Harilainen et al. in a controlled prospective randomized study demonstrated no statistically or clinically differences between cross-pin femoral fixation and interference screw fixation at 2-year follow up (15). Other studies compared different fixation devices with cross-pin showed no differences between the two surgical options (16,17).

However, as reported in our case report, several complication of RigidFix have been described in literature: lateral pin slip, implant protrusion, tunnel widening (18) and pin breakage (19).

Studler et al in a recent retrospective study on 202 patients treated with Rigid fix reported after 26 months of follow up in 28% of the patients breakage of the posterior femoral cortex, in 17% founding of fractured cross-pins and in 6% migration of fractured pin fragments (20).

Kokkinakis et al documented three cases of ili-otibial band friction syndrome (21), Misra et al presented one case of a patient with intra-articular pin translation into the medial retinacular area (22) and Marx and Spock documented lateral and medial pin migration in two patients probably due to technical error in positioning of the femoral tunnel (23). Also stress fractures of the medial femoral supracondylar area are reported potentially secondary to an accelerated rehabilitation program and the cortical hole of the cross-pin guide.

While the correlation of the pin breakage or migration and knee stability is debated, clinical com-

plications due to fractures of Rigid fix bioabsorbable cross pin such as chondral lesion on lateral femoral and tibial condyle (24) and painful sensation during leg extension (25) are reported.

In our opinion the painful swelling of the knee was due to a displacement of the pin that had been accidentally lodged in the soft tissues instead of the bone thus causing a foreign-body reaction resulting in granuloma formation with local inflammation. This dislodgement could have been due to an inappropriately long femoral tunnel. No intrarticular complication has been observed.

Like other authors we didn't encounter failure of the graft or post-surgery knee instability. The complications associated with bioabsorbable pin very rarely affect the clinical outcome of surgery as Ahn and Studler demonstrated (18-20), and result in minor clinical problems, most commonly pain or effusion. These are usually successfully corrected by removal of the broken or dislodged pin with complete resolution of symptoms and preservation of ACL graft function.

The mechanisms responsible for such events, in addition to the one we report, are posterior femoral wall blowout caused by a too much vertically oriented tibial tunnel as reported by Han (25), a too much caudal or posterior orientation of pins tunnel when drilled in the bone resulting in invasion of the articular cavity (22).

Most of these events were likely initiated when drilling graft and pin tunnels.

Time from surgery to symptoms presentation could vary from months to years, is therefore extremely important to create correctly oriented tunnels avoiding full-thickness crossing of contralateral cortex or capsula with invasion of joint space.

References

- Gianotti SM, Marshall SW, Hume PA, Bunt L. Incidence of anterior cruciate ligament injury and other knee ligament injuries: a national population-based study. *J Sci Med Sport* 2009; 12(6): 622-7.
- Graham SM, Parker RD. Anterior cruciate ligament reconstruction using hamstring tendon grafts. *Clin Orthop Relat Res* 2002; 402: 64-75.
- Aglietti P, Buzzi R, Menchetti PM, Giron F. Arthroscopically assisted semitendinosus and gracilis tendon graft in reconstruction for acute anterior cruciate ligament injuries in athletes. *Am J Sports Med* 1996; 24: 726-31.
- Noojin FK, Barret GR, Hartzog CW, Nash CR. Clinical comparison of intrarticular anterior cruciate ligament reconstruction using autogenous semitendinosus and gracilis tendons in men versus women. *Am J Sports Med* 2000; 28: 783-9.
- Ahmad CS, Gardner TR, Groh M, Arnouk J, Levine N. Mechanical properties of soft tissue femoral fixation devices for anterior cruciate ligament reconstruction. *Am J Sports Med* 2004; 32(3): 635-40.
- Zantop T, Weibers B, Weimann A, et al. Biomechanical evaluation of a new cross-pin technique for the fixation of different sized bone-patellar tendon-bone grafts. *Knee Surg Sports Traumatol Arthrosc* 2004; 12(6): 520-7.
- Kousa P, Järvinen TL, Vihavainen M, Kannus P, Järvinen M. The fixation strength of six hamstring tendon graft fixation devices in anterior cruciate ligament reconstruction. Part II: tibial site. *Am J Sports Med* 2003; 31(2): 182-8.
- Cossey AJ, Kalairajah Y, Morcom R, Spriggins AJ. Magnetic resonance imaging evaluation of biodegradable transfemoral fixation used in anterior cruciate ligament reconstruction. *Arthroscopy* 2006; 22(2): 199-204.
- Pihlajamaki H, Böstman O, Tynnenen O, Laitinen O. Long term tissue response to bioabsorbable poly-L-lactide and metallic screws: an experimental study. *Bone* 2006; 39: 392-7.
- Bostman O, Pihlajamaki H. Clinical biocompatibility of biodegradable orthopaedic implants for internal fixation: a review. *Biomaterials* 2000; 21: 2615-21.
- Bostman OM, Pihlajamaki HK. Adverse tissue reactions to bioabsorbable fixation devices. *Clin Orthop Relat Res* 2000; 371: 216-27.
- Burkart A, Imhoff AB, Roscher E. Foreign-body reaction to the bioabsorbable suretac device. *Arthroscopy* 2000; 16: 91-5.
- Milano G, Mulas PD, Ziranu F, Piras S, Manunta A, Fabriciani C. Comparison between different femoral fixation devices for ACL reconstruction with doubled hamstring tendon graft: a biomechanical analysis. *Arthroscopy* 2006; 22(6): 660-8.
- Clark R, Olsen RE, Larson BJ, Goble EM, Farrer RP. Cross-pin femoral fixation: a new technique for hamstring anterior cruciate ligament reconstruction of the knee. *Arthroscopy* 1998; 14(3): 258-67.
- Harilainen A, Sandelin J, Jansson KA. Cross-pin femoral fixation versus metal interference screw fixation in anterior cruciate ligament reconstruction with hamstring tendons: results of a controlled prospective randomized study with 2-year follow up. *Arthroscopy* 2005; 21(1): 25-33.
- Rose T, Hepp P, Venus J, Stockmar C, Josten C, Lill H. Prospective randomized clinical comparison of femoral transfixation versus bioscrew fixation in hamstring tendon ACL reconstruction—a preliminary report. *Knee Surg Sports Traumatol Arthrosc* 2006; 14(8): 730-8.
- Price R, Stoney J, Brown G. Prospective randomized comparison of endobutton versus cross-pin femoral fixation in

- hamstring anterior cruciate ligament reconstruction with 2-year follow-up. *ANZ Journal of Surgery* 2010; 80(3): 162-5.
18. Ahn JH, Lee YS, Ha HC. Anterior cruciate ligament reconstruction with preservation of remnant bundle using hamstring autograft: technical note. *Arch Orthop Traum Surg* 2009; 129(8): 1011-5.
19. Choi NH, Lee JH, Victoroff BN. Do broken cross-pins compromise stabilize after anterior cruciate ligament reconstructions with hamstring tendons?. *Arthroscopy* 2007; 23(12): 1334-40.e2.
20. Studler U, White LM, Naraghi AM, et al. Anterior cruciate ligament reconstruction by using bioabsorbable femoral cross pins: MR imaging findings at follow-up and comparison with clinical findings. *Radiology* 2005; 255(1): 108-16.
21. Kokkinakis M, Ashmore A, El-Guindi M. Intraoperative complications using the Bio-Transfix femoral fixation implant in anterior cruciate ligament reconstruction. *Arch Orthop Traum Surg* 2010; 130(3): 375-9.
22. Misra R, Strover A, El-Shazly M. Intra-articular protrusion of malpositioned transfix implant following anterior cruciate ligament reconstruction. *Arthroscopy* 2006; 22(2): 226e1-e4.
23. Marx RG, Spock CR. Complications following hamstring anterior cruciate ligament reconstruction with femoral cross-pin fixation. *Arthroscopy* 2005; 21(6): 762.e1-e3.
24. Papastergiou SG, Koukoulis E, Dimitriadis T, Pappis G, Parisi CA. RigidFix femoral fixation: a test for detecting inaccurate cross pin positioning. *Arthroscopy* 2007; 23(11): 1247.e1-e3.
25. Han I, Kim YH, Yoo JH, Seong SC, Kim TK. Broken bioabsorbable femoral cross-pin after anterior cruciate ligament reconstruction with hamstring tendon graft: a case report. *Am J Sports Med* 2005; 33(11): 1742-5.

Correspondance:

Gian Mario Micheloni MD

University of Verona,

Surgery Department - Orthopedic Division

Polo Chirugico P. Confortini

37134 Verona, Italy

Tel. +39 0458123276

Fax +39 0458123578

E-mail: gianmario.micheloni@libero.it