

Rotational osteoplasty and bioabsorbable polylactate pin fixation in Pipkin type 2 fracture with acute osteochondral defect: a case report

Tommaso Maluta, Gian Mario Micheloni, Andrea Sandri, Dario Regis, Alessandro Costanzo, Bruno Magnan

Department of Orthopaedic Surgery, Azienda Ospedaliera Universitaria Integrata, Polo Chirurgico P. Confortini, Verona, Italy

Summary. Pipkin fractures are relative rare high-energy lesions characterized by an intra-articular fracture of the femoral head after posterior hip dislocation. Early anatomic reduction and stable fixation are the main goals of treatment. This case evaluates the outcome of managing Pipkin type 2 fracture with acute osteochondral defect of the femoral head using “rotational osteoplasty” and bioabsorbable polylactate pin fixation. 24-year-old male patient was involved in a motorcycle accident, suffering from a left hip fracture-dislocation, and pelvic Computed Tomography revealed a Pipkin type 2 lesion. An open urgent treatment was performed. After anatomic reduction of the femoral head fragment a large osteochondral defect in the anterior-superior weight bearing surface was evident. The pattern of the fracture allowed us to perform a “rotational osteoplasty” including rotation of the femoral head fragment, to obtain an osteochondral cartilage congruence of the anterior-superior surface. Stable fixation was obtained by three bioabsorbable polylactate pins. At four-year follow up the patient had an excellent outcome and Magnetic Resonance Imaging (MRI) showed fracture healing, minimal signs of arthritis, excluding osteonecrosis of the femoral head. The reported case confirms that Pipkin fractures are very insidious surgical urgencies. In selected cases, “rotational osteoplasty” may be an alternative to osteochondral transplant for acute osteochondral defect of the femoral head. Bioabsorbable polylactate pin fixation allowed us to have a stable fixation evaluating the bone healing process and vitality of femoral head by MRI. (www.actabiomedica.it)

Key words: Pipkin fracture, femoral head fracture, osteochondral injury, osteochondral defect, rotational osteoplasty, osteochondral transplant, bioabsorbable pin

Introduction

Pipkin type 2 lesions are relative rare but severe high energy injuries characterized by an intra-articular fracture of the femoral head cephalad to the fovea capitis following posterior hip dislocation (1-4).

Early anatomic reduction and stable fixation are the main goals of treatment of these lesions to reduce the risk of avascular femoral head necrosis of the femoral head and post-traumatic osteoarthritis of the hip

joint (5). Surgical options to treat these lesions include fragment excision, open reduction and internal fixation or prosthetic replacement (2, 3, 6). Surgical treatment of an acute osteochondral defect of the femoral head after Pipkin type 2 fracture has been rarely described in literature (7, 8). We present the second case of fracture of the femoral head with acute osteochondral defect in weight-bearing portion after Pipkin type 2 fracture treated by “rotational osteoplasty”, that was recently reported by Au et al (8). Fracture fixation was

performed using multiple bioabsorbable polylactate pins. The patient was informed that the data concerning this case would be submitted for publication.

Case Report

On November 1, 2009, a 24-year-old male patient, with BMI 23, was involved in a motorcycle accident, suffering from a high-energy trauma on the left hip like a dashboard injury. On admission to the emergency room, the patient was in a stable haemodynamic condition with no vascular, neurological, chest and abdominal lesions but his left lower extremity was very painful, shorter and forced into internal rotation. Pelvic radiograph and Computed Tomography (CT) revealed left posterior hip dislocation and concomitant fracture of the femoral head cephalad to the fovea centralis classified as Pipkin type 2 fracture (2) (Figure 1). No closed reduction was attempted in order to prevent further fragmentation of the femoral head. Un-

der general anesthesia, an open urgent treatment was performed using an antero-lateral Watson-Jones approach. The leg was adducted and externally rotated to evaluate the acetabular cavity and expose the femoral head. Intraoperatively, the severity of the lesion was confirmed, as it consisted of larger head fragment and smaller articular fragments including a wide area of bone and cartilage loss (Figure 2). A first anatomic reduction of the femoral head fragment resulted in an osteochondral defect in the anterior-superior weight-bearing region. The pattern of the fracture allowed to perform rotational osteoplasty consisting in rotation of the femoral head fragment to obtain an osteochondral cartilage congruence of the antero-superior surface. Rotation of fragment created a residual defect in the inferior not weight bearing surface. Three bioabsorbable POLI-L/DL pins (Smart Pin®, Conmed Linvatec, Tampere, Finland), 2.0 mm diameter x 40 mm length, were used to fix the large femoral fragment (Figure 3). At the end of the surgical procedure, the hip range of motion was checked to rule out any joint impingement.

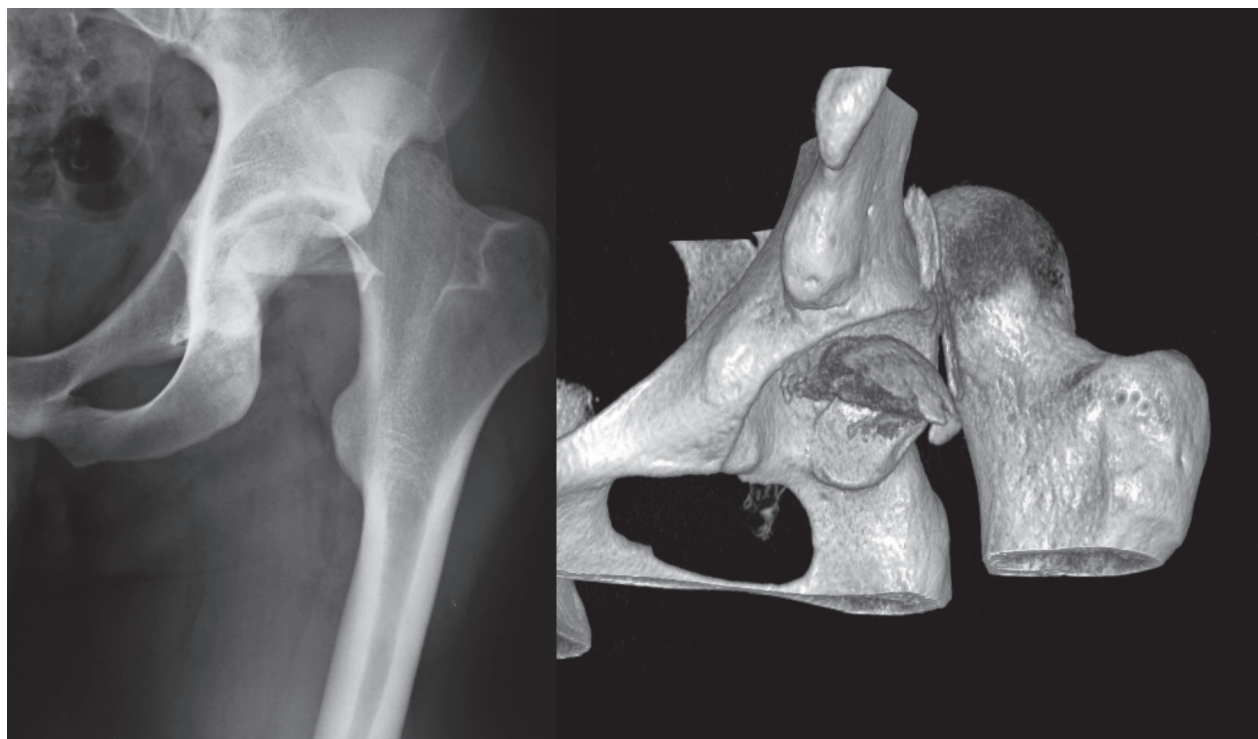


Figure 1. Preoperative Pelvic X-Ray and 3D CT scan showing posterior hip dislocation and large intrarticular fragment of the femoral head

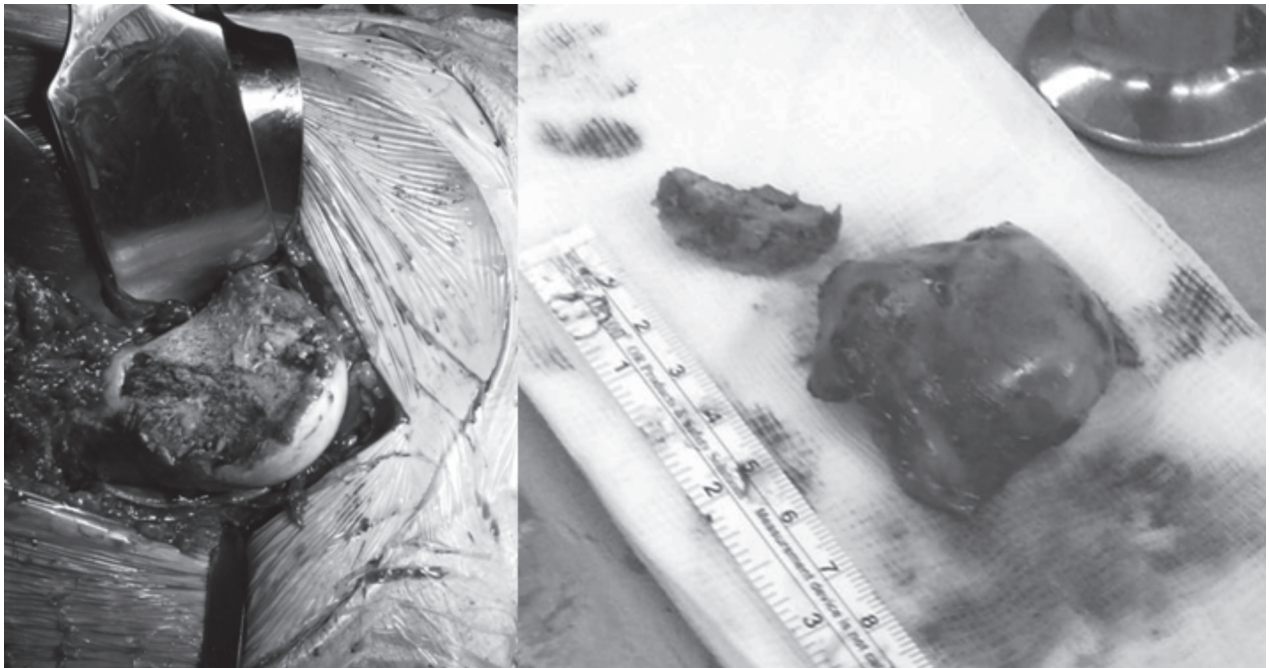


Figure 2. Intraoperative photographs showing a large zone of bone and cartilage loss in the femoral head. Note the femoral head fragments

Post-operative x-rays and CT scan of the hip demonstrated a quite large area of bone and cartilage loss with an acceptable articular congruity. The patient received a 10-day course of 150 mg/die of indomethacin for heterotopic ossification prophylaxis. Four weeks after surgery passive rehabilitation started, but weight bearing was allowed 6 weeks later.

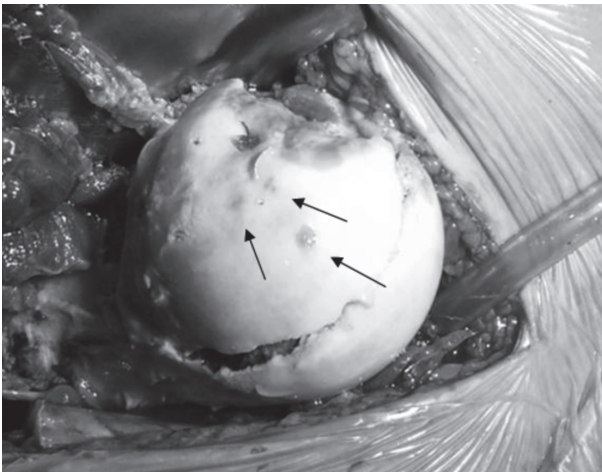


Figure 3. Intraoperative reduction and fixation with three pins (arrows) of the articular surface of the femoral head. Note the residual articular cartilage loss

Four month after surgery, x-rays showed fracture healing. MRI and x-rays performed one year after surgery revealed bone remodeling of the fragment, similar to an osteonecrosis lesion, excluding any blood supply impairment of the femoral head. Complete bone healing and initial signs of hip arthritis were detected 2 years postoperatively.

At 4-year follow up the patient had an excellent functional result with an Harris Hip Score of 99,65 (9). Pelvic MRI and CT showed fracture healing with minimal signs of arthritis, excluding avascular femoral osteonecrosis (Figure 4).

Discussion

Pipkin fractures are relative rare high-energy lesions characterized by an intra-articular fracture of the femoral head following posterior hip dislocation. In 1957 Pipkin described four types of lesion: type 1, dislocation with fracture of the femoral head caudal to the fovea capitis femoris; type 2, dislocation with fracture of the femoral head cephalad to the fovea capitis femoris; type 3, type 1 or 2 associated with fracture of

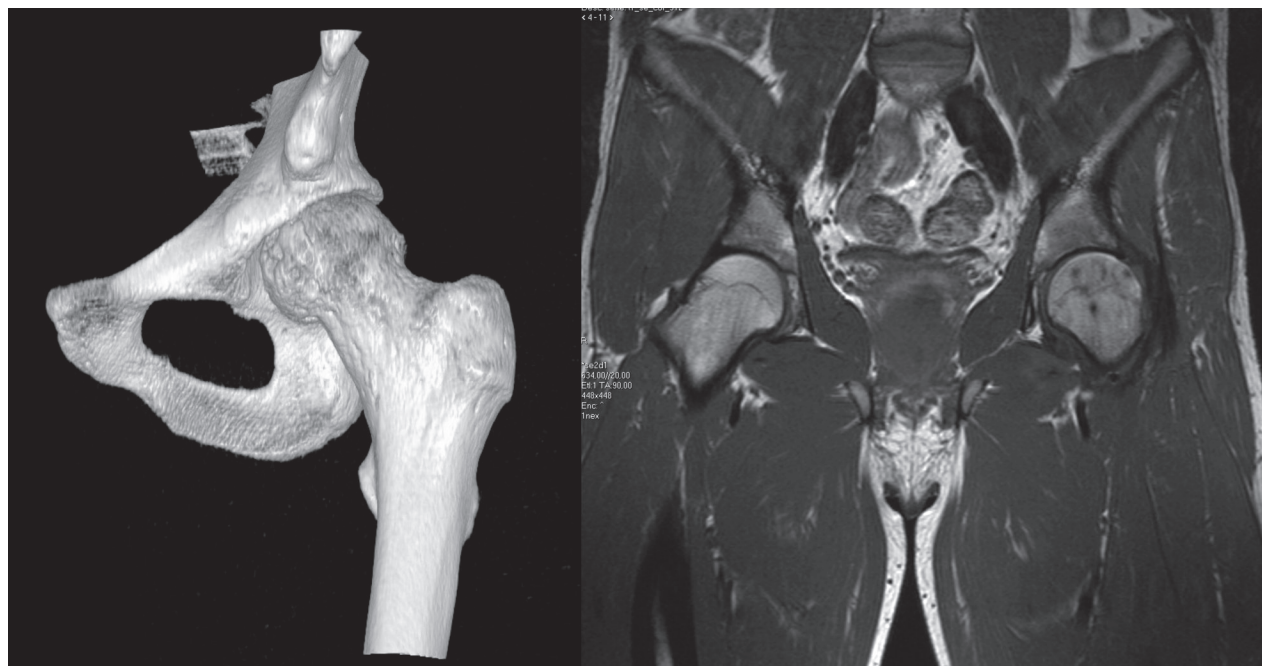


Figure 4. 4-year follow up 3D CT scan and MRI showing bone healing with no signs of avascular femoral necrosis

the femoral neck; type 4, type 1 or 2 associated with fracture of the acetabular rim (2).

The most common injury mechanism in these type of fracture is the so called dashboard injury (4). Femoral head fractures associated with traumatic hip dislocation are due to an impact that forced the femoral head to the posterior rim of the acetabulum, leading to posterior dislocation of the femoral head (10-12). The severity of the lesion depends on the position of the hip and the direction of the force during the trauma. These type of lesions are true orthopaedic urgency and a reduction should be performed as soon as possible. Some authors suggested primary open reduction to prevent damage of injured soft tissues and joint space caused by harmful fragments (1, 11). Other studies supported an initial closed reduction followed by CT or MRI evaluation to check the congruence of the fragments (10, 12-15). An attempt of closed reduction could be dangerous causing further trauma or even a fracture of the injured femoral head, leading to a more difficult fixation (10, 11). Undoubtedly CT scan evaluation in addition to x-rays is necessary as soon as possible to perform the correct classification and the best treatment of these lesions, helping the sur-

geon to plan the operative approach to be utilized (12). Different surgical approaches have been used for the management of Pipkin lesion, but no statistically significant differences in terms of heterotopic ossification and avascular necrosis of the femoral head have been demonstrated (16).

Several treatment options have been described in literature, from simple closed reduction to prosthetic replacement. A systematic review of 29 articles highlights that 241 out of 293 cases (82.3%) required operative treatment, in particular ORIF (17). Fragment removal is rare (20.6%) and could be very dangerous, because the fracture line passes through a weight-bearing area. Another surgical option is represented by prosthetic replacement. Several articles suggested this treatment especially for Pipkin 3 and 4, but they concluded that a primary reconstruction should be always attempted, in particular in young patients (18).

In Pipkin type 2 lesion the impact of the femoral head to the posterior rim of the acetabulum may cause an acute osteochondral defect in the weight bearing part of the femoral head (7,8). The treatment of acute osteochondral defect in the anterior-superior weight-bearing part of the femoral head after traumatic hip

dislocation has been rarely described. Nam et al (7) reported two cases of traumatic focal chondral defect in the antero-superior weight bearing part of the femoral head treated by osteochondral autograft transplantation from the ipsilateral knee and the inferior aspect of the femoral head respectively with a good clinical outcome and a good autograft incorporation with maintenance of articular surface conformity on MRI evaluation at 1 and 5 year follow-up. Au et al (8) managed a 33 year old male patient who sustained a Pipkin-type 2 fracture using a modified lateral Hardinge approach, after a first reduction of the fragment of the femoral head, a significant osteochondral defect (2x4cm) was present on the weight bearing portion. In order to reconstruct the destroyed articular firstly described "rotational osteoplasty" by rotating the femoral head fragment such that the weight-bearing area had an intact and congruent articular surface. This author used patient's existing fracture line to perform the rotation and the femoral head fragment was fixed using 3.5 mm screws countersunk below the articular cartilage. At 13-month follow up CT scan showed healing of the femoral head. Our article reports the second case of Pipkin type 2 lesion treated by rotational osteoplasty with a considerably longer follow-up. We performed stabilization with three bioabsorbable pins because our lesion consisted of only one single fragment. Disposition of the three pins, at three angles of an ideal triangle, was a good choice for the distribution of the weight bearing improving a stable fixation without rotational movement. Moreover, the thin diameter of the pins (2.0 mm) allowed us to be less invasive than other surgeons (15,19).

Osteosynthesis of the fragment with stainless steel or titanium screws is described but potential disadvantages could be stress shielding, allergic reactions, late infection and intolerance fixation (20). On the other hand, synthetic biodegradable polymers like bioabsorbable polylactate seem to be a better choice in term of biocompatibility, not requiring removal. There are only a few studies describing the use of bioabsorbable devices for the treatment of Pipkin fractures. In 1998, Jukkala-Partio et al first reported promising results in six femoral head fracture-dislocations with an average 38-month follow up (21). Seven years later, Hermus et al described the successful 12-month outcome of a

Pipkin IV fracture treated with 2 bioabsorbable screws (22). Nine cases, including a type 2 fracture treated with 6 POLI-L/DL pins (three 2.7-mm Polypins and three 2.0-mm Polypins), were reviewed by Prokop et al (15). At 42.3-month follow-up a very good result was obtained (15 points according to Merle d'Aubigné and Postel scale). Unfortunately, the number of fracture fragments is not detailed, as in our opinion 6 pins can adversely affect the blood supply of the femoral head. In a randomized study, Chen et al found that the outcome of nonoperative treatment of Pipkin type 2 fractures was worse than that of the surgical group treated with 2 to 3 bioabsorbable screws (2.5-3.0-mm diameter) via a Smith-Petersen approach (19).

Fracture-dislocation of the femoral head includes the risk for avascular necrosis. MRI is effective for evaluating and following up the development of avascular necrosis of the femoral head. However, one of the limitation is the image distortion using ferromagnetic screw fixation. Titanium hardware screws or bioabsorbable polylactate screws avoid artifacts and field distortion in MRI. In our case, the use of bioabsorbable polylactate pins has provided artifacts-free images to better evaluate healing and vitality of the femoral head.

In conclusion, the reported case confirms that Pipkin fractures are very insidious surgical urgencies for their intricate procedures and poor short-midterm outcomes. In selected patients, according to the pattern and line of fracture, rotational osteoplasty should represent an effective surgical option to treat acute osteochondral loss in fracture of the femoral head. The reported case confirms the advantages of bioabsorbable pin fixation to reduce MRI artifacts allowing better evaluation of bone healing, cartilage state and osteonecrosis of the femoral head.

References

1. Birkett J. Description of a dislocation of the head of the femur, complicated with its fracture; with remarks by John Birkett (1815-1904). *Clin Orthop Relat Res* 2000; 377: 4-6.
2. Pipkin G. Treatment of grade IV fracture-dislocation of the hip. *J Bone Joint Surg Am* 1957; 39A(5): 1027-42.
3. Butler JE. Pipkin type-II fractures of the femoral head. *J Bone Joint Surg Am* 1981; 63(8): 1292-6.

4. Davis JB. Simultaneous femoral head fracture and traumatic hip dislocation. *Am J Surg* 1950; 80(7): 893-5.
5. Kloen P, Siebenrock KA, Raaymakers E, Marti RK, Ganz R. Femoral head fractures revisited. *Eur J Trauma* 2002; 28(4): 221-33.
6. Roeder Jr LF, DeLee JC. Femoral head fractures associated with posterior hip dislocation. *Clin Orthop Relat Res* 1980; 147: 121-30.
7. Nam D, Shindle MK, Buly RL, Kelly BT, Lorch DG. Traumatic osteochondral injury of the femoral head treated by mosaicplasty: a report of two cases. *HSS J* 2010; 6(2): 228-34.
8. Au B, Jamieson MD, Banerjee R. Rotational osteoplasty for femoral head fracture with cartilage loss. *Orthopedics* 2013; 36(1): e105-8.
9. Harris WH. Traumatic arthritis of the hip after dislocation and acetabular fractures: treatment by mold arthroplasty. An end-result study using a new method of result evaluation. *J Bone Joint Surg Am* 1969; 51(4): 737-55.
10. Stannard JP, Harris HW, Volgas DA, Alonso JE. Functional outcome of patients with femoral head fractures associated with hip dislocations. *Clin Orthop Relat Res* 2000; 377: 44-56.
11. Epstein HC, Wiss DA, Cozen L. Posterior fracture dislocation of the hip with fractures of the femoral head. *Clin Orthop Relat Res* 1985; 201: 9-17.
12. Henle P, Kloen P, Siebenrock KA. Femoral head injuries: which treatment strategy can be recommended? *Injury* 2007; 38(4): 478-88.
13. Keel MEK, Isler B, Trentz O. The role of surgical hip dislocation in the treatment of acetabular and femoral head fractures. *Eur J Trauma* 2005; 2: 138-47.
14. Mostafa MM. Femoral head fractures. *Int Orthop* 2001; 25(1): 51-4.
15. Prokop A, Helling HJ, Hahn U, Udomkaewkanjana C, Rehm KE. Biodegradable implants for Pipkin fractures. *Clin Orthop Relat Res* 2005; 432: 226-33.
16. Guo JJ, Tang N, Yang HL, Qin L, Leung KL. Impact of surgical approach on postoperative heterotopic ossification and avascular necrosis in femoral head fractures: a systematic review. *Int Orthop* 2010; 34(3): 319-22.
17. Giannoudis PV, Kontakis G, Christoforakis Z, Akula M, Tosounidis T, Koutras C. Management, complications and clinical results of femoral head fractures. *Injury* 2009; 40(12): 1245-51.
18. Yoon TR, Rowe SM, Chung JY, Song EK, Jung ST, Anwar IB. Clinical and radiographic outcome of femoral head fractures: 30 patients followed for 3-10 years. *Acta Orthop Scand* 2001; 72: 348-53.
19. Chen ZW, Zhai WL, Ding ZQ, et al. Operative versus nonoperative management of Pipkin type-II fractures associated with posterior hip dislocation. *Orthopedics* 2011; 34(5): e12-e17.
20. Spector M, Cease C, Tong-li X. The local tissue response to biomaterials. *Crit Rev Biocompatibility* 1989; 5: 269-95.
21. Jukkala-Partio K, Partio EK, Hirvensalo E, Rokkanen P. Absorbable fixation of femoral head fractures: A prospective study of six cases. *Ann Chir Gynaecol* 1998; 87(1): 44-8.
22. Hermus JP, Laan CA, Hogervorst M, Rhemrey SJ. Fixation of a Pipkin fracture with bio-absorbable screws. Case report and a review of the literature. *Injury* 2005; 36(3): 458-61.

Correspondance:

Tommaso Maluta, MD

First Assistant, Department of Orthopaedic Surgery,

Azienda Ospedaliera Universitaria Integrata,

Polo Chirurgico P. Confortini, Verona, Italy

Tel. +390458123578

Fax +390458123578;

E-mail: tommasomaluta@yahoo.it