



UNIVERSITA' DEGLI STUDI DI VERONA
DIPARTIMENTO DISANITÀ PUBBLICA E MEDICINA DI COMUNITÀ
SEZIONE DI PSICHIATRIA E PSICOLOGIA CLINICA

SCUOLA DI DOTTORATO DI
SCIENZE MEDICINA E INGEGNERIA

DOTTORATO DI RICERCA IN
SCIENZE PSICOLOGICHE E PSICHIATRICHE

XXIV CICLO - 2009

TESI DI DOTTORATO

A structural magnetic resonance imaging study
of Orbitofrontal Cortex in Psychosis

S.S.D. MED/25 PSICHIATRIA

Coordinatore: Prof.ssa MIRELLA RUGGERI

Firma _____

Tutor: dr. PAOLO BRAMBILLA

Firma _____

Dottorando: Dott.ssa STEFANIA CERRUTI

Firma _____

ABSTRACT

BACKGROUND: The orbitofrontal cortex (OFC) is the most inferior and ventral region of the prefrontal cortex that lies above the orbits. Through its connections with the amygdala, hippocampus, thalamus, dorsolateral prefrontal cortex and superior temporal lobe, it is involved in several cognitive processes, such as sensory integration, reward mechanism, decision-making, mood regulation and impulse control. OFC dysfunction is implicated in cognitive, affective and social impairments similar to those present in schizophrenia. Although with some inconsistencies, there is evidence that OFC volumes are reduced in schizophrenia, and that they may be associated with psychopathology and altered cognition. However, it is still not clear whether OFC deficits are present before the onset of the disease or whether they occur with the progression of the illness.

OBJECTIVES: The aims of the study were to measure the volumes of the OFC and its subregions, as traced on MRI scans, in a group of schizophrenia patients (SCZ), in a group of First Episode Psychosis patients (FEP), recruited in the context of the Psychosis Incident Cohort Outcome Study (PICOS), and in a group of healthy controls (HC) and to investigate the changes in OFC volumes over time in this cohort.

METHODS: socio-demographical and clinical data were initially acquired from 26 SCZ patients, 16 FE patients and 21 HC subjects. The MRI sessions were conducted using a 1.5 T scanner and the images were analyzed using the BRAINS2 software. Subjects were scanned the second time after a mean follow up period of 3 years. The OFC and its medial and lateral subregions were traced and they were segmented for grey and white matter.

RESULTS: In the cross sectional comparison, both the white and grey matter of the left lateral OFC was found to be increased in SCZ patients in respect to FEP patients and HC. In the longitudinal comparison the OFC grey matter volume of FEP patients had a greater decrease across time than those of chronic SCZ patients and HC.

DISCUSSION: The left lateral OFC seems to be a brain region particularly affected by volume alteration in schizophrenia. The OFC grey matter reduction in FEP patients across time might confirm the assumption that brain volume is more affected by loss in the very first time of the illness.

INDEX

1. BACKGROUND OF THE SUDY.....	Pag 5
1.1 Psychosis and brain imaging.....	Pag 5
1.2 Schizophrenia: Developmental and degenerative hypotheses...	Pag 6
1.3 Frontal lobes and schizophrenia.....	Pag 7
1.3.1. Cross Sectional studies.....	Pag 9
1.3.2. Longitudinal studies on the frontal lobes.....	Pag 10
1.4 Orbito Frontal Cortex.....	Pag 11
1.4.1. Cross Sectional studies.....	Pag 12
1.4.2. Longitudinal studies on the frontal lobes.....	Pag 15
2. AIM OF THE STUDY.....	Pag 17
3. METHOD.....	Pag 18
3.1 Sample recruitment.....	Pag 18
3.2 MRI acquisition and image processing.....	Pag 21
4. STATISTICAL ANALYSIS.....	Pag 26
4.1 Socio demographical characteristics.....	Pag 26
4.2 Cross sectional analysis baseline and follow up.....	Pag 27
4.3 Longitudinal analysis.....	Pag 27
5. RESULTS.....	Pag 28
5.1. Sample characteristics.....	Pag 28

5.2 Cross sectional analysis.....	Pag 29
5.2.1 ANCOVA baseline.....	Pag 29
5.2.2 ANCOVA follow up.....	Pag 30
5.2.3. Spearman correlations.....	Pag 31
5.3 Longitudinal analysis.....	Pag 32
5.3.1. First approach: GLM for repeated measures.....	Pag 32
5.3.2. Second approach: ANCOVA on the DP of volume ...	Pag 32
5.3.3. Pattern of volume changes (CH).....	Pag 32
6. DISCUSSION	Pag 34
7. REFERENCES	Pag 37

1. BACKGROUND OF THE STUDY

1.1 Psychosis and brain imaging

Since the demonstration of the ventricles enlargement in the 1970s with a CT study on schizophrenia patients (Johnstone et al., 1976; Weinberger et al., 1978), the rapid development of modern imaging technology, going from computed tomography and positron and single photon emission tomography to magnetic and functional magnetic resonance imaging has allowed a wide spread of studies on the neurobiology of psychosis.

In particular, the magnetic resonance imaging (MRI) which permits a fine distinction of brain soft-tissue (grey matter, white matter and cerebrospinal fluid) has the ability to highlight real-time functional changes, has been widely used in psychiatric research to investigate the anatomical substrate of mental illness.

Two main methods are applied to study MRI structural images: the Region of Interest (ROI) approach and the Voxel Based Morphometry (VBM) (Kubicki et al., 2002; Giuliani et al., 2005).

The ROI approach is a manual method, in which a region of interest is first detected as *of interest* and is then manually traced with specific tracing software. The Voxel Based Morphometry is an automated technique, in which no previous hypothesis on a specific area is needed and a software analyzes the whole brain, voxel by voxel. The ROI method has the strength of having a high anatomical validity, but of being time consuming, not allowing the comparison between many brain areas or large subjects groups. Indeed, the VBM method, provides non-biases (by prior hypothesis or observer-dependent biases) measures of the whole brain, but it requires a spatial normalization of the brain scans on a template and it is therefore less sensitive to shape differences and more susceptible to errors caused by misregistrations, especially for small areas (Malla et al., 2011).

Over the past 3 decades a wide range of structural studies, using both ROI or VBM methods, focused on brain volumetric changes in psychiatric disorders. The most common findings in schizophrenia, and to a certain extent in psychosis in general (Dazzan et al., 2011) beside the

confirmation of ventricular enlargement, were general grey/white matter reductions and regional volume reduction (frontal, temporal and limbic regions) providing a common accepted evidence of subtle abnormalities of cerebral structure in patients with schizophrenia (DeLisi 2008; Fornito et al., 2009; Ellison Wright and Bullmore 2010).

In affective psychosis, the most common findings were also volume reductions in frontal and limbic regions, though the results consistence is less than for schizophrenia (Gur et al., 2007; Ellison Wright and Bullmore, 2010). Even if with some inconsistencies and differences such as the volume of the hippocampus, reduced in schizophrenia but not in bipolar patients, and the volume of the amygdala, enlarged only in bipolar patients (Dazzan et al., 2011), it seems that both disorders show an overlap in brain abnormalities, most of all in the frontal lobes (Nakamura et al., 2007; Yu et al., 2010), suggesting that these disorders may be in a continuum of psychosis (Pantelis et al., 2003; Keshavan et al., 2011; Crespo-Facorro et al., 2009). Furthermore, these same patterns of MRI morphometric abnormalities were found also in first episode psychosis patients before they are diagnosed as schizophrenic or bipolar patients (Pantelis et al., 2003; Nakamura et al., 2007; De Castro-Manglano et al., 2011; Dazzan et al., 2011).

1.2 Schizophrenia: Developmental versus degenerative hypotheses

Schizophrenia is a severe, chronic and disabling mental disorder characterized by thought disorganization, delusions and hallucinations, flattened affect and social withdrawal. It arises in late adolescence or early adulthood and affects 1% of the world population. Because of its large range of symptoms, that affects cognition, emotion and behavior, it is an illness with an heterogeneous course and a high degree of disability (Van Haren et al., 2008).

Although the aetiology of schizophrenia remains still unclear, it is considered to be multifactorial as there are many factors that seems to have a role in its pathogenesis (Lewis et al., 2002): the interaction of genetic risk, pre and peri-natal complications, environmental and social stressors, early in the development, leads to alterations in the brain, making a person more susceptible to developing schizophrenia (Nuechterlein and Dawson 1984; Cannon et al., 2000; Mathalon et al., 2003; Hanson et al., 2005). Neither the genetic nor the environmental factors are considered fully determinant and risk factors later in life may be different for each person: while someone may develop schizophrenia due largely to family environment, another may develop it due to the prevalence of gene factors, and a third may not develop it. Although the exact processes that causes

schizophrenia remains still unclear, there is common agreement about the presence of vulnerability to the illness, as confirmed by studies on high risk subjects (Lawrie et al., 1999, Brewer et al., 2006); therefore, the identification of a set of trait and biological markers of this vulnerability could be of fundamental importance for early clinical interventions.

Structural brain abnormalities in schizophrenia are now widely accepted, but, although these abnormalities are evident, the timing of their occurrence remains unclear.

There are two main hypotheses on the nature of the illness: the neurodevelopmental model (Weinberger et al., 1987; Marenco and Weinberger, 2000) and the neurodegenerative model (Lieberman et al., 1999; Van Haren et al., 2008).

The first postulates that early developmental insults in childhood may induce neural pathological process that leads to schizophrenia symptoms in adolescence or early adulthood. To support this hypothesis, authors (Cannon et al., 2000; Marenco and Weinberger, 2000) refer to the fact that the brain pathological process, caused by both genetic and environmental factors, begins before the brain has reached its anatomical adult state: follow back and cohort studies have demonstrated that *pre-schizophrenic* children have developmental social and cognitive delays, behavioral and intellectual abnormalities (Brewer et al., 2006) and individuals who later developed schizophrenia had higher probability to have experienced pre and peri-natal insults and stressful events (Cannon et al., 2000).

The *neurodegenerative hypothesis* postulates that a degenerative process of the brain tissue goes on after the first psychotic symptoms: it arises from the results of neuroimaging studies reporting progressive brain changes after illness onset and it rises back to the hypothesis of Kraepelin and Bleuler (Bleuler 1950; Kraepelin 1971) that a destruction of brain tissues is associated with psychosis (Lieberman et al., 1999). Supports for this hypothesis came from longitudinal structural studies that showed a progression in time of brain abnormalities detected in cross sectional studies , with worsening associated with length of illness (Cahn et al., 2009b; Pantelis et al., 2005).

To date, there is some agreement in considering these two models as not mutually exclusive: instead of a dichotomy, they should be considered as two stages of a continuous process (Woods 1998; Keshavan 1999). There can be an initial neurodevelopmental impairment that causes vulnerability to the illness and that could be the substrate for a later degenerative process, that goes on with illness chronicity (Pantelis et al 2005; Hulshoff Poll 2008).

1.3 Frontal lobes and schizophrenia

Patients with schizophrenia have symptoms, especially negative symptoms (i.e. flattened affect, lack of speech fluency) and cognitive impairments (i.e., executive, problem solving and decision making impairments, poor insight), that are similar to those observed in patients with damage of the frontal lobes, following injury, tumors or strokes (Bechara 2004; Rolls 2004).

The frontal lobe is the area of the brain located in front of each hemisphere, anterior to the parietal and occipital lobe and superior to the temporal lobe. It is involved in several higher cognitive function like problem solving, planning, reasoning and decision making.

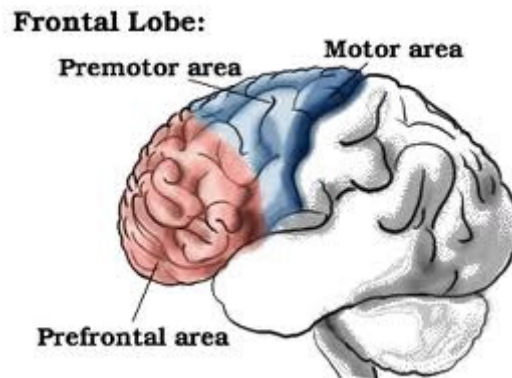


Fig 1: frontal lobe subdivisions.

Each frontal lobe is divided into three parts, the first collocated anteriorly is called prefrontal cortex, the posterior part is composed by the premotor and motor area.

The prefrontal cortex is one of the most complex and evolved part of the human cerebral cortex and it has numerous connections with all other areas of the brain cortex, as well as with limbic and subcortical structures, thus, it has an important modulatory role in human behavior (Shenton et al., 2001) and in complex environmental information processing: it is the main elaboration and executive centre of the brain. Schizophrenia patients have difficulties with the regulation of perception and behavior: both this fact and the observation that cognitive impairments like those present in schizophrenia patients are associated with measures of frontal lobes damages (Andreasen

et al., 1992; Weinberger et al., 1992), lead to the hypothesis that frontal lobes might have a key role in schizophrenia (Weinberger et al 1988; Weinberger et al., 1994; Mc Carley et al., 1999; Shenton et al., 2001) and caused a considerable arising interest in the researchers , making the frontal lobes a focus of structural studies.

The MRI study of the frontal lobes firstly focused on patients with established chronic schizophrenia, while they brought some results, they are susceptible of chronicity biases errors, so researchers began to study also first episode psychosis patients and high risk subjects (Pantelis et al., 2009) in order to better characterize the aetiology of the illness.

Furthermore, since there is evidence of morphological and neurophysiological alterations of the frontal cortex also in affective and in non schizophrenic psychosis (Dazzan et al., 2011) the frontal lobes are thought to have a key role in psychosis.

1.3.1 Cross sectional studies on the frontal lobes

Systematic reviews on ROI studies (Wright et al., 2000; Shenton et al., 2001; Pantelis et al., 2005; Crespo-Facorro et al., 2007) reported evidence for volume alterations, mainly reductions, in the temporal and frontal regions.

On the VBM studies, 6 recent meta-analyses (summarized in tab 1) were conducted on schizophrenia patients at different stages of the illness. Honea (Honea et al., 2005), Glahn (Glahn et al., 2008) and Fornito (Fornito et al., 2009) have analyzed respectively 15, 31 and 37 papers on chronic patients. Ellison-Wright (Ellison-Wright et al., 2008) and Cahn (Cahn et al., 2009) analyzed both first episode (respectively 9 and 14 papers) and chronic patients (respectively 29 and 19 papers). Jockschat et al. (2011) included 38 studies in a meta-analysis but only in 26 the duration of illness was reported.

	Studies	Subjects	Illness stage	Volume Main findings
Honea et al., (2005)	15	390 PT 364 HC	Ch and Fe	Reductions temporal and frontal lobes
Ellison Wright et al., (2008)	27	224 Fe 1332 Ch	Ch and Fe	Reductions Frontal lobes in FE, frontal

		1541 HC		and temporal in Ch
Glahn et al., (2008)	31	1195 PT 1292 HC	Only Ch	Volumes reduction in frontal lobes
Cahn et al., (2009)	41	446 Fe 601 Hr 808 Ch	Hr, Fe and Ch	Fronto temporal reductions in Fe, temporal reductions in Ch, frontal reductions in Hr
Fornito et al., (2009)	37	1646 PT 1690 HC	Only Ch	Volume reductions in temporal and frontal lobes
Jockschat et al., (2011)	83	1736 PT 1915 HC	Not reported	Volume reductions in temporal frontal and thalamic regions

Tab 1. Meta-analyses of VBM studies on schizophrenia. PT: patients, Hr: high risk, Ch: chronic, Fe: first episode, HC: healthy controls.

The most consistent findings across these meta-analysis are clusters of grey matter reductions in the frontal, temporal, limbic, striatal and thalamic regions of schizophrenia patients: these alterations become more extensive with the chronicity of the illness.

Smieskova et al. (2011) analysed 21 studies on high risk subjects with subsequent transition to psychosis and found clusters of volume reductions in prefrontal and medial temporal regions.

Finally, two meta-analysis have compared VBM data on schizophrenia patients with data on bipolar disorder patients (Ellison-Wright and Bullmore, 2010; Yu et al., 2010): both studies found volume reductions in frontal and temporal regions in schizophrenia patients. Interestingly, the regions found to be reduced in bipolar patients overlapped with those of schizophrenia patients, even if bipolar patients have less marked reductions and showed specific decrease in paralimbic regions that are involved in emotional processing.

Meta-analyses had some limitations: individual studies incorporated use different sample size, sample characteristics, brain measurement and statistical methods; furthermore, the standardized and most often used ALE method does not accommodate covariates in the analysis, so confounding factors can influence the results.

1.3.2 Longitudinal studies on the frontal lobes

A longitudinal study is defined as a research study that consists in repeated observations or measurements of the same variables over stabilized periods of time: usually it consists in making a first valuation at a first time point (T1) and in repeating this measurement after a certain period of follow up (T2).

In order to clarify the issue about the timing of the structural abnormalities and to investigate if they are permanent and static or progressive during the course of the illness, several longitudinal studies have been conducted at different stages of the illness so far.

Longitudinal studies on subjects with a high risk to develop schizophrenia and on first-episode (FE) patients have demonstrated that the brain abnormalities described in cross-sectional studies may be progressive over time, starting from the earliest prodromal phases of the illness till the chronic phase (Cahn et al., 2009b; Pantelis et al., 2005). The majority of the longitudinal studies on schizophrenia focused the investigation on the first 5 years of illness and the few studies (Pantelis et al 2005; Hulshoff Poll 2008) conducted on chronic patients reported some evidence that the brain changes occurring during the early stages of schizophrenia are progressing also in the chronic patients, suggesting that the brain changes may be progressive also beyond the first psychotic episode.

Furthermore, these progressive brain changes in chronic patients were found to correlate with a worse clinical outcome, but not with specific clinical variables, i.e number of hospitalizations or psychotic relapses during the two scans interval and they cannot be explained by antipsychotic medication intake: possibly, atypical antipsychotic assumption may even counteract brain volume loss (Hulshoff Pol & Kahn 2008). Progressive brain changes in chronic patients have been demonstrated in the whole brain and are more pronounced in frontal and temporal cortical areas (Ellison-Wright et al., 2008; Fornito et al., 2009; Olabi et al., 2011).

1.4 Orbito-Frontal Cortex

Within the frontal lobes, three main prefrontal cortex regions are involved in the regulation of cognition and emotions in humans, i.e. the anterior cingulate, the dorsolateral prefrontal cortex (DLPFC) and the orbitofrontal cortex (OFC) (Teasdale *et al.*, 1999, Gray *et al.*, 2002).

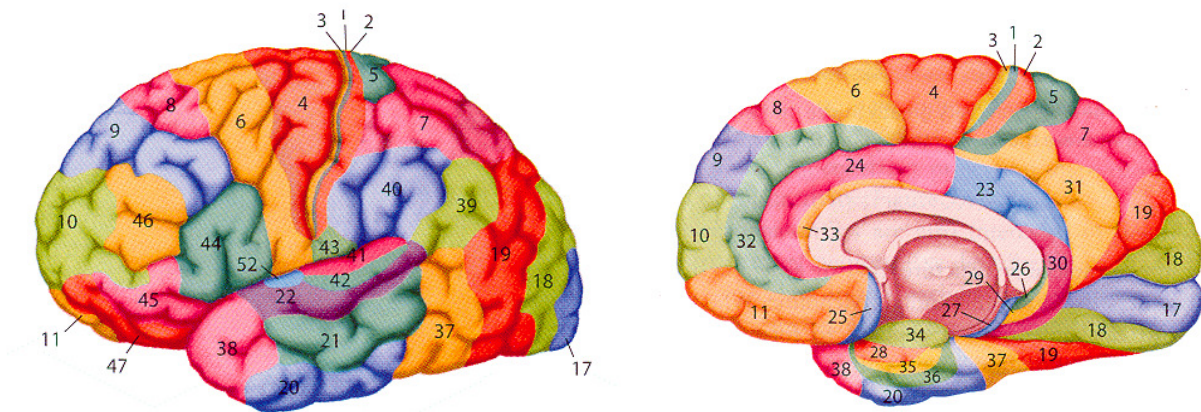


Fig 2: Brodman Areas of the human brain

In particular, the orbitofrontal cortex (OFC) lies above the orbits in the ventral part of the frontal lobe, extending from the anterior perforated substance to the frontal pole (Brodmann Areas 10, 11, 12, 13, 14 and 47). It has been subdivided in a medial part, involved in the processing of negative emotions, and in a lateral part, associated with the integration between positive emotions and cognition (Lacerda *et al.*, 2003). The OFC has extensive connections with several brain areas like the amygdala, hippocampus, thalamus, dorsolateral prefrontal cortex and superior temporal lobe (Lacerda *et al.*, 2007; Ongur & Price, 2000), and is involved in several cognitive processes, such as sensory integration, reward mechanism, decision-making, mood regulation and impulse control (Bechara, 2004; Happaney *et al.*, 2004; Rolls, 2004). Since it's connections with the limbic system, it is thought to have an important role in modulating human behavior through stimulus-reinforcer association learning processes, reward and punishments processing and integration between affective and non affective informations: therefore it has a key role in goal-directed behavior and emotional processing (Kringelbach 2005). Indeed, several functional imaging studies reported OFC activation during reward-guided learning and decision making tasks (Kringelbach and Rolls 2004; Walton *et al.*, 2004; Kringelbach 2005) and in tasks involving emotions.

Damages of the OFC cause cognitive, affective and social impairments, which are similar to the symptoms expressed by patients suffering from schizophrenia (Bechara *et al.* 2004; Lacerda *et al.*, 2007). In this regard, the OFC may play a crucial role for the pathophysiology of the disease.

1.4.1 Cross sectional studies on the OFC

Several (Goldstein *et al.*, 1999; Gur *et al.*, 2000; Wilke *et al.*, 2001; Shapleske *et al.*, 2002; Kawasaki *et al.*, 2004; Riffkin *et al.*, 2005; Tregellas *et al.*, 2007; Schobel *et al.*, 2009; Witthaus *et al.*, 2009; Schultz *et al.*, 2010; Takayanagi *et al.*, 2010; Brown *et al.*, 2011), but not all neuroimaging studies (Baaré *et al.*, 1999; Szeszko *et al.*, 1999; Yamasue *et al.*, 2004; Rupp *et al.*, 2005; Lacerda *et al.*, 2007) have reported volume reductions of the OFC in schizophrenia, using both manual or automated techniques (tab. 2). Interestingly, OFC volumes have also been found to positively correlate with severity of negative symptoms (Lacerda *et al.*, 2007), low levels of insight (Shad *et al.*, 2006; Sapara *et al.*, 2007; Bellani & Brambilla, 2008), high levels of aggression and impulsivity (Hoptman *et al.*, 2005; Gansler *et al.*, 2008; Kumari *et al.*, 2009), with poor verbal memory (Matsui *et al.*, 2008) and decision making performances (Nakamura *et al.*, 2008; Bellani *et al.*, 2009). Furthermore, reduced OFC volumes, particularly the middle orbital gyrus, associated with greater formal thought disorder and with a longer duration of the illness (Nakamura *et al.*, 2008).

Therefore, although with some inconsistencies, there is evidence that OFC volumes are reduced in schizophrenia, at least in chronic patients, and that they may be associated with psychopathology and impaired cognition. However, it is still not clear whether OFC deficits are present before the onset of the disease or whether they occur with the progression of the illness.

The description above has been published in: Bellani M, Cerruti S, Brambilla P. Orbitofrontal cortex abnormalities in schizophrenia. *Epidemiologia e Psichiatria Sociale*, 2010, 19:23-5.

Study	Subjects	Age (years)	Duration of illness (mean)	Tesla, Slice Thickness, Tracing method	OFC volumes in schizophrenia
Baaré <i>et al.</i> , (1999)	14 patients 14 controls	28.5 ± 5.7 26.9 ± 5.9	80.3 months	0.5 T, 1.2 mm VOI	Preserved
Goldstein <i>et al.</i> , (1999)	29 patients 26 controls	44.8 ± 10.5 39.8 ± 11.5	22 ± 9.9 years	1.5 T, 3.1 mm Parcellation method	↓ Right OFC GM
Szeszko <i>et al.</i> , (1999)	10 patients 16 controls	23.6 ± 3.7 28.6 ± 6.9	First episode	1 T, 1.17 mm ROI	Preserved
Gur <i>et al.</i> , (2000)	70 patients 81 controls	28.7 ± 6.9 26.4 ± 6.7	6 ± 6.4 years	1.5 T, 1.0 mm Parcellation method	↓ OFC GM in female patients
Wilke <i>et al.</i> , (2001)	48 patients 48 controls	33 ± 9.1 33 ± 9.8	8.5 ± 8.4 years	1.5 T, 0.9-1.4 mm VBM	↓ OFC GM
Shapleske <i>et al.</i> , (2002)	72 patients 32 controls	34.1 ± 8.5 33.3 ± 8.7	138.1 ± 94 months	1.5 T, 3 mm VBM	↓ OFC GM
Kawasaki <i>et al.</i> , (2004)	25 patients 50 controls	25.8 ± 4.5 24 ± 5.7	3.1 ± 3.1 years	1.5 T, 1.0 mm VBM	↓ OFC GM
Yamasue <i>et al.</i> , (2004)	27 patients 27 controls	30.4 ± 7.9 30 ± 5.6	9.8 ± 7.2 years	1.5 T, 3 mm Parcellation method	Preserved
Riffkin <i>et al.</i> , (2005)	18 patients 18 controls	35.9 ± 12 34.5 ± 11.8	< 2 years	1.5 T, 1.5 mm VBM, ROI	↓ OFC GM
Rupp <i>et al.</i> , (2005)	33 patients 40 controls	25.4 ± 4.7 26.2 ± 4.7	4 years	1.5 T, 1 – 1.2 mm Parcellation method	Preserved
Shad <i>et al.</i> , (2006)	14 patients 21 controls	26.2 ± 7.5 24.3 ± 5.7	104 ± 126 weeks	1.5 T, 1.5 mm ROI	Preserved

Lacerda <i>et al.</i> , (2007)	43 patients 53 controls	24.5 ± 6 25.3 ± 7.3	First episode	1.5 T, 1.5 mm ROI	↑ left OFC GM
Sapara <i>et al.</i> , (2007)	28 patients 20 controls	39 ± 10.6 35.9 ± 13.7	13.7 ± 10 years	1.5 T, 5 mm ROI	Preserved
Tregellas <i>et al.</i> , (2007)	32 patients 32 controls	39.6 ± 8.8 35.3 ± 9.3	Not reported	1.5 T, 1.5 mm VBM	↓ OFC GM
Schobel <i>et al.</i> , (2009)	38 patients 29 controls	32.3 ± 10.6 31.3 ± 9.2	10.8 ± 9.2 years	1.5 T, 1.5 mm ROI	↓ Left OFC
Witthaus <i>et al.</i> , (2009)	23 patients 29 controls	26.4 ± 6.1 25.7 ± 5.2	First Episode	1.5 T 1 mm VBM	↓ Left OFC
Schultz <i>et al.</i> , (2010)	54 patients 54 controls	26.4 ± 7.7 26.6 ± 6.3	First Episode	1.5 T 1 mm Parcellation method	↓ OFC GM
Takayanagi <i>et al.</i> , (2010)	42 patients 35 controls	29.15 ± 5.8 29.55 ± 5	12.7 ± 12.5 months	1.5 T, 1 mm ROI	↓ OFC
Brown <i>et al.</i> , (2011)	17 patients 21 controls	44.8 ± 6.8 45 ± 10.2	19.1 ± 6.2 years	1.5 T 1 mm VBM	↓ OFC GM

Tab.2 Mm= Millimeters; OFC= Orbitofrontal Cortex; ROI= Region of Interest; T= Tesla; VBM= Voxel Based Morphometry; VOI= Volume of Interest, GM= Gray Matter.

1.4.2 Longitudinal studies on the OFC

There is a lack of longitudinal volumetric studies on OFC and the fews confirmed the hypothesis that structural brain changes in schizophrenia may be progressive. In two studies (Pantelis at al., 2003; Borgwardt et al., 2008) high risk individuals underwent a first scan at baseline and a second one after 3 years, in the second scan a reduction of the OFC volume was found, but only in those subjects who developed psychosis during the follow up period. The authors argued their results with the hypothesis that even if some brain abnormalities are associated with vulnerability to psychosis, some other may emerge as psychosis develops and worsen in time.

In another study on young relatives at risk for schizophrenia, OFC was found to be reduced in respect to healthy controls at baseline and to further decline after 1 year (Bohraj et al., 2011).

Three studies (Kasperek et al., 2009; Asami et al., 2011; Castro-Manglano et al., 2011) found smaller OFC volumes in first-episode schizophrenia patients after a follow-up period of 1, 1.5, and 3 years respectively, and Mané (2009) reported wider gray matter reduction in the right orbitofrontal gyrus in first-episode patients in respect of healthy controls, after a follow-up period of four years. Finally, Van Haren (2011) found OFC reduction after 5 year in chronic patients.

The few existent studies on the OFC seem to confirm the hypothesis that structural brain changes in this region in schizophrenia may be progressive, but further longitudinal studies are expected to investigate OFC volumes in subjects with an at-risk mental state for psychosis or in first-episode patients.

2. AIM OF THE STUDY

Based on the considerations of the previous paragraph, in this study we aimed to compare possible longitudinal volume changes of the OFC in first episode and chronic schizophrenia patients. Also, we analyzed OFC sub-regions separately, based on the functional and anatomical characteristics of the OFC in humans, and we segmented each subregion in white and grey matter, to analyze them separately and to explore whether they associate with particular psychopathological dimensions (negative versus positive symptoms) or outcome measures.

Aims of this study were :

- to measure the volumes of the OFC and its subregions, as traced on MRI scans, in a group of First Episode Psychosis patients (FEP), a group of chronic schizophrenia patients (SCZ) and a in group of healthy controls (HC);
- to investigate the volume differences in these 3 groups at baseline;
- to investigate the changes in OFC volumes over time in this dataset;
- to correlate OFC volume changes over time with psychopathology, outcome, insight.

We expected FEP and Schizophrenia patients to have different OFC volumes in comparison to HC. Moreover, we expected that these differences would be more evident over time.

3. METHODS

3.1 Sample recruitment

This study was conducted on 3 groups of subjects: chronic schizophrenia patients, first episode psychosis (FEP) patients and healthy controls. All participants provided signed informed consent, after having understood the nature and purpose of the study.

Chronic schizophrenia group: 71 patients with a DSM-IV diagnosis of schizophrenia aged between 18 and 65 years, were recruited from the geographically defined catchment area of South-Verona (Italy) through the South Verona Psychiatric Case Register (Amaddeo *et al.*, 2009; Amaddeo & Tansella, 2009) and underwent a Magnetic Resonance Scan at baseline and another one at follow up. Exclusion criteria were the presence of comorbidity of axis I disorders, mental retardation, organic mental disorder (epilepsy, dementia, cerebro-vascular or infective illness, head injury or brain tumors), organic medical illness and alcohol and substance abuse.

This study is part of a wider research project (FIRST, “*Following imaging resilience features in schizophrenia and affective disorder*”) that was approved by the Ethics Committee of the Azienda Ospedaliera Universitaria Integrata of Verona.

First episode psychosis group: 83 First Episode patients were recruited for MRI, in the context of the Psychosis Incident Cohort Outcome Study (PICOS). The PICOS study is a large multisite research (coordinated by Prof. Mirella Ruggeri) taking place in the Veneto Region of Italy, with the aim to evaluate the role of clinical, social, genetic and cerebral morphological factors in predicting the outcome of the psychotic episodes. Overall, 25 routine public community-based mental health services took part in the PICOS: they were asked to refer all potential cases of psychotic patients at first service contact to the study’s research staff, during the index period.

The research project was composed by three research modules:

Module 1 - Clinical and epidemiological evaluations (Head, Dott. Antonio Lasalvia)

This module takes into account the evaluation of clinical and social variables of patients affected by a psychotic disease with the aim of characterizing the onset of the illness and following the medial

and long term outcome. Study variables are: life events, premorbid adjustment, premorbid IQ, parental bonding, psychopathology (positive/negative and depressive/manic symptoms), global functioning, social disability, insight level, “neurological soft signs”, quality of life, mental health services satisfaction, collateral drug effects and needs for care.

Module 2 – Genetics (Head Dott.ssa Sarah Tosato)

It is based on the analysis of the familiarity of psychotic disorders and of the genetic predisposition to psychosis. It includes the reconstruction of probands’ Family Tree for psychosis and techniques of molecular genetics. Blood samples from patients and their first degree relatives were collected for DNA analyses, which will be focused on putative susceptibility genes for psychoses: Neuregolin 1, PRODH2, Brain-derived Neurotrophic Factor (BDNF), Disrupted in Schizophrenia 1 (DISC 1).

Module 3 - Brain imaging (Head Dott. Paolo Brambilla)

It includes the study of brain anatomy through the evaluation of structural/ functional brain abnormalities by MRI scans; a series of neuropsychological tests has been also performed, by the Brain Imaging Unit of the University of Verona, in order to find possible correlations between brain abnormalities and specific brain functions. MRI scans are performed at baseline and at 1 year. MRI and test procedure are described in detail in the next paragraphs.

Patients with a first episode of psychosis were recruited at their first contact with the psychiatric services of the Veneto region during a period of 24 months: within 30 days by their first contact, patients were administered the “WHO Screening Schedule for Psychosis” (Jablensky et al, 1992), a screening test for the identification of possible cases to be included.

Inclusions criteria were:

1. Age 18-54
2. Presentation of at least one severe positive symptom or two severe negative symptoms
3. First absolute contact with the psychiatric service for the symptoms of the previous point
4. If treated for the symptoms on point 2, treatment duration must be less than 3 months
5. Absence of organic mental disorder (epilepsy, mental retardation, dementia, cerebrovascular or infective illness, head injury or brain tumors)

6. With respect to the research exclusion criteria adopted by Module 1, further criterion was applied in Module 3: alcohol or substance abuse in the six months preceding MRI.

For both schizophrenia patients and FEP psychosis patients the diagnosis was confirmed by the IGC-SCAN (*Item Group Checklist of the Schedule for Clinical Assessment in Neuropsychiatry*, World Health Organization, 1992).

Healthy Controls Group: Ninety-two healthy controls without DSM-IV axis I disorders and with an age comprised between 18 and 65 years were also recruited. SCID-IV *non patient version*, GAF were assessed. Exclusion criteria were the presence of mental retardation, organic mental or psychiatric disorder (epilepsy, dementia, cerebro-vascular or infective illness, head injury or brain tumors), organic medical illness and alcohol and substance abuse.

As regards the SCZ and FEP patients group, a clinical assessment was administered by a trained research clinical psychologist. It is composed by rating scales measuring three main dimensions:

- 1) global functioning and quality of life [Global Assessment of Functioning (GAF), Strauss and Carpenter Outcome Scale, World Health Organization-Disability Assessment Schedule (WHO-DAS), Manchester Short Assessment of Quality of Life (MANSA), Short Form Health Survey 36 (SF-36), EuroQol (EQ-5D)];
- 2) drug attitude [Morisky Scale; Drug Attitude Inventory (DAI)]
- 3) insight/psychopathology [Schedule for the Assessment of Insight (SAI-E), Brief Psychiatric Rating Scale (BPRS, 24-item version), Hamilton Depression Rating Scale (HDRS), Bech-Rafaelsen Mania Rating Scale (BRMRS)].

Other socio-demographic data such as age of onset (operationally defined as the time patient had his first contact with psychiatric services), duration of illness, number of hospitalizations, handedness and psychopharmacological lifetime treatment were collected from patients' interviews and medical records.

Moreover, both patients and healthy subjects were assessed with a full neuropsychological assessment exploring the domains of language, executive functions, general cognitive functioning, inter-hemispheric communication. Hand dominance was measured using the **Edinburgh Handedness Inventory**, a questionnaire asking subjects to indicate the hand used in performing 10 activities (writing, drawing, throwing, using scissors, using a toothbrush, using a knife without a

fork, using a spoon, the upper hand when using a broom, striking a match, and opening the lid of a box). The strength of this preference was also investigated.

In the present study, the following instrument have been utilized in the analyses, and thus described in details in the following paragraphs:

The **Global Assessment of Functioning (GAF)** is a numeric scale (from 0 to 100), part of the DSM-IV-R, Axis V, which considers psychological, social, and occupational functioning of the subject on a hypothetical continuum of mental health-illness. It does not include impairment in functioning due to physical (or environmental) limitations. The GAF has 10 anchor points, which can be further divided into 10 points by providing a continuum from "complete mental health" (100) to "risk of death" (1): 81 to 100 = absence of psychopathology, 71 to 80 = marginal psychopathology, psychopathology = 1 to 70 of different severity. The GAF is useful in studies requiring the assessment of well-being or for measuring the degree of improvement.

Post processing analyses were conducted only on the scans of subject who had both baseline and follow up scans: 27 schizophrenia patients, 22 healthy controls and 39 first episode patients.

The OFC was traced on MRI images of 27 schizophrenia patients, 22 healthy controls and 21 FEP patients: one schizophrenia patient, one healthy control and 5 FEP were excluded for technical problems.

The final sample consisted of 16 FEP patients, 26 schizophrenia and 21 healthy controls.

3.2 MRI acquisition and image processing

The MRI sessions were conducted at the Section of Radiology (prof. Pozzi Mucelli and Dr Cerini) of the Verona Hospital (Policlinico G.B. Rossi) and MRI scans were acquired with a 1.5T Siemens Magnetom Symphony Maestro Class scanner (Syngo MR, 2002B). A standard head coil were used for RF transmission and reception of the MR signal; restraining foam pads were used to minimize head motion. T1-weighted images were first obtained to verify each subject's head position and the image quality (TR=450 ms, TE=14 ms, flip angle=90°, FOV=230x230 mm, 18 slices, slice thickness=5 mm, matrix size=384x512, NEX=2). PD/T2-weighted images were then acquired (TR=2500 ms, TE=24/121 ms, flip angle=180°, FOV=230x230 mm, 20 slices, slice thickness=5

mm, matrix size=410x512, NEX=2), according to an axial plane parallel to the anterior-posterior commissures (AC-PC), to exclude focal lesions. Subsequently, a coronal 3D MP-RAGE sequence were acquired (TR=2060 ms, TE=3.9 ms, flip angle=15°, FOV=176x235 mm, slice thickness=1.25 mm, matrix size=270x512, TI=1100) to obtain 144 images covering the entire brain. All imaging data were transferred to a PC workstation and analyzed using the BRAINS2 software developed at the University of Iowa (<http://www.psychiatry.uiowa.edu/mhcr/ IPLpages/ BRAINS .htm>).

ROI tracing

The OFC was manually traced in the coronal plane, using a standardized geometrical method developed by Lacerda and colleagues (Lacerda et al., 2003; Lacerda et al., 2004). The first slice was the one at the rostrum of the Corpus Callosum and the last slice to be traced was the most anterior slice where the brain tissue could be identified.

In all slices, the lateral boundaries were represented by a point placed on the intersection between the tangents to the lateral and the inferior limits of the frontal lobes. The superior limit, in the subgenual region, was the inferior border of the Anterior Cingulate and a point placed 5 slice higher to this inferior border, in the region in front of the genu of the Corpus Callosum. In each slice, lines were drawn to connect the superior boundary point with the intersections points of the inferior and lateral tangents of the frontal lobes. The lateral borders of the triangle so obtained were the lateral boundaries of the tracings. The inferior border was then edit and re-traced following the inferior surface of the frontal lobes (Fig 3).

This total trace (OFC) was then divided in a right and a left part (R_OFC and L_OFC), following the interhemispheric sulcus (Fig 4), and each right and left part was further on divided into a medial and a lateral part (R_Lat_OFC, L_Lat_OFC, R_med_OFC and L_med_OFC) following the olfactory sulcus (Fig. 5).

The software BRAINS2 automatically calculates the volumes and creates a 3D reconstruction of the traced area (Fig 6).

The inter-rater reliability, defined by ten randomly selected scans traced by two blind raters, was $r=0.91$ for the entire OFC, $r=0.92$ for the right-left division, 0.92 for the right lateral-medial division and 0.91 for the left lateral-medial division.

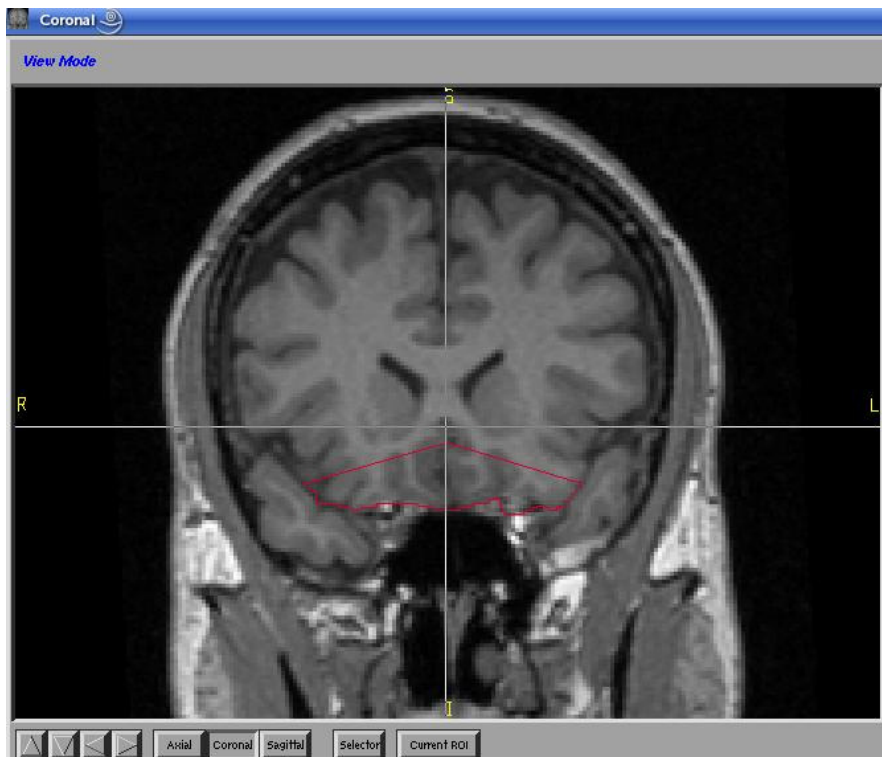


Fig 3: OFC tracing

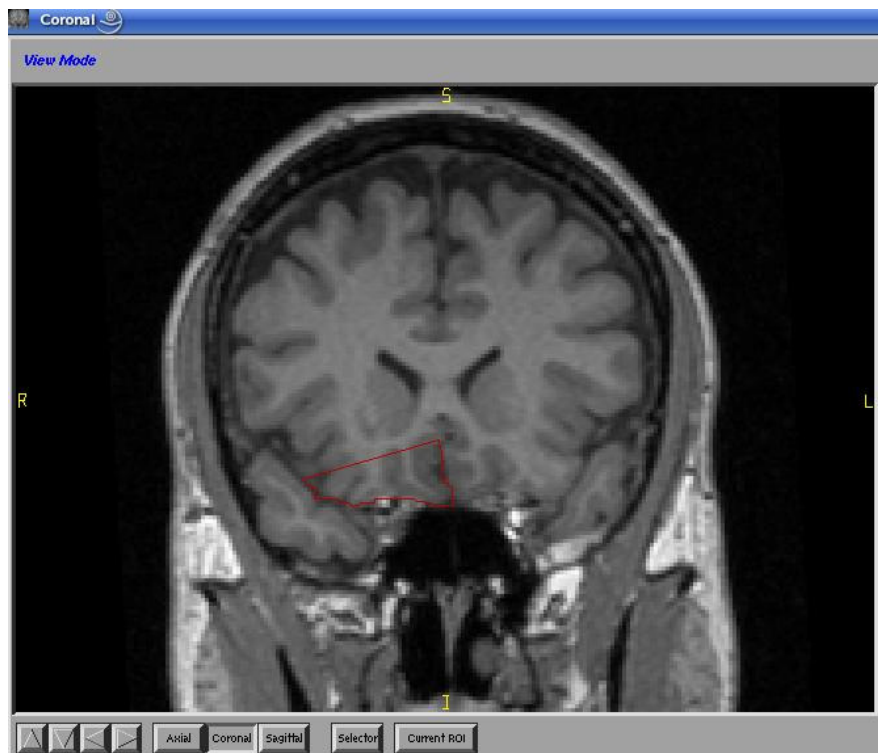


Fig 4: Right/Left subdivision of the OFC

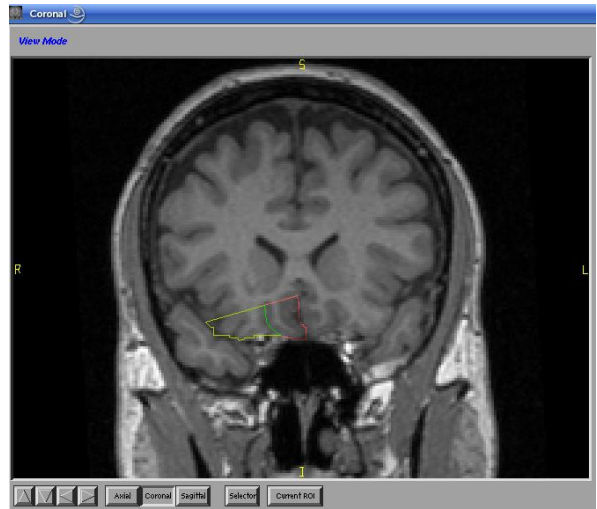
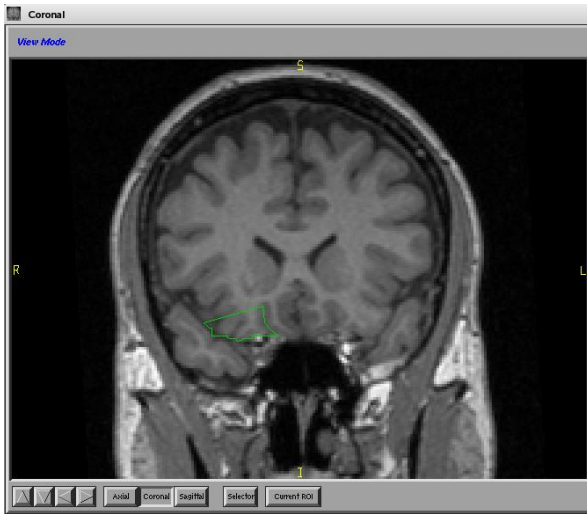


Fig 5: Lateral and medial subdivisions of the OFC

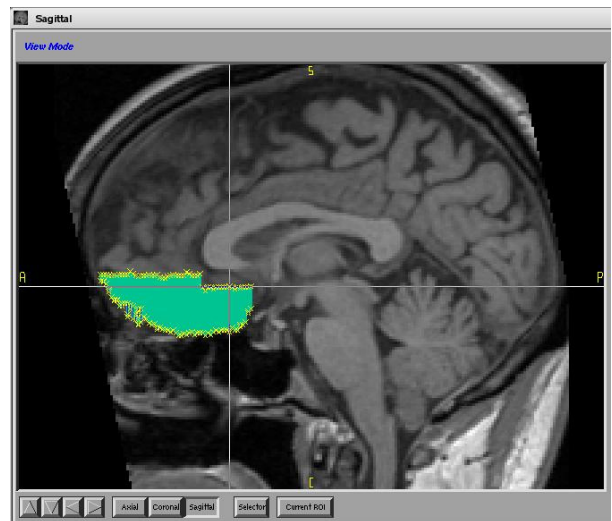
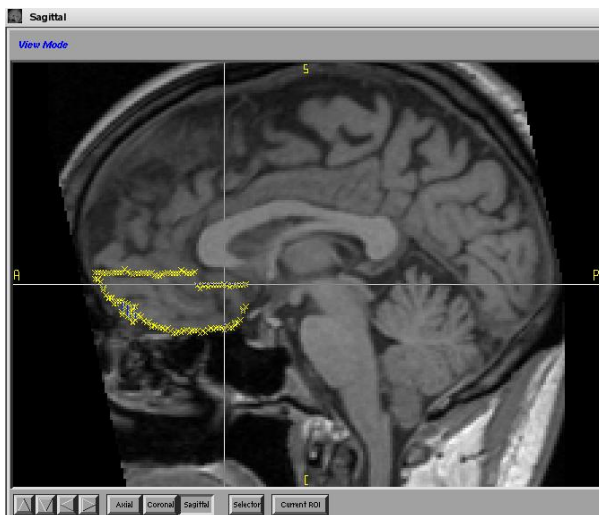

Fig 6: OFC volume

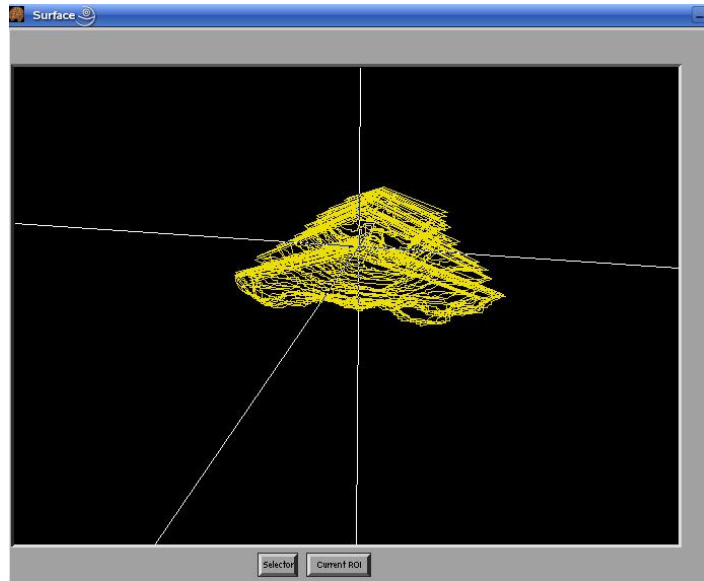


Fig 7: 3D reconstruction of the OFC

4. STATISTICAL ANALYSIS

4.1 Socio demographical characteristics

We performed ANOVA (or Chi-squares test) to analyze socio-demographic, clinical and ICV volumes differences between groups.

4.2 Cross sectional analyses baseline and follow up

ANCOVA with age, gender and ICV as covariates and Bonferroni post hoc correction were performed to compare the volumes of OFC and its sub-regions, both at baseline and follow-up (group as between-subject factor).

We also calculated Pearson's correlations between OFC volumes and clinical variables at both baseline and follow up (p value set at 0.005).

4.3 Longitudinal analyses

To compare the longitudinal OFC volume changes in the three groups, we firstly performed a GLM for repeated measures (age, gender and ICV as covariates) with time (baseline-follow up), hemisphere (left-right) and region (total-white matter-grey matter) as within-subjects factors and group (FEP-SCZ-HC) as between-subjects factor.

Secondly, we adopted another approach to longitudinal data by calculating the percent difference (DP) of volume changes between baseline and follow up scans $[(\text{volume at second scan} - \text{volume at first scan}) / \text{volume at first scan} * 100]$ and then we performed an ANCOVA analysis on these data, using age, gender and ICV as covariates.

Furthermore, in order to take into account the difficult to understand the phenomenon of changes of volumes by means of DP calculation (changes are positive and negative, so the mean values are nearly zero) longitudinal changes were calculated as percentages of subjects, within each group, who showed an increase in the volumes between baseline and follow-up ($DP < -0.99$) or a decrease ($DP > +0.99$) or a stability ($-0.99 < DP < +0.99$). The choice of a value of 0.99 was established on the basis of the review of Hedman (Hedman et al., 2011) in which the authors found a decrease of brain volume in healthy subjects of 0.2% pro year. Therefore we considered as normal a volume loss of 1% in three years (our mean inter-scan interval). The pattern of increase/decrease/stability (CH: changes) in the three types of subjects (HC, FEP, SCZ) was evaluated by Chi-square test.

All analyses were conducted using SPSS 17.0 for Windows (SPSS Inc., Chicago). All tests were two-tailed and the statistical significance level was set at $p < 0.05$.

5. RESULTS

5.1 Sample characteristics

There were no differences in age, gender, education and ICV between groups. Socio-demographic and clinical variables of the sample, are summarized in tab.3 (baseline) and in tab.4 (follow up).

	HC (N=21)	FEP (N=16)	SCZ (N=26)	Statistics
Gender (F/M)	10/11	9/7	7/20	X = 4.46 p = 0.11
Age	39.29±11.91	35.50±11.48	39.11±11.96	F = 0.58 p = 0.56
Education (low/high)	28.6/71.4%	18.8/81.3%	63/37%	X = 10.02 p = 0.07
Age at onset	-	34.77±10.44	25.07±9.81	F = 9.52 p = 0.004
Illness duration (months)	-	2.38±1.5	168.78±151.64	t = 19.32 p = 0.000
Number of hospitalizations	-	0.67±0.62	5.46±8.9	F = 4.32 p = 0.044
GAF score	79.35±4.31	58.08±18.2	50.96±15.05	F = 25.6 p = 0.00
Anxiety/depression (BPRS)	-	10.93±5.32	11.58±5.25	t = 0.14 p = 0.73
Negative symptoms (BPRS)	-	8.33±1.91	11.37±3.82	t = 8.17 p = 0.007
Positive symptoms (BPRS)	-	6.87±2.47	10.77±5.74	t = 4.98 p = 0.03
Mania (BPRS)	-	9.87±1.46	12.87±5.15	t = 4.82 p = 0.03
BPRS total score	-	32.8±7.67	41.21±15.29	t = 4.88 p = 0.03
ICV	1476±143	1431±141	1464±149	F = 0.50 p = 0.60

Tab 3 Socio-demographic and clinical characteristics of the sample at baseline.

	HC (N=21)	FEP (N=16)	SCZ (N=26)	Statistics
Gender (F/M)	10/11	9/7	7/20	X = 4.46 p= 0.11
age	42.38±12.36	37.19±11.39	42.27±12.3	F = 1.07 p= 0.34
Illness duration (months)	-	23.50±7.64	204.5±160	t = 20.23 p= 0.00
Number of hospitalizations	-	0.8±0.78	6±8.9	t = 5.04 p= 0.03
GAF score	82.57±6.05	59.5±16.03	48.12±13.64	F = 44.89 p= 0.00
Anxiety/depression (BPRS)	-	8.27±1.83	10±3.69	t = 2.84 p= 0.10
Negative symptoms (BPRS)	-	8±1.19	9.64±2.78	t = 4.66 p= 0.04
Positive symptoms (BPRS)	-	6.53±2.19	8.04±3.34	t = 2.4 p= 0.13
Mania (BPRS)	-	10±2.07	11.72±2.98	t = 3.86 p= 0.06
BPRS total score	-	29.6±5.38	35.54±8.75	t = 5.56 p= 0.02
ICV	1474±135	1412±136	1471±151	F = 1.07 p = 0.35
Interscan Interval (months)	36.71±8.03	21.13±7.5	32.92±17.50	t = 7.16 p= 0.02

Tab 4 Socio-demographic and clinical characteristics of the sample at follow up,

5.2 Cross sectional analyses

5.2.1 ANCOVA - volumes at baseline

At baseline, ANCOVA showed a difference between groups in the OFC grey matter volumes, both in right and left side (see tab. 5).

Post hoc test revealed that SCZ had bigger volumes than FEP and HC in the above mentioned regions (OFC grey matter: $p=0.026$; right OFC grey matter: $p=0.013$; left lateral OFC grey matter: $p=0.045$).

	HC (N=21)	FEP (N=16)	SCZ (N=26)	Statistics	
OFC grey matter	9.53±1.64	9.83±1.80	10.75±2.11	F=3.71	$p=0.030$
Right OFC grey matter	4.90±0.82	4.95±0.96	5.53±0.99	F= 4.48	$p= 0.015$
Left lateral OFC grey matter	1.75±0.44	1.76±0.32	2.09±0.56	F= 3.36	$p= 0.042$

Tab. 5 ANCOVA baseline. Only significant results are reported.

5.2.2. ANCOVA - volumes at follow up

At follow up, the left lateral OFC volume (total and both white and grey matter) differed between groups (see tab 6).

Post hoc test showed that SCZ had bigger volumes than FEP and HC in these regions (left lateral OFC: $p=0.007$; gray matter lateral OFC: $p= 0.019$; white matter lateral OFC: $p=0.003$).

	HC (N=21)	FEP (N=16)	SCZ (N=26)	Statistics	
Left lateral OFC	4.87±1.11	5.05±1.28	6.16±1.78	F= 5.24	p= 0.008
Left lateral white matter OFC	2.39±0.52	2.48±0.63	2.93±0.90	F= 6.08	p= 0.004
Left lateral grey matter OFC	1.68±0.40	1.69±0.45	2.06±0.58	F= 4.28	p= 0.018

Tab. 6 ANCOVA follow up. Only significant results are reported.

5.2.3. Pearson's Correlations

We found positive correlations, in the FEP group, between the OFC volume and negative symptoms on the BPRS at baseline (table 7a), and between the OFC volume and positive symptoms on the BPRS at follow up (table 7b). In the SCZ and in the HC groups, no significant correlations were found.

	Ofc	Ofc wm	Ofc gm	R ofc	L ofc	L ofc wm	L ofc gm
negative symptoms	r=0.74 p=0.001	r=0.70 p=0.004	r=0.73 p=0.002	r=0.69 p=0.004	r=0.77 p=0.001	r=0.74 p=0.001	r=0.75 p=0.001
	R lat	R lat wm	R lat gm	R med gm	L med	L med wm	L med gm
	r=0.73 p=0.002	r=0.69 p=0.004	r=0.74 p=0.002	r=0.71 p=0.003	r=0.79 p=0.000	r=0.71 p=0.003	r=0.85 p=0.000

Tab 7a. ofc, orbitofrontal cortex; r, right; l, left; wm, white matter; gm, grey matter; med, medial; lat, lateral.

Positive symptoms	L ofc wm	L ofc gm	L lat	L lat wm	L lat gm
	r=0.71 p=0.003	r=0.68 p=0.005	r=0.78 p=0.001	r=0.83 p=0.000	r=0.84 p=0.000
	R med	R med wm	R med gm	L med wm	L med gm
	r=0.73 p=0.002	r=0.78 p=0.000	r=0.77 p=0.001	r=0.75 p=0.001	r=0.71 p=0.003

Tab 7b. ofc, orbitofrontal cortex; r, right; l, left; wm, white matter; gm, grey matter; med, medial; lat, lateral.

5.3 Longitudinal analyses

5.3.1 First approach: GLM for repeated measures

No significant main effects and *time x group x region* (and/or *hemisphere*) interactions were shown in OFC, medial OFC and lateral OFC volumes (test of within-subjects effects) ($p > 0.05$). Also, no group differences were revealed by test of between subjects effect ($p > 0.05$).

Since cross sectional analyses suggested left lateral OFC to be a region of critical interest, we repeated GLM for this region only. No time effect was found (test of within-subjects effects), but difference between groups (unrelated to time) was confirmed by test of between subjects effect ($F=4.67$; $p=0.013$).

5.3.2 Second approach: ANCOVA on the DP volume

ANCOVA (with age, gender and ICV as covariates) on the volume DP (that is the % of volume difference between baseline and follow up) found a significant difference between groups in the OFC grey matter (see tab 8). Post hoc correction showed that this difference is between FEP and HC ($p=0.029$), with FEP showing a bigger difference in the volume of the OFC grey matter than healthy controls.

	HC (N=21)	FEP (N=16)	SCZ (N=26)	Statistics	
Percent difference OFC grey matter	-1.90±9.25	4.75±8.13	0.30±7.20	F= 3.60	p= 0.034

Tab. 8 ANCOVA on the percentage differences of volume between baseline and follow up

5.3.3 Pattern of volume changes (CH)

We found a significant difference in the pattern of changes over time (increase, decrease and stability) in the three groups in the OFC grey matter (OFC GM) ($\chi^2 = 9.53$; $p = 0.049$).

Specifically, within the FEP group, 12.5% showed increased OFC GM volume, 6.3% a stable volume and 81.3% a decreased volume over time (see tab. 8). Looking at the adjusted residuals, FEP showed a significantly bigger decrease than HC in the volume of OFC GM over time (in bold in tab. 9).

		HC	FEP	SCZ	Total
increase	N	11	2	11	24
	% within group	52,4%	12,5%	42,3%	38,1%
stability	N	3	1	1	5
	% within group	14,3%	6,3%	3,8%	7,9%
decrease	N	7	13	14	34
	% within group	33,3%	81,3%	53,8%	54,0%
Total	N	21	16	26	63
	% within group	100,0%	100,0%	100,0%	100,0%

Tab. 9 Chi Square test on the percentage differences of volume between baseline and follow up in the three groups (OFC grey matter).

6. DISCUSSION

We expected first episode psychosis patients FEP and Schizophrenia to have different (greater) OFC volumes in comparison to HC. Moreover, we expected that these differences would be more evident over time. The finding of larger volumes of the left lateral OFC grey matter in SCZ patients compared to FEP and HC was confirmed at the follow up.

We expected a reduction of the OFC volume in SCZ patients, but we found an increased volume in SCZ patients compared to FEP and HC in the left part of the OFC, both in white and grey matter.

Only two studies reported similar increase results: Tanskanen (Tanskanen et al., 2008) found an excess of grey matter density in the medial OFC of SCZ patients and Lacerda (Lacerda et al., 2007) found an increase in the volume of the left part of the OFC grey matter but in FEP patients, not in chronic SCZ patients.

Interestingly, other studies had found alterations, rather reduction than increase, in the volume of the left part of the OFC: indeed Pantelis (Pantelis et al., 2003) found a reduction of the left OFC in high risk subjects who subsequently developed psychosis; Crespo-Facorro (Crespo-Facorro et al., 2000) found a deficit in the cortical surface size of the left OFC, Venkatasubramanian (Venkatasubramanian et al., 2008) reported a bilateral, lateral orbitofrontal cortices deficit in antipsychotic naïve schizophrenia patients; Kaspareck found a bilateral grey matter reduction of the lateral OFC in first episode schizophrenia patients (Kaspareck et al., 2009) and Takayanagi found a bilateral grey matter reduction of the orbital gyrus (Takayanagi et al., 2010).

Therefore, the left part of the OFC seems to be a brain region particularly affected by volume abnormalities in psychosis.

As regards the findings of an increase of white matter in the left part of the OFC of the SCZ patients, to our knowledge, there are only two studies that found the OFC white matter to be implicated in schizophrenia patients: Riffkin (Riffkin et al., 2005) found a reduction of the volume of the OFC white matter, but only in the right part, and Hoptmann (Hoptmann et al., 2002) found this region to correlate with impulsivity and aggression. If we take into consideration the entire frontal lobe, Paillère-Martinot (Paillère-Martinot et al., 2001) found a bilateral white matter reduction in the frontal lobes of early onset schizophrenia patients.

Although alterations (but reductions) of the OFC grey matter in chronic SCZ is a result often confirmed in literature (Bellani et al., 2010), volume alterations in the white matter of this region

were less mentioned in literature. This lack of findings on white matter of the OFC, and of the brain in general, is possibly due to the fact that firstly, often volume alterations are mentioned without a specific distinction of white and grey matter, (many ROI volumetric studies have not specified if the volume they measured was segmented into white and grey matter) and secondarily, the majority of volumetric studies have been focused only on grey matter (Ellison Wright and Bullmore 2011), the interest for the white matter volume and integrity of frontal regions in schizophrenia is newer than those for grey matter (Walterfang et al., 2011). Instead, for connectivity studies which apply the DTI method, a common evidence is a reduced connectivity (lower FA) in the infero-frontal occipital fasciculus (White et al., 2008), which is included in our trace of the OFC.

We expected an association between the volume of the OFC and psychopathology: we found an enlargement of the OFC at baseline to be positively correlate with severity of negative symptoms, and the OFC at follow up with positive symptoms. To our knowledge this is a result present in only two studies: Lacerda (Lacerda et al., 2007) reported a OFC volume increase related to severity of negative symptoms in first episode schizophrenia patients and Nesvag (Nesvag et al., 2009) found the same correlation in chronic schizophrenia patients. Instead, two studies found negative symptoms to be related to reductions of the OFC in schizophrenia patients: Gur (Gur et al., 2000) and Baarè (Baarè et al., 1999). Finally Nakamura (Nakamura et ., 2008) reported an association between the volume of the OFC and worse positive formal thought disorder. To our knowledge, no study to date has established clear association of OFC volume with positive symptoms.

As regards the longitudinal analysis, the OFC grey matter volume of FEP patients had decreased across time more than those of chronic SCZ patients and HC. Although this result is in line with some previous findings reporting longitudinal OFC grey matter volume decrease in FEP patients (Kasperek et al., 2009; Asami et al., 2011; De Castro-Manglano et al., 2011), and in High Risk subjects (Pantelis et al., 2005) they do not have compared the FEP patients with chronic patients but only with HC. A volume decrease particularly sited in the right part of the frontal lobe was found in the study of Turetsky (Turetsky et al., 1995), but in chronic schizophrenia patients and not in FEP, and in a study of Mathalon (Mathalon et al., 2001) but in schizophrenic men and in a study of Job (Job et al., 2005) but in High Risk subjects.

This result on FEP patients might confirm the assumption that brain volume is more affected by loss in the very first time of the illness (Pantelis et al., 2005; Crespo-Facorro et al., 2010).

In conclusion, our results are of difficult interpretation because they are not in line with previous findings: as described previously, there are common evidence of OFC alteration in schizophrenia and in psychosis in general, but this alterations are volume reductions in the majority of the cases, secondly, also structural volume alterations of the white matter are seldom mentioned in brain imaging studies. Nevertheless, our finding seems to confirm the implication of the OFC in schizophrenia and in psychosis in general, and the hypothesis that alterations of this region may arise from an interaction between brain maturation and mechanisms related to disease chronicity.

Our study has two big limits. First of all the sample of the FEP patients is relatively small in comparison to that of the chronic schizophrenia, and therefore, in the longitudinal comparison, it was not possible to separate FEP patients that developed schizophrenia from those who developed an affective psychosis. Our FEP patient group includes 3 subjects who developed an affective psychosis, 2 subjects who developed schizophrenia, and 11 subjects who developed an unspecific psychotic syndrome. Therefore, we can not make any consideration about the course of the illness of the FEP patients, even though these could be a minor limit, since evidence in literature of a substantial overlap of volume abnormalities sites in schizophrenia and affective psychoses.

The second limit is the lack of information about the antipsychotic drug assumption of our sample. Three studies found the OFC to be affected by antipsychotic intake: Stip (Stip et al., 2009) found greater OFC grey matter density in SCZ patients after 5 months of quetiapine intake, Molina (Molina et al., 2004) found a significant direct association between the degree of OFC atrophy and the improvement of positive symptoms with olanzapine and Malla (Malla et al., 2011) found a bilateral reduction of the OFC in psychotic patients with a longer duration of untreated psychosis (DUP), as compared to those with a short DUP. Therefore, it is highly probable that our results may be influenced by medication intake: SCZ patients should have a minor decrease of the OFC grey matter due to antipsychotic assumption, indeed (Dazzan et al., 2005) atypical antipsychotics seems to have a protective role on brain volume.

Strength of this study is that it is one of the few studies, conducted with a ROI approach, that has considered the subdivision of the OFC in its lateral and medial part, and that each of this parts have been segmented into grey and white matter. As mentioned previously, the ROI method has the strength of being particularly indicated for very small brain areas, as our OFC subdivisions.

Further, it would be of interest to enlarge the sample, divide and stratificate the FEP group for diagnosis (schizophrenia or affective spectrum) after one year, and to correlate the volumes also with performance on neuropsychological test.

7. REFERENCES

- Amaddeo, F., Burti, L., Ruggeri, M., Tansella, M., (2009). Long-term monitoring and evaluation of a new system of community-based psychiatric care. Integrating research, teaching and practice at the University of Verona. *Ann. Ist. Super. Sanità* 45, 43-53.
- Amaddeo F., Tansella M., (2009). Information systems for mental health. *Epidemiologia e Psichiatria Sociale* 18, 1-4.
- Asami T., Bouix S., Whitford T.J., Shenton M.E., Salisbury D.F., McCarley R.W., (2011). Longitudinal loss of gray matter volume in patients with first-episode schizophrenia: DARTEL automated analysis and ROI validation. *Neuroimage*, in press.
- Baaré W.F., Hulshoff Pol H.E., Hijman R., Mali W.P., Viergever M.A. & Kahn R.S. (1999). Volumetric analysis of frontal lobe regions in schizophrenia: relation to cognitive function and symptomatology. *Biological Psychiatry* 45, 1597-1605
- Bechara A. (2004). The role of emotion in decision-making: evidence from neurological patients with orbitofrontal damage. *Brain Cognition* 55, 30-40
- Bellani M. & Brambilla P. (2008). Is there a neurobiological basis of insight in Schizophrenia? *Epidemiologia e Psichiatria Sociale* 17, 28-30.
- Bellani M., Cerruti S. & Brambilla P. (2010). Orbitofrontal abnormalities in Schizophrenia. *Epidemiologia e Psichiatria Sociale* 19, 23-25.
- Bellani M., Tomelleri L. & Brambilla P. (2009). Emotion-based Decision Making in Schizophrenia: evidence from the Iowa Gambling Task. *Epidemiologia e Psichiatria Sociale* 18, 104-106.
- Berlin, H. A., Rolls, E. T., Kischka, U. (2004a). Impulsivity, time perception, emotion, and reinforcement sensitivity in patients with orbitofrontal cortex lesions. *Brain* 127, 1108-26.
- Bhojraj TS, Sweeney JA, Prasad KM, Eack SM, Francis AN, Miewald JM, Montrose DM, Keshavan MS. (2011). Gray matter loss in young relatives at risk for schizophrenia: relation with prodromal psychopathology. *Neuroimage*, 54, 272-9.
- Bleuler E. 1950. Dementia Praecox or the Group of Schizophrenias. Zinkin J trans-ed. New York, NY: International Universities Press.

Borgwardt S.J., McGuire P.K., Aston J., Gschwandtner U., Pflüger M.O., Stieglitz R.D., Radue E.W., Riecher-Rössler A. (2008). Reductions in frontal, temporal and parietal volume associated with the onset of psychosis. *Schizophrenia Research* 106, 108-14.

Brewer WJ, Wood SJ, Phillips LJ, Francey SM, Pantelis C, Yung AR, Cornblatt B, McGorry PD. (2006). Generalized and specific cognitive performance in clinical high-risk cohorts: a review highlighting potential vulnerability markers for psychosis. *Schizophrenia Bulletin*, 32, 538-555.

Brown G.G., Lee J.S., Strigo I.A., Caligiuri M.P., Meloy M.J., Lohr J. (2011). Voxel-based morphometry of patients with schizophrenia or bipolar I disorder: a matched control study. *Psychiatry Research*, 194, 149-156.

Cannon T.D., Rosso I.M., Hollister J.M., Bearden C.E., Sanchez L.E., Hadley T. (2000). A perspective study of genetic and perinatal influences in the etiology of schizophrenia. *Schizophrenia Bulletin* 26, 351-66.

Chan R.C., Di X., McAlonan G.M., Gong Q.Y. (2009b). Anatomical Abnormalities in High-Risk Individuals, First-Episode, and Chronic Schizophrenia: An Activation Likelihood Estimation Meta-analysis of Illness Progression. *In press*.

Cahn W., Rais M., Stigter F.P., van Haren N.E., Caspers E., Hulshoff Pol H.E., Xu Z., Schnack H.G., Kahn R.S. (2009a). Psychosis and brain volume changes during the first five years of schizophrenia. *European Neuropsychopharmacology* 19, 147-51.

Crespo-Facorro B., Kim J., Andreasen N.C., O'Leary D.S., Magnotta V., 2000. Regional frontal abnormalities in schizophrenia: a quantitative gray matter volume and cortical surface size study. *Biological Psychiatry*, 48, 110-119.

Crespo-Facorro B., Roiz-Santiáñez R., Pérez-Iglesias R., Tordesillas-Gutiérrez D., Mata I., Rodríguez-Sánchez J.M., de Lucas E.M., Vázquez-Barquero J.L. (2009). Specific brain structural abnormalities in first-episode schizophrenia. A comparative study with patients with schizophreniform disorder, non-schizophrenic non-affective psychoses and healthy volunteers. *Schizophrenia research*, 115, 191-201.

Dazzan P, Morgan KD, Orr K, et al. (2005). Different effects of typical and atypical antipsychotics on grey matter in first episode psychosis: the AESOP study. *Neuropsychopharmacology* 30, 765–774.

Dazzan P., Soulsby B., Mechelli A., Wood S.J., Velakoulis D., Phillips L.J., Yung A.R., Chitnis X., Lin A., Murray R.M., McGorry P.D., McGuire P.K., Pantelis C. (2011). Volumetric Abnormalities Predating the

Onset of Schizophrenia and Affective Psychoses: An MRI Study in Subjects at Ultrahigh Risk of Psychosis. *Schizophrenia Bulletin*, in press.

de Castro-Manglano P., Mechelli A., Soutullo C., Landecho I., Gimenez-Amaya J.M., Ortuño F., McGuire P. (2011). Longitudinal changes in brain structure following the first episode of psychosis. *Psychiatric research*, 191, 166-173.

DeLisi L.E. (2008). The concept of progressive brain change in schizophrenia: implications for understanding schizophrenia. *Schizophrenia Bulletin*, 34, 312-321.

Ellison-Wright I. & Bullmore E. (2010). Anatomy of bipolar disorder and schizophrenia: a meta-analysis. *Schizophrenia Research*. 117, 1-12.

Ellison-Wright I., Glahn D.C., Laird A.R., Thelen SM, Bullmore E.(2008). The anatomy of first-episode and chronic schizophrenia: an anatomical likelihood estimation meta-analysis. *American Journal of Psychiatry* 165, 1015-1023.

Fornito A., Yücel M., Patti J., Wood S.J., Pantelis C.(2009). Mapping grey matter reductions in schizophrenia: an anatomical likelihood estimation analysis of voxel-based morphometry studies. *Schizophrenia Research* 108,104-113.

Gansler D.A., McLaughlin N.C., Iguchi L., Jerram M., Moore D.W., Bhadelia R. & Fulwiler C. (2009). A multivariate approach to aggression and the orbital frontal cortex in psychiatric patients. *Psychiatry Research* 31, 145-154.

Giuliani NR, Calhoun VD, Pearlson GD, Francis A, Buchanan RW. (2005). Voxel-based morphometry versus region of interest: a comparison of two methods for analyzing gray matter differences in schizophrenia. *Schizophrenia Research*, 74, 135-147.

Glahn D.C., Laird A.R., Ellison-Wright I., Thelen S.M., Robinson J.L., Lancaster J.L., Bullmore E., Fox P.T. (2008). Meta-analysis of gray matter anomalies in schizophrenia: application of anatomic likelihood estimation and network analysis. *Biological Psychiatry*, 64, 774-81.

Goldstein J.M., Goodman J.M., Seidman L.J., Kennedy D.N., Makris N., Lee H., Tourville J., Caviness V.S. Jr, Faraone S.V. & Tsuang MT. (1999). Cortical abnormalities in schizophrenia identified by structural magnetic resonance imaging. *Archives of General Psychiatry* 56, 537-547.

Gray J.R., Braver T.S. & Raichle M.E. (2002). Integration of emotion and cognition in the lateral prefrontal cortex. *Proceedings of the National Academy of Science of the United States of America* 99, 4115-4120.

- Gur R.E., Cowell P.E., Latshaw A., Turetsky B.I., Grossman R.I., Arnold S.E., Bilker W.B. & Gur R.C. (2000). Reduced dorsal and orbital prefrontal gray matter volumes in schizophrenia. *Archives of General Psychiatry* 57, 761-768. Erratum in *Archives of General Psychiatry* 57, 858.
- Gur R.E., Keshavan M.S., Lawrie S.M. (2007). Deconstructing psychosis with human brain imaging. *Schizophrenia Bulletin*, 33, 921-931.
- Hanson D.R., Gottesmann I.I. (2005). Theories of schizophrenia a genetic-inflammatory-vascular synthesis. *BMC medical genetics*, 11, 6-7.
- Happaney K., Zelazo P.D. & Stuss D.T. (2004). Development of orbitofrontal function: current themes and future directions. *Brain Cognition* 55, 1-10.
- Ho B.C., Andreasen N.C., Nopoulos P., Arndt S., Magnotta V., Flaum M. (2003). Progressive structural brain abnormalities and their relationship to clinical outcome: a longitudinal magnetic resonance imaging study early in schizophrenia. *Archives of General Psychiatry* 60, 585-94.
- Hoptman M.J., Volavka J., Weiss E.M., Czobor P., Szeszko P.R., Gerig G., Chakos M., Blocher J., Citrome L.L., Lindenmayer J.P., Sheitman B., Lieberman J.A. & Bilder R.M. (2005). Quantitative MRI measures of orbitofrontal cortex in patients with chronic schizophrenia or schizoaffective disorder. *Psychiatry Research* 30, 133-145.
- Hulshoff Pol H.E., Kahn R.S. (2008). What happens after the first episode? A review of progressive brain changes in chronically ill patients with schizophrenia. *Schizophrenia Bulletin* 34, 354-66.
- Job D.E., Whalley H.C., Johnstone E.C., Lawrie S.M. (2005). Grey matter changes over time in high risk subjects developing schizophrenia. *Neuroimage*, 25, 1023-1030.
- Nickl-Jockschat T., Schneider F., Pagel A.D., Laird A.R., Fox P.T. (2011). Progressive pathology is functionally linked to the domains of language and emotion: meta-analysis of brain structure changes in schizophrenia patients. *European Archives of Psychiatry and Clinical Neuroscience*, 261, 166-171.
- Kasperek T., Prikryl R., Schwarz D., Kucerova H., Marecek R., Mikl M., Vanicek J., Ceskova E. (2009). Gray matter morphology and the level of functioning in one-year follow-up of first-episode schizophrenia patients. *Progress in Neuro-psychopharmacology and Biological Psychiatry* 33, 1438-1446.
- Kawasaki Y., Suzuki M., Nohara S., Hagino H., Takahashi T., Matsui M., Yamashita I., Chitnis X.A., McGuire P.K., Seto H. & Kurachi M. (2004). Structural brain differences in patients with schizophrenia and schizotypal disorder demonstrated by voxel-based morphometry. *European Archives of Psychiatry and Clinical Neuroscience* 254, 406-414.

- Keshavan MS. (1999). Development, disease and degeneration in schizophrenia: a unitary pathophysiological model. *Journal of Psychiatric Research*, 33, 513-21.
- Keshavan M.S., Morris D.W., Sweeney J.A., Pearlson G., Thaker G., Seidman L.J., Eack S.M., Tamminga C. (2011). A dimensional approach to the psychosis spectrum between bipolar disorder and schizophrenia: the Schizo-Bipolar Scale. *Schizophrenia research*, 133, 250-254.
- Kraepelin E. Dementia Praecox and Paraphrenia. Barclay RM, trans-ed. 1919; New York, NY: Krieger, 1971 edition.
- Kringelbach M.L., Rolls E.T., (2004). The functional neuroanatomy of the human orbitofrontal cortex: evidence from neuroimaging and neuropsychology. *Progress in Neurobiology*, 72, 341-372.
- Kringelbach M.L. (2005). The human orbitofrontal cortex: linking reward to hedonic experience. *Nature Reviews. Neurosciences*. 6, 691-702.
- Kubicki, M., Shenton, M.E., Salisbury, D.F., Hirayasu, Y., Kasai, K., Kikinis, R., Jolesz, F.A., McCarley, R.W. (2002). Voxelbased morphometric analysis of gray matter in first episode schizophrenia. *Neuroimage* 17, 1711 –1719.
- Kumari V., Barkataki I., Goswami S., Flora S., Das M. & Taylor P. (2009). Dysfunctional, but not functional, impulsivity is associated with a history of seriously violent behaviour and reduced orbitofrontal and hippocampal volumes in schizophrenia. *Psychiatry Research* 15, 39-44.
- Lacerda A.L., Hardan A.Y., Yorbik O., Keshavan M.S. (2003). Measurement of the orbitofrontal cortex: a validation study of a new method. *Neuroimage* 19, 665-673.
- Lacerda A.L., Keshavan M.S., Hardan A.Y., Yorbik O., Brambilla P., Sassi R.B., Nicoletti M., Mallinger A.G., Frank E., Kupfer D.J., Soares J.C. (2004). Anatomic evaluation of the orbitofrontal cortex in major depressive disorder. *Biological Psychiatry* 55, 353-358.
- Lacerda A.L., Hardan A.Y., Yorbik O., Vemulapalli M., Prasad K.M., Keshavan M.S. (2007). Morphology of the orbitofrontal cortex in first-episode schizophrenia: relationship with negative symptomatology. *Progress in Neuropsychopharmacology and Biological Psychiatry*. March 30, 510-516.
- Lamar M. & Resnick S.M. (2004). Aging and prefrontal functions: dissociating orbitofrontal and dorsolateral abilities. *Neurobiology of Aging* 25, 553–558.

Lawrie SM, Whalley H, Kestelman JN, Abukmeil SS, Byrne M, Hodges A, Rimmington JE, Best JJ, Owens DG, Johnstone EC. (1999). Magnetic resonance imaging of brain in people at high risk to develop schizophrenia. *Lancet*, 353, 30-33.

Lewis DA, Levitt P (2002). Schizophrenia as a disorder of neurodevelopment. *Annual Reviews of Neurosciences* 25, 409-432.

Lieberman JA. (1999) Is schizophrenia a neurodegenerative disorder? A clinical and neurobiological perspective. *Biological Psychiatry*, 46, 729–739.

Malla A.K., Bodnar M., Joobar R., Leage M. (2011). Duration of untreated psychosis is associated with orbital–frontal grey matter volume reductions in first episode psychosis. *Schizophrenia Research*, 125, 13-20.

Mané A., Falcon C., Mateos J.J., Fernandez-Egea E., Horga G., Lomeña F., Bargalló N., Prats-Galino A., Bernardo M., Parellada E. (2009). Progressive gray matter changes in first episode schizophrenia: a 4-year longitudinal magnetic resonance study using VBM. *Schizophrenia Research* 114, 136-143.

Marenco S., Weinberger D.R., (2000). The neurodevelopmental hypothesis of schizophrenia: Following a trail of evidence from cradle to grave. *Development and psychopathology*, 12, 501-527.

Mathalon D.H., Sullivan E.V., Lim K.O., Pfefferbaum A., 2001. Progressive brain volume changes and the clinical course of schizophrenia in men: a longitudinal magnetic resonance imaging study. *Archives of General Psychiatry*, 58, 148-157.

Mathalon DH, Rapoport JL, Davis KL, et al. 2003. Neurotoxicity, neuroplasticity, and magnetic resonance imaging morphometry. *Archives General Psychiatry*, 60,846–8.

McCarley, R.W., Wible, C., Frumin, M., Hirayasu, Y., Levitt, J.J., Fischer, I.A., Shenton, M.E., (1999). MRI anatomy of schizophrenia. *Biological Psychiatry* 45, 1099-1119.

Matsui M., Suzuki M., Zhou S.Y., Takahashi T., Kawasaki Y., Yuuki H., Kato K. & Kurachi M. (2008). The relationship between prefrontal brain volume and characteristics of memory strategy in schizophrenia spectrum disorders. *Progress in Neuro-psychopharmacology and Biological Psychiatry* 12, 1854-1862.

Molina V., Sanz J., Benito C., Palomo T., (2004). Direct association between orbitofrontal atrophy and the response of psychotic symptoms to olanzapine in schizophrenia. *International Clinical Psychopharmacology* 2004, 19:221–228.

Nakamura M., Salisbury D.F., Hirayasu Y., Bouix S., Pohl K.M., Yoshida T., Koo M.S., Shenton M.E., McCarley R.W. (2007). Neocortical gray matter volume in first episode schizophrenia and first episode affective psychosis: a cross sectional and longitudinal MRI study. *Biological Psychiatry*, 62, 773-783.

Nakamura M., Nestor P.G., Levitt J.J., Cohen A.S., Kawashima T., Shenton M.E. & McCarley R.W. (2008). Orbitofrontal volume deficit in schizophrenia and thought disorder. *Brain* 131, 180-195.

Nesvag R., Saetre P., Lawjer G., Jonsson E.G., Agartz I. (2009). The relationship between symptom severity and regional cortical and grey matter volumes in schizophrenia. *Progress in Neuro-psychopharmacology and Biological Psychiatry*, 33, 482-490.

Nuecherlein K.H., Dawson M.E. (1984). A Heuristic Vulnerability/Stress Model of Schizophrenic Episodes. *Schizophrenia Bulletin* 10, 300-312.

Olabi B., Ellison Wright I., McIntosh A.M., Wood S.J., Bullmore E., Lawrie S.M. (2011). Are There Progressive Brain Changes in Schizophrenia? A Meta-Analysis of Structural Magnetic Resonance Imaging Studies. *Biological Psychiatry* 70, 88-96.

Ongür D. & Price J.L. (2000). The organization of networks within the orbital and medial prefrontal cortex of rats, monkeys and humans. *Cerebral Cortex* 10, 206-19.

Paillère-Martinot M., Caclin A., Artiges E., Poline J.B. (2001). Cerebral grey and white matter reductions and clinical correlates in patients with early onset schizophrenia. *Schizophrenia Research*, 50, 19-26.

Pantelis C., Velakoulis D., McGorry P.D., Wood S.J., Suckling J., Phillips L.J., Yung A.R., Bullmore E.T., Brewer W., Soulsby B., Desmond P., McGuire P.K. (2003). Neuroanatomical abnormalities before and after onset of psychosis: a cross-sectional and longitudinal MRI comparison. *The Lancet* 25, 281-288.

Pantelis C., Yücel M., Wood S.J., Velakoulis D., Sun D., Berger G., Stuart G.W., Yung A., Phillips L., McGorry P.D. (2005). Structural brain imaging evidence for multiple pathological processes at different stages of brain development in schizophrenia. *Schizophrenia Bulletin* 31, 672-696.

Pantelis C., Yücel M., Bora E., Fornito A., Testa R., Brewer W.J., Velakoulis D., Wood S.J. (2009). Neurobiological markers of illness onset in psychosis and schizophrenia: The search for a moving target. *Neuropsychology review*, 19, 385-398.

Resnick S.M., Lamar M. & Driscoll I. (2007). Vulnerability of the Orbitofrontal Cortex to Age-Associated Structural and Functional Brain Changes. *Annals of the New York Academy of Sciences* 1121, 562-575.

- Riffkin J., Yücel M., Maruff P., Wood S.J., Soulsby B., Olver J., Kyrios M., Velakoulis D. & Pantelis C. (2005). A manual and automated MRI study of anterior cingulate and orbito-frontal cortices, and caudate nucleus in obsessive-compulsive disorder: comparison with healthy controls and patients with schizophrenia. *Psychiatry Research* 28, 99-113.
- Rolls E.T. (2004). The functions of the orbitofrontal cortex. *Brain Cognition* 55, 11-29.
- Rupp C.I., Fleischhacker W.W., Kemmler G., Kremser C., Bilder R.M., Mechtcheriakov S., Szeszko P.R., Walch T., Scholtz A.W., Klimbacher M., Maier C., Albrecht G., Lechner-Schoner T., Felber S. & Hinterhuber H. (2005). Olfactory functions and volumetric measures of orbitofrontal and limbic regions in schizophrenia. *Schizophrenia Research* 74, 149-61.
- Sapara A., Cooke M., Fannon D., Francis A., Buchanan R.W., Anilkumar A.P., Barkataki I., Aasen I., Kuipers E. & Kumari V. (2007). Prefrontal cortex and insight in schizophrenia: a volumetric MRI study. *Schizophrenia Research* 89, 22-34.
- Schobel S.A., Kelly M.A., Corcoran C.M., Van Heertum K., Seckinger R., Goetz R., Harkavy-Friedman J. & Malaspina D. (2009). Anterior hippocampal and orbitofrontal cortical structural brain abnormalities in association with cognitive deficits in schizophrenia. *Schizophrenia Research* 114, 110-118
- Schultz C.C., Koch K., Wagner G., Roebel M., Schachtzabel C., Gaser C., Nenadic I., Reichenbach J.R., Sauer H., Schlösser R.G. (2010). Reduced cortical thickness in first episode schizophrenia. *Schizophrenia Research* 116, 204-209.
- Shad M.U., Muddasani S. & Keshavan M.S. (2006). Prefrontal subregions and dimensions of insight in first-episode schizophrenia--a pilot study. *Psychiatry Research* 30, 35-42.
- Shapleske J., Rossell S.L., Chitnis X.A., Suckling J., Simmons A., Bullmore E.T., Woodruff P.W. & David A.S. (2002). A computational morphometric MRI study of schizophrenia: effects of hallucinations. *Cerebral Cortex* 12, 1331-1341.
- Stip E., Mancini-Marie A., Letourneau G., Fahim C., Mensour B., Crivello F., Dollfus S., (2009). Increased grey matter densities in schizophrenia patients with negative symptoms after treatment with quetiapine: a voxel-based morphometry study. *International Clinical Psychopharmacology*, 24, 34-41.
- Szeszko P.R., Bilder R.M., Lencz T., Ashtari M., Goldman R.S., Reiter G., Wu H. & Lieberman J.A. (2000). Reduced anterior cingulate gyrus volume correlates with executive dysfunction in men with first-episode schizophrenia. *Schizophrenia Research* 16, 97-108.
- Tanskanen P, Ridler K, Murray GK, Haapea M, Veijola JM, Jääskeläinen E, Miettunen J, Jones PB, Bullmore ET, Isohanni MK. (2008). Morphometric brain abnormalities in schizophrenia in a population-based sample: relationship to duration of illness. *Schizophrenia Bulletin*, 36, 766-77.

- Takayanagi Y., Takahashi T., Orikabe L., Masuda N., Mozue Y., Nakamura K., Kawasaki Y., Itokawa M., Sato Y., Yamasue H., Kasai K., Okazaki Y., Suzuki M. (2010). Volume reduction and altered sulco-gyral pattern of the orbitofrontal cortex in first-episode schizophrenia. *Schizophrenia Research*, 121, 55-65.
- Teasdale J.D., Howard R.J., Cox S.G., Ha Y., Brammer M.J., Williams S.C. & Checkley S.A. (1999). Functional MRI study of the cognitive generation of affect. *American Journal of Psychiatry* 156, 209-215.
- Tregellas J.R., Shatti S., Tanabe J.L., Martin L.F., Gibson L., Wylie K. & Rojas D.C. (2007). Gray matter volume differences and the effects of smoking on gray matter in schizophrenia. *Schizophrenia Research* 97, 242-249.
- Turetsky B., Cowell P.E., Gur R.C., Grossman R.I., Shtasel D.L., Gur R.E. (2005). Progressive Brain Volume Changes and the Clinical Course of Schizophrenia in Men. *Archives of General Psychiatry*, 52, 1061-1070.
- Van Haren N.E, Hulshoff Pol H.E., Schnack H.G., Cahn W., Mandl R.C., Collins D.L., Evans A.C., Kahn R.S. (2007). Focal gray matter changes in schizophrenia across the course of the illness: a 5-year follow-up study. *Neuropsychopharmacology* 32, 2057-2066.
- Van Haren N.E, Cahn W., Hulshoff Pol H.E., Kahn R.S. (2008). Schizophrenia as a progressive brain disease. *European Psychiatry*, 23, 245-254.
- Van Haren N.E., Schnack H.G., Cahn W., Van den Heuvel M.P., Lepage C., Collins L., Evans AC., Hulshoff Pol H.E., Kahn R.S. (2011). Changes in cortical thickness during the course of illness in schizophrenia. *Archives General Psychiatry*, 68, 871-880.
- Venkatasubramanian G., Jayakumar P.N., Gangadhar B.N., Keshavan M.S. (2008). Automated MRI parcellation study of regional volume and thickness of prefrontal cortex (PFC) in antipsychotic-naïve schizophrenia. *Acta Psychiatrica Scandinavica*, 117, 420-431.
- Walterfang M., Velacoulis D., Whitford T.J., Pantelis C., (2011). Understanding aberrant white matter development in schizophrenia: an avenue for therapy? *Expert review of neurotherapeutics*, 11, 971-987.
- Walton M.E., Devlin J.T., Rushworth M.F.S. (2004). Interaction between decision making and performance monitoring within prefrontal cortex. *Nature Neurosciences*, 11, 1259-1265.
- Weinberger, D.R. (1987). Implications of normal brain development for the pathogenesis of schizophrenia. *Archives of General Psychiatry*, 44, 660-669.
- Weinberger D.R. (1988). Schizophrenia and the frontal lobe. *Trends in neurosciences*, 11, 367-370.

- Weinberger D.R. (1994). The frontal lobes and schizophrenia. *The Journal of Neuropsychiatry and Clinical Neurosciences*, 6, 419-427.
- Wilke M., Kaufmann C., Grabner A., Pütz B., Wetter T.C., Auer DP. (2001). Gray matter-changes and correlates of disease severity in schizophrenia: a statistical parametric mapping study. *Neuroimage* 13, 814-824.
- White T., Nelson M., Lim K.O.. (2008). Diffusion tensor imaging in psychiatric disorders. *Topics in magnetic resonance imaging*, 19, 97-109.
- Whitford T.J., Grieve S.M., Farrow T.F., Gomes L., Brennan J., Harris A.W., Gordon E., Williams L.M. (2006). Progressive grey matter atrophy over the first 2-3 years of illness in first-episode schizophrenia: a tensor-based morphometry study. *Neuroimage* 32, 511-9.
- Witthaus H., Kaufmann C., Bohner G., Ozgürdal S., Gudlowski Y., Gallinat J., Ruhrmann S., Brüne M., Heinz A., Klingebiel R., Juckel G. (2009). Gray matter abnormalities in subjects at ultra-high risk for schizophrenia and first-episode schizophrenic patients compared to healthy controls. *Psychiatry Research* 173, 163-169.
- Woods BT. (1998) Is schizophrenia a progressive neurodevelopmental disorder? Toward a unitary pathogenetic mechanism. *American Journal of Psychiatry*, 155,1661-70.
- Wright IC, Rabe-Hesketh S, Woodruff PW, David AS, Murray RM, Bullmore ET (2000). Meta-analysis of regional brain volumes in schizophrenia. *American Journal of Psychiatry*, 157, 16–25.
- Yamasue H., Iwanami A., Hirayasu Y., Yamada H., Abe O., Kuroki N., Fukuda R., Tsujii K., Aoki S., Ohtomo K., Kato N. & Kasai K. (2004). Localized volume reduction in prefrontal, temporolimbic, and paralimbic regions in schizophrenia: an MRI parcellation study. *Psychiatry Research* 15, 195-207.
- Yu K., Cheung C., Leung M., Li Q., Chua S., McAlonan G. (2010). Are bipolar disorder and schizophrenia neuroanatomically distinct? An anatomical likelihood meta-analysis. *Frontiers in human neurosciences*, 4, 189-200.