Appendectomy in Women. Is the Laparoscopic Approach Always Better Than the "Open" Approach in Uncomplicated Appendicitis?

Andrea Casarotto, MD, Fabio R. Zarantonello, MD, and Matteo Rebonato, MD

Background: Acute appendicitis is the most common emergency in abdominal surgery, but remains a continuing controversy regarding the most appropriate method of removing the inflamed appendix.

Materials and Methods: From January 2002 to December 2012, 1037 women underwent appendectomy (average age: 25 ± 15.7 y; range: 6 to 91 y). Of these, 519 underwent open appendectomy (OA) and 518 underwent laparoscopic appendectomy (LA). For all the patients we determined the postoperative hospital stay, the eventual readmissions within 30 days after discharge, the length of surgical procedures (data were available only for the period from January 2008 to December 2012), the costs for the OA and LA, and the rate of negative appendicitis.

Results: In our cohort of patients, 189 women (18.2%) had a negative appendectomy. Considering the postoperative hospital stay (average: 4.2 ± 3.6 d; range: 1 to 32 d in OA group and average: 3.9 ± 3.1 d; range: 1 to 21 d in LA group; $P = 0.15$) there were no statistical differences between 2 groups. The average length of surgical procedures in LA group was 42.3 ± 18.4 minutes (range: 8 to 135 min) and 43.2 ± 19 minutes in the OA group (range: 10 to 135 min) ($P = 0.63$). The average net cost of LA was 1203.61 euros, whereas for OA it was 95.18 euros. In this study, we considered only the surgical materials.

Conclusions: LAs are not associated with a lower complication rate than the OAs and, above all, LAs are more expensive than OAs. Also we believe that laparoscopic approach should be used only in case of unclear abdominal pain and not for the treatment of clear acute and uncomplicated appendicitis.

Key Words: laparoscopic appendectomy, open appendectomy, appendectomy in women, false appendicitis

(*Surg Laparosc Endosc Percutan Tech* 2014;24:406–409)

Acute appendicitis is the most common emergency in abdominal surgery. Open appendectomy (OA) performed through the right lower quadrant incision was first described in 1894.[1] It has become the standard treatment of choice for acute appendicitis, remaining mainly unchanged for 100 years due to its favorable efficacy and safety. Laparoscopic appendectomy (LA), first performed by Semm[2] in 1983, has gradually gained acceptance. However, it remains as a continuing controversy in the literature regarding the most appropriate method of removing the inflamed appendix.[3] Although some studies claimed LA to be superior to OA in terms of a quicker and less painful recovery, less postoperative complications, and better cosmesis, other studies found no such advantages or even favoured the traditional approach.[4]

Although several studies have shown a beneficial effect of LA in women in the absence of gross pelvic disease, these studies had major flaws in their design or methodology.[5–8] Thus, questions remain about the internal and external validity of these studies.[5]

In this study we considered only women aged 6 to 91 years who underwent appendectomy for acute appendicitis. The main objective was to identify the best approach in our cohort of patients to determine which technique, LA or OA, gives better patient outcome.

MATERIALS AND METHODS

From January 2002 to December 2012, 2199 appendectomies were performed in our department [746 (33.9%) LA and 1453 (66.1%) OA]. We considered only 1037 women (47.1%) who underwent appendectomy (average age: 25 ± 15.7 y; range: 6 to 91 y). Of these, 519, who underwent OA and 518, who underwent LA, were enrolled into this study, retrospectively. Young female and obese women underwent diagnostic laparoscopy to detect the presence of gynecologic pathologies mimicking appendicitis.

The average age in 2 groups was 31 ± 15.7 in the LA group and 28.3 ± 21.3 in OA group, respectively ($P = 0.52$). Surgical procedures were performed by the attending surgeons, and a total number of 12 surgeons participated in this study.

All appendectomies were performed under general anesthesia: for the induction phase we used fentanyl citrate 5 μg/kg, propofol 1.5 to 2.5 mg/kg, and rocuronium 0.6 mg/kg; for the maintenance phase we used remifentanil hydrochloride 0.1 to 1 μg/kg/min and propofol 6 mg/kg/min.

LAs were performed using a standardized 3-trocar approach (umbilical, 5-mm port; suprapubic, 5-mm port; up-right quadrant, 10- to 12-mm port) (Covidien, Mansfield, MA). The incisions were made with a scalpel number 11. The pneumoperitoneum was performed with a Verres needle. Carbon dioxide was insufflated into the peritoneal cavity at a rate of 4 to 6 L/min to maintain a pressure of 14 mm Hg during surgery. With the patient in the Trendelenburg position and right side up, the small bowel was retracted away from the lower right quadrant. After the laparoscopic exploration using a video-camera (K Storz GmbH & Co, Tuttlingen, Germany) with 30-degree angle of visualization to detect any abnormalities in the abdomen and the exposure of the pelvis, the cecum

Received for publication November 27, 2013; accepted March 7, 2014.
From the Surgical Department, "Alto Vicentino" Hospital, Santorso (Vi), Italy.
The authors declare no conflicts of interest.
Reprints: Andrea Casarotto, MD, Surgical Department, "Alto Vicentino" Hospital, 36014 Santorso (Vi), Italy (e-mail: andrea.casarotto@ulss4.veneto.it).

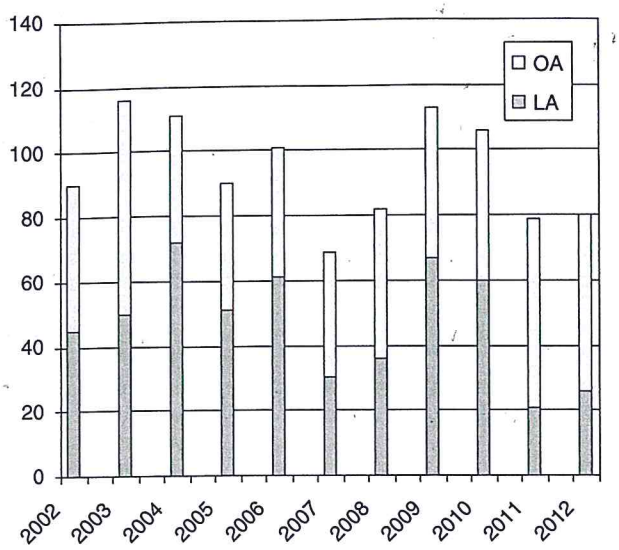

FIGURE 1. Number of OA and LA in different years in women. LA indicates laparoscopic appendectomy; OA, open appendectomy.

was lifted to expose the base of appendix. An inflammatory mass or hard adhesion, if present, was dissected gently with blunt instruments. The mesoappendix was identified and was dissected using a vascular stapler (Endo-GIA, DLU 30 mm white; Covidien). Then, the appendix was divided using an intestinal stapler (Endo-GIA, DLU 30 mm blue; Covidien) and removed through the 10- to 12-mm ports, in general using a specimen bag (Endo-Catch; Covidien). A drain type Penrose was used in all patients. In all LAs, we used 1 brained absorbable sutures 0 (Polysorb; Covidien) to suture the incision in linea alba, 1 nonabsorbable polyamide monofilament 0 (Dafilon; Braun Melsungen AG, Melsungen, Germany) to suture the incisions, and 1 nonabsorbable polyester sutures 0 (Ti-Cron; Covidien) to fix the drain. Ten gauzes were used.

In contrast, OAs were performed through a standard McBurney splitting incision of the lower right quadrant muscle (right pararectal incision) using for the skin a scalpel number 24 and the electric scalpel. For the incision of the trasversalis we used a scalpel number 15, and a scalpel number 11 was used for the appendix. A stump ligature was performed with invagination using 3 brained absorbable sutures 0 (Polysorb; Covidien). In all patients we used Penrose drain, fixed with 1 nonabsorbable polyester sutures 0 (Ti-Cron; Covidien). A nonabsorbable polyamide monofilament 0 (Dafilon; Braun Melsungen AG) or metallic skin stapler (Visistat Skin Stapler; Teleflex Medical, NC) was used to suture the incision. In OAs, 20 steril gauzes were used.

For all patients we determined the postoperative hospital stay, the eventually readmissions within 30 days after discharge, the length of surgical procedures (data were available only for the period from January 2008 to December 2012) and the costs for the OA and LA. In our cohort of patients, we also determined the rate of negative appendicitis, defined as either a normal appendix after resection for suspected appendicitis or a medically unnecessary appendectomy.[9] These patients were not considered in this study. All statistical analyses were 2-sided and P-values <0.05 were considered statistically significant.

RESULTS

From January 2002 to December 2012, 1037 women underwent appendectomy (519 OAs and 518 LAs) (Fig. 1). There was no mortality in either groups and neither major intraoperative complication, such as bleeding or bowel perforations.

Of this cohort of patients, 189 women (18.2%) had a negative appendectomy. In these patients, the appendix was not removed.

In Table 1 we reported the postoperative hospital stay (average: 4.2 ± 3.6 d; range: 1 to 32 d in OA group and average: 3.9 ± 3.1 d; range: 1 to 21 d in LA group. $P = 0.15$) considering the different years and there were not statistical differences between the 2 groups of patients.

In Table 2 we reported the length of surgical procedures (average: 42.3 ± 18.4 min; range: 8 to 135 min in LA group and average: 43.2 ± 19 min; range: 10 to 135 min in OA group; $P = 0.63$). In that period, 9 patients (0.87%) were readmitted in our Department within 30 days from discharge. Of these patients, 4 underwent LA and 5 OA.

In the group of patients who underwent LA, 1 patient was readmitted for vomiting, 1 patient for abdominal pain, 1 patient for wound infection, and 1 patient for intestinal obstruction. The patient with the wound infection underwent a surgical drainage, whereas the other patients underwent a conservative approach obtaining the remission of the symptoms. In the group of patients who underwent the OA procedure, 4 patients were readmitted for intra-abdominal abscess and 1 patient for intestinal obstruction. All intra-abdominal abscesses were drained with an open approach, whereas the patient with intestinal obstruction was treated with nasogastric tube and parenteral saline nutrition, obtaining the solution.

The average net cost of LA was 1203.61 euros, whereas for OA it was 95.18 euros. We considered only the surgical materials, not the costs of surgical theater.

TABLE 1. Length of Hospital Stay in Different Years

Length of Hospital Stay (d)	2002	2003	2004	2005	2006	2007	2008	2009	2010	2011	2012
LA	3.60	4.34	3.07	4.00	4.20	3.50	3.80	3.34	3.75	3.40	3.00
OA	4.24	3.64	4.02	3.95	5.32	4.54	3.65	3.95	3.95	5.20	3.98
T-STU	1.13	1.03	2.02	0.08	1.34	1.46	0.33	1.68	0.36	1.48	1.62
P	0.26	0.30	0.05	0.94	0.18	0.15	0.74	0.10	0.72	0.14	0.11

LA indicates laparoscopic appendectomy; OA, open appendectomy.

TABLE 2. Length of Procedures (min)

Length of Procedures (min)	2008	2009	2010	2011	2012
LA	32.05	44.00	47.08	37.30	32.54
OA	43.26	44.00	46.00	41.07	41.04
T-STU	0.18	0.88	0.27	1.47	1.11
P	0.86	0.38	0.79	0.14	0.27

Data available from 2008 to 2012.
LA indicates laparoscopic appendectomy; OA, open appendectomy.

DISCUSSION

Acute appendicitis is a common cause of abdominal pain, especially in males with a male:female ratio of 1.4:1. It is expected that 8.6% of males and 6.7% of females develop appendicitis during their lifetime. Young age is a risk factor and almost 70% of the cases with acute appendicitis are under 30 years.[10]

Nevertheless, sometimes the diagnosis of acute appendicitis remains difficult because the symptoms are not specific: in fact, the typical clinical process begins with intermittent, stomach ache-like cramps thought to be caused by occlusion of the appendicular lumen. Pain can be difficult to localize and it is sometimes followed by nausea. Only when inflammation becomes transmural and causes peritonitis, the pain is classically located in the right lower quadrant.[11–14] Regarding the imaging for the diagnosis of acute appendicitis, ultrasonography (USG) is the preferred method because of the fact that it is easily applied and has no radiation effects. The sensitivity of USG in appendicitis ranges between 55% and 98%, and the specificity ranges between 78% and 100%. In infants and adults, the sensitivity of computed tomography (CT) in diagnosing acute appendicitis is higher compared with USG, but there is no remarkable difference in specificity. Especially in children and pregnant women, magnetic resonance imaging (MRI) can be used when the cause for abdominal pain remain unclear. In fact, comparing USG and MRI, the rates of accuracy, sensitivity, and negative predictive values are higher in MRI than USG.[15]

Also the most appropriate method of removing the inflamed appendix remains a continuing controversy in the literature.[3]

Since its introduction by McBurney in 1894,[1] appendectomy is the treatment of choice for acute appendicitis.

The surgical technique has remained nearly unchanged for over a century, as it combines therapeutic efficacy with low morbidity and mortality rates.[16] The evolution of endoscopic surgery led to the idea of performing appendectomy in laparoscopy, which was first described by Semm in 1983.[2] Nevertheless, the new method has only partly gained acceptance, because the advantages of LA were not as obvious as for laparoscopic cholecystectomy.[4] In recent years, there have been several advancements in laparoscopic surgery and intraoperative instruments. These improvements have contributed to several advantages of LA over the open technique, including reduced postoperative pain, fewer and earlier discharge from the hospital. In the literature, LA has been reported to be associated with less analgesic use, early start of oral nutrient intake, shorter hospital stay.[3,17–19] The disadvantages of LA are the use of disposable instruments, which adds to the cost and increases the operative time compared with OA.[20,21] Although some studies claimed LA to be superior to OA in terms of a quicker and less painful recovery, less postoperative complications, and better cosmesis, other studies found no such advantages or even favoured the traditional approach.

In this study, we did not find any differences between AO and LA regarding the operative time, length of hospital stay, and rate of readmission within 30 days from the discharge, in accordance with Sauerland et al.[22] In contrast, our conclusion is in disagreement with Groves et al.[23] In that study, in fact, there was no significant difference in the rate of postoperative organ space abscess, surgical reexploration, or rehospitalisation in children with perforated appendicitis, but LA had fewer surgical site infections and shorter lengths of hospital stay compared with OA without an increase in patient costs. We think that difference is in relation with the fact that in our case the patients were affected by uncomplicated appendix, without signs of perforation or abdominal obstruction, and for this reason the length of hospital stay was not significantly different between the 2 groups. For the same reason, the length of operative time and the rate of readmission within 30 days were no difference in our cohort of patients.

Beside these therapeutic effects of LA, laparoscopy may offer valuable diagnostic opportunities. So, as demonstrated in a very recent paper, a clear consensus as to the superiority of LA versus OA for uncomplicated appendicitis has been established.[24]

As surgical removal of an uninflamed, normal (innocent) appendix occurs in up to 50% of patients, it has been proposed not to remove the appendix in those situations, where other pathologies can be diagnosed during laparoscopy. It is also worth recalling that the appendix is used in reconstructive surgery[25] and in our cases, in the patients with an innocent appendix it was not removed. Before the advent of CT, a negative appendectomy rate as high as 20% was considered acceptable to avoid missing cases of appendicitis. Complications of acute appendicitis, including perforation, peritonitis, and sepsis were used to justify the large number of negative appendectomies. This has been particularly true among reproductive-age women, among whom the negative appendectomy rate has been reported to be as high as 40%, largely as the result of gynecologic mimics.[9]

In our group of patient with uninflamed appendix, the most common cause of abdominal pain was ovarian cyst ruptures, as demonstrated by Engin et al[10] who reported a rate of 72.3%. According to him, we believe that gynecologic consultation before appendectomy in women is necessary, but not sufficient.

Regarding the possibility of converting a laparoscopic approach into a laparotomic procedure, Abe et al[24] identified 4 independent risk factors of conversion: diffuse peritonitis on physical examination, CT grades of 4 or 5 (grade 4: abnormal appendix surrounded by fat stranding and fluid; grade 5: inflammatory mass or abscess),[26] C-reactive protein > 10 mg/dL, and perforating appendicitis.

In conclusion, in this study we demonstrated that LAs are not associated with a lower complication rate than the OAs and, above all, LAs are more expensive than OAs. In contrast, and according to the literature, we believe that preoperative USG, CT/MRI, or diagnostic laparoscopy may be helpful for decreasing negative appendectomy rate and it would be the first approach for the management of lower abdominal pain, especially in women of childbearing

age. In the end, we also believe that laparoscopic approach should be used only in case of unclear abdominal pain and not for the treatment of clear acute and uncomplicated appendicitis.

REFERENCES

1. McBurney C. The incision made in the abdominal wall in cases of appendicitis, with a description of a new method of operating. *Ann Surg*. 1894;20:38–43.
2. Semm K. Endoscopic appendectomy. *Endoscopy*. 1983;15: 59–64.
3. Li X, Zhang J, Sang L, et al. Laparoscopic versus conventional appendectomy a meta-analysis of randomized controlled trials. *BMC Gastroenterol*. 2010;10:129–136.
4. Sauerland S, Lefering R, Neugebauer EAM. Laparoscopic versus open surgery for suspected appendicitis (review). *Cochrane Database Syst Rev*. 2004;4:CD001546. Review.
5. Lal AK, Weaver AL, Hopkins MR, et al. Laparoscopic appendectomy in women without identifiable pathology undergoing laparoscopy for chronic pelvic pain. *JSLS*. 2013; 17:82–87.
6. Al Salilli M, Vilos GA. Prospective evaluation of laparoscopic appendectomy in women with chronic right lower quadrant pain. *J Am Assoc Gynecol Laparosc*. 1995;2:139–142.
7. DeCou JM, Gauderer MW, Boyle JT, et al. Diagnostic laparoscopy with planned appendectomy: an integral step in the evaluation of unexplained right lower quadrant pain. *Pediatr Surg Int*. 2004;20:123–126.
8. Agarwala N, Liu CY. Laparoscopic appendectomy. *J Am Assoc Gynecol Laparosc*. 2003;10:166–168.
9. Webb EM, Nguyen A, Wang ZJ, et al. The negative appendectomy rate: who benefits from preoperative CT? *AJR Am J Roentgenol*. 2011;197:861–866.
10. Engin O, Calik B, Yildirim M, et al. Gynecologic pathologies in our appendectomy series and literature review. *J Korean Surg Soc*. 2011;80:267–271.
11. Ertekin C, Guloğlu R, Taviloglu K. *Acil Cerrahi*. Istanbul: Nobel Tıp Kitabevleri; 2009:301–317.
12. Townsend CM, Beauchamp RD, Evers BM, et al. *Sabiston Textbook of Surgery*. 17th ed. Philadelphia: Saunders; 2004: 1381–1397.
13. Zinner MJ, Ashley SW. *Maingot's Abdominal Operations*. 11th ed. New York: McGraw-Hill; 2007:589–611.
14. Sayek I. Temel Cerrahi. Ankara: Güneş Kitabevi 2004: 1191-1197.
15. Binnebösel M, Otto J, Stumpf M, et al. Acute appendicitis. Modern diagnostics-surgical ultrasound. *Chirurg*. 2009;80: 579–587.
16. Eriksson S, Granström L. Randomized controlled trial of appendicectomy versus antibiotic therapy for acute appendicitis. *Br J Surg*. 1995;82:166–169.
17. Wei B, Qi CL, Chen TF, et al. Laparoscopic versus open appendectomy for acute appendicitis: a meta analysis. *Surg Endosc*. 2011;25:1199–1208.
18. Nana AM, Ouandji CN, Simoens C, et al. Laparoscopic appendectomies: results of a monocentric prospective and non-randomized study. *Hepatogastroenterology*. 2007;54: 1146–1152.
19. Yeh CC, Wu SC, Liao CC, et al. Laparoscopic appendectomy for acute appendicitis is more favorable for patients with comorbidities, the elderly, and those with complicated appendicitis: a nationwide population-based study. *Surg Endosc*. 2011;25:2932–2942.
20. Chung RS, Rowland DY, Li P, et al. A meta-analysis of randomized controlled trials of laparoscopic versus conventional appendectomy. *Am J Surg*. 1999;177:250–256.
21. Fallahzadeh H. Should a laparoscopic appendectomy be done? *Am Surg*. 1998;64:231–233.
22. Sauerland S, Jaschinski T, Neugebauer EAM. Laparoscopic versus open surgery for suspected appendicitis. *Cochrane Database Syst Rev*. 2010;10:CD001546. doi: 10.1002/14651858.CD001546.pub3.
23. Groves LB, Ladd MR, Gallaher JR, et al. Comparing the cost and outcomes of laparoscopic versus open appendectomy for perforated appendicitis in children. *Ann Surg*. 2013;79: 861–864.
24. Abe T, Nagaie T, Miyazaki M, et al. Risk factors of converting to laparotomy in laparoscopic appendectomy for acute appendicitis. *Clin Exp Gastroenterol*. 2013;6:109–114.
25. Tannoury J, Abboud B. Treatment options of inflammatory appendiceal masses in adults. *WJG*. 2013;19:3942–3950.
26. Tuggle KR, Ortega G, Bolorunduro OB, et al. Laparoscopic versus open appendectomy in complicated appendicitis: a review of the NSQIP database. *J Surg Res*. 2010;163:225–228.