

Generalized pustular psoriasis successfully treated with spesolimab: A case report

Noemi Brigenti¹, Paolo Gisondi, Francesco Bellinato and Giampiero Girolomoni

SAGE Open Medical Case Reports
 JCMS Case Reports
 Volume 12: 1–4
 © The Author(s) 2024
 Article reuse guidelines:
sagepub.com/journals-permissions
 DOI: 10.1177/2050313X241235451
journals.sagepub.com/home/sco



Abstract

Generalized pustular psoriasis is defined as a primary, sterile, macroscopically visible pustular eruption on non-acral skin, which can occur with or without systemic inflammation and/or psoriasis vulgaris, and can either be relapsing or be persistent, according to the European Rare and Severe Psoriasis Expert Network. The treatment of generalized pustular psoriasis may be challenging. We describe a 48-year-old woman with a 15-year history of severe generalized pustular psoriasis and plaque psoriasis resistant to multiple courses of treatments with conventional and biological agents who had a rapid, complete and durable (up to 12 months) clinical remission with spesolimab, an anti-interleukin-36 receptor antagonist monoclonal antibody recently approved for the treatment of generalized pustular psoriasis flares.

Keywords

Generalized pustular psoriasis, IL-36, spesolimab, Generalized Pustular Psoriasis Physician Global Assessment

Date received: 9 December 2023; accepted: 29 December 2023

Introduction

Generalized pustular psoriasis (GPP) is a rare inflammatory skin disease frequently presenting with systemic symptoms and extracutaneous manifestations.^{1,2} Several studies have indicated the key role of the interleukin-36 (IL-36) pathway in the pathogenesis of GPP, with a significant portion of patients carrying a null mutation in the IL-36 receptor antagonist gene.^{3,4} The flare is a distinguishing clinical feature of GPP and is characterized by the acute onset of wide, painful erythematous plaques covered by sterile pustules.^{2,5} Mortality rate during flare ranges from 2% to 16%.⁶ Treatment of the GPP flare with available drugs is unsatisfactory and/or frequent recurrence.⁷ Recently, the monoclonal antibody against IL-36-receptor, spesolimab, received approval for the treatment of GPP flares from the Food and Drug Administration and the European Medicines Agency.^{8,9} We describe a 48-year-old woman with a 15-year history of severe GPP associated with chronic plaque psoriasis resistant to multiple courses of treatments with conventional and biological agents, who had a rapid, complete and durable (up to 12 months) clearance with spesolimab.

Case report

A 48-year-old Moroccan woman with GPP and plaque psoriasis has been followed at our institution since she was

33 years old. From 2008 to 2016, the patient has been treated with the following medications either alone and in combination with partial and intermittent control of the disease: prednisone (5–25 mg/day), acitretin (10–35 mg/day), cyclosporine (4 mg/kg/day), methotrexate (10–20 mg/week), infliximab (5 mg/kg), etanercept (50 mg/week) and adalimumab (40 mg/week). From 2016 to 2022, satisfactory disease control was maintained with secukinumab 300 mg every 4 weeks. In October 2022, she experienced a severe GPP flare, with acute onset of large erythematous plaques covered with pustules affecting the back, abdomen, chest, and upper and lower limbs. She also had a fever (37.8°C), fatigue, malaise and agitation. Leukocytosis ($12.8 \times 10^9/L$) and elevated C-reactive protein (22.4 mg/L) were present. The Generalized Pustular Psoriasis Physician Global Assessment¹⁰ (GPPGA) was 3.5; the Generalized Pustular Psoriasis Area and Severity Index¹¹ (GPPASI) was 32.6; and the Dermatology Life and Quality Index (DLQI) was 30 (Figure 1(a) and (b)). The

Department of Medicine, Section of Dermatology and Venereology, University of Verona, Verona, Italy

Corresponding Author:

Noemi Brigenti, Department of Medicine, Section of Dermatology and Venereology, University of Verona, Piazzale Stefani, 1, Verona 37126, Italy.

Email: noemibrigenti@gmail.com



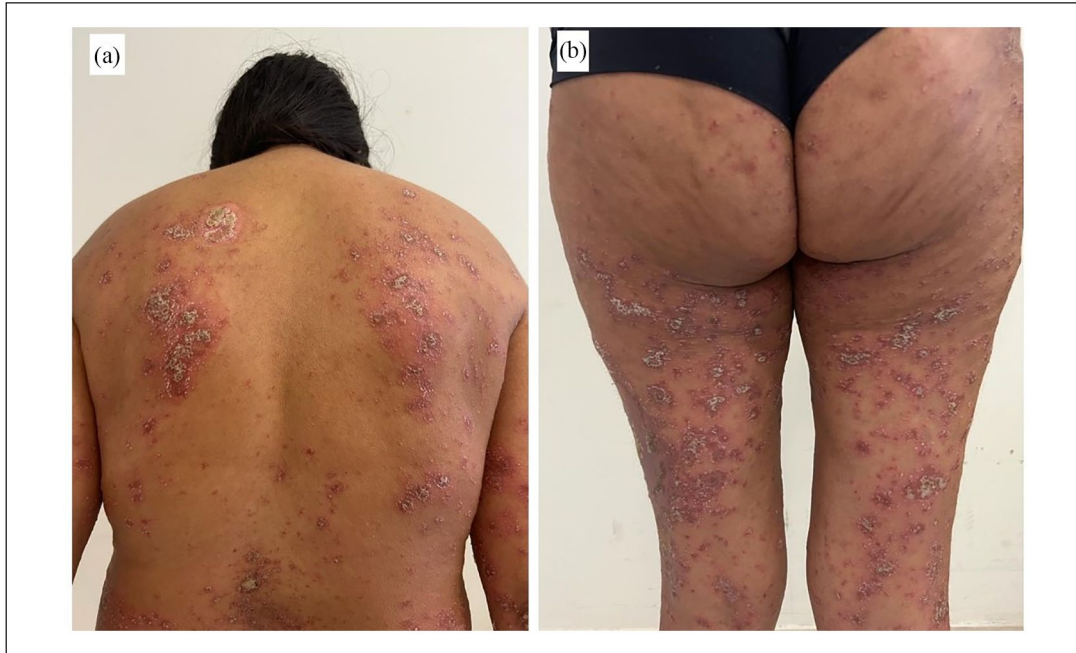


Figure 1. At baseline, large and multiple erythematous plaques covered by coalescent pustules are observed on the back (a) and on the limbs (b).

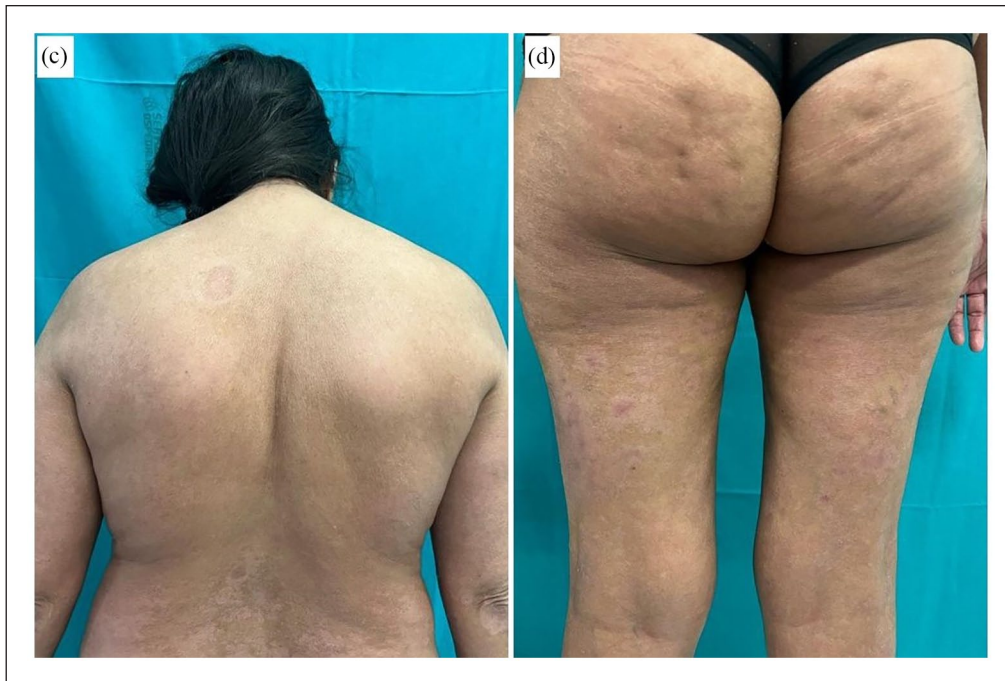

Figure 2. At 2 weeks after the first spesolimab dose, complete clearance of the erythematous plaques and pustules on the back (a) and on the limbs (b); some post-inflammatory sequelae persist.

patient also reported severe skin pain with a Numerical Rating Scale for Pain (pain NRS)=9/10. Some typical psoriasis plaques were also present on the trunk and lower limbs (PASI 6). In November 2022, spesolimab 900 mg was

administered intravenously in two doses, 1 week apart. Two weeks after the first dose, rapid and almost complete clearance of the lesions was observed (GPPGA=0.5; GPPASI=2.3, with pustulation sub-score=0; DLQI=1; pain

NRS=1/10) (Figure 2(a) and (b)). No adverse events were reported during or after the infusions. During the first 5-month follow-up, complete clinical remission was maintained for both GPP and plaque psoriasis. After 5 months, some lesions of plaque psoriasis re-occurred on the limbs (PASI=3). Consequently, secukinumab 300 mg was started, which achieved a complete clinical remission (PASI=0, GPPGA=0, GPPASI=0, DLQI=1) at 8-month follow-up.

Discussion

GPP can be a dermatological emergency and a life-threatening condition that poses multiple diagnostic and management challenges.¹² Its current treatment is often based on existing therapies for plaque psoriasis but with frequent unsatisfactory results, highlighting an unmet need for more specific and effective treatments.⁷ Spesolimab is the first molecule to specifically inhibit the IL-36 receptor and represents the first approved and specific therapy for GPP flare.³ The efficacy of spesolimab in managing the flare of GPP was shown first in the Effisayl-1 clinical trial showing that spesolimab induced a rapid and marked reduction of GPP severity.¹³ The rapid onset of action is consistent with what was observed in our case.

In addition, spesolimab was effective in improving the skin pain of the patient and its effectiveness was durable. In the Effisayl-2 study, about one-third of patients had a relapse of GPP-flare in the first 8 weeks after treatment.¹⁴ In our patient, a complete clinical remission of both plaque psoriasis and GPP was maintained for 5 months. Afterwards, there was a recurrence of psoriasis, for which we resumed therapy with secukinumab, which had been proven effective in the past for both plaque psoriasis and GPP.

To date, there are only a few cases in which the use of spesolimab has been described in a real-life context.^{15–17} The results are consistent with those observed in our case.

One limitation of our case is that we did not investigate the genetics of IL36-receptor antagonists in the patient, although spesolimab has shown to be effective independently from genetic mutations.¹³

Further studies are needed to better understand the durability of spesolimab-induced remission and its potential long-term effects. A recent trial confirmed that the administration of spesolimab subcutaneously is effective in preventing GPP flare.¹⁴

Declaration of conflicting interests

The author(s) declared the following potential conflicts of interest with respect to the research, authorship, and/or publication of this article: Paolo Gisondi has been consultant in advisory board and/or served as a speaker for AbbVie, Biogen, Ammirall, Eli Lilly, Janssen, LEO Pharma, Novartis, Pfizer, Pierre Fabre, Sanofi, and UCB Pharma; Giampiero Girolomoni has received personal fees from AbbVie, Ammirall, Amgen, Boehringer-Ingelheim, Bristol-Myers Squibb, Eli-Lilly, Leo Pharma, Merck Serono, Novartis, Pfizer,

Pierre Fabre, Samsung bioepis and Sanofi; Francesco Bellinato and Noemi Brigenti none declared.

Funding

The author(s) received no financial support for the research, authorship, and/or publication of this article.

Patient consent

The patient permitted the clinical case to be written up and for the photographs to be published. Data are available upon request to the corresponding author.

ORCID iD

Noemi Brigenti  <https://orcid.org/0009-0009-1884-8206>

References

1. Navarini AA, Burden AD, Capon F, et al. European consensus statement on phenotypes of pustular psoriasis. *J Eur Acad Dermatol Venereol* 2017; 31: 1792–1799.
2. Löfvendahl S, Norlin JM and Schmitt-Egenolf M. Prevalence and incidence of generalized pustular psoriasis in Sweden: a population-based register study. *Br J Dermatol* 2022; 186(6): 970–976.
3. Bachelez H, Choon SE, Marrakchi S, et al. Inhibition of the Interleukin-36 Pathway for the treatment of generalized pustular psoriasis. *N Engl J Med* 2019; 380(10): 981–983.
4. Marrakchi S and Puig L. Pathophysiology of Generalized Pustular Psoriasis. *Am J Clin Dermatol* 2022; 23(Suppl 1): 13–19.
5. Bellinato F, Gisondi P, Marzano AV, et al. Characteristics of patients experiencing a flare of generalized pustular psoriasis: a multicenter observational study. *Vaccines (Basel)* 2023; 11(4): 740.
6. Ryan TJ and Baker H. The prognosis of generalized pustular psoriasis. *Br J Dermatol* 1971; 85: 407–411.
7. Balato A, Ambrogio F, Burlando M, et al. Commentary: unmet needs in generalized pustular psoriasis in clinical practice. *Dermatol Ther (Heidelberg)* 2024; 14(1): 5–13.
8. Blair HA. Spesolimab: first approval [published correction appears in *Drugs*. 2023 Jan;83(1):103]. *Drugs* 2022; 82(17): 1681–1686.
9. European Medicines Agency approval of Spesolimab, <https://www.ema.europa.eu/en/medicines/human/EPAR/spevigo> (2023, accessed 5 December 2023).
10. Burden AD, Bachelez H, Choon SE, et al. The Generalized Pustular Psoriasis Physician Global Assessment (GPPGA) score: online assessment and validation study of a specific measure of GPP disease activity. *Br J Dermatol* 2023; 189(1): 138–140.
11. Burden AD, Bissonnette R, Lebwohl MG, et al. Psychometric validation of the generalized pustular psoriasis physician global assessment (GPPGA) and generalized pustular psoriasis area and severity index (GPPASI). *J Eur Acad Dermatol Venereol* 2023; 37(7): 1327–1335.
12. Choon SE, Lebwohl MG, Turki H, et al. Clinical characteristics and outcomes of generalized pustular psoriasis flares. *Dermatology* 2023; 239(3): 345–354.

13. Bachelez H, Choon SE, Marrakchi S, et al. Trial of spesolimab for generalized pustular psoriasis. *N Engl J Med* 2021; 385(26): 2431–2440.
14. Morita A, Strober B, Burden AD, et al. Efficacy and safety of subcutaneous spesolimab for the prevention of generalised pustular psoriasis flares (Effisayil 2): an international, multicentre, randomised, placebo-controlled trial. *Lancet* 2023; 402(10412): 1541–1551.
15. Müller VL and Kreuter A. Remission einer therapierefraktären generalisierten pustulösen Psoriasis unter dem Interleukin-36-Rezeptor-Inhibitor Spesolimab [Remission of recalcitrant generalized pustular psoriasis under interleukin-36 receptor inhibitor spesolimab]. *Dermatologie (Heidelb)* 2023; 74(5): 356–359.
16. Guénin SH, Khattri S and Lebwohl MG. Spesolimab use in treatment of pyoderma gangrenosum. *JAAD Case Rep* 2023; 34: 18–22.
17. Cardenas-de la Garza JA, Zazueta-López RM, Garza-Elizondo AK, et al. Spesolimab treatment in a patient with generalized pustular psoriasis: a case report with 12-month follow-up and literature review. *Clin Exp Dermatol* 2023; 49(3): 286–288.