



Article

Fixation of Posterior Malleolus in Trimalleolar Ankle Fractures: Anteroposterior Screw or Posterolateral Plate?

Paolo Ceccarini, Marco Donantoni, Federico Milazzo, Vito Prezioso, Rosario Petruccelli, Elena Manuela Samaila, Daniele Marcolli, Massimiliano Leigheb, Giuseppe Rinonapoli and Auro Caraffa

Special Issue

Orthopedic Trauma and Fractures: From Pathophysiology to Novel Therapeutic Approaches



Edited by

Dr. Giuseppe Rinonapoli and Dr. Paolo Ceccarini



Article

Fixation of Posterior Malleolus in Trimalleolar Ankle Fractures: Anteroposterior Screw or Posterolateral Plate?

Paolo Ceccarini ¹, Marco Donantoni ^{1,*}, Federico Milazzo ², Vito Prezioso ², Rosario Petruccelli ¹, Elena Manuela Samaila ³ , Daniele Marcolli ⁴, Massimiliano Leigheb ⁵ , Giuseppe Rinonapoli ¹ and Auro Caraffa ¹

¹ Orthopedic and Traumatology Unit, University of Perugia, “Santa Maria della Misericordia” Hospital, P.le G. Menghini 3, 06156 Perugia, Italy; rosario.petruccelli@ospedale.perugia.it (R.P.); giuseppe.rinonapoli@ospedale.perugia.it (G.R.); auro.caraffa@ospedale.unipg.it (A.C.)

² Orthopaedics and Traumatology Unit, “M. Bufalini” Hospital, Viale Giovanni Ghirelli 286, 47521 Cesena, Italy; milazzofederico@gmail.com (F.M.); vitoprezioso78@gmail.com (V.P.)

³ Department of Orthopedics and Trauma Surgery, University of Verona, Surgical Center “P. Confortini”, P.le A. Stefani, 1, 37126 Verona, Italy; elenamanuela.samaila@univr.it

⁴ Orthopaedics and Traumatology Unit, “G. Pini” University Hospital, P.za Cardinale Andrea Ferrari 1, 20122 Milano, Italy; dott.danielemarcolli@gmail.com

⁵ San Gaudenzio Clinic, Policlinic of Monza s.p.a., Via Bottini 3, 28100 Novara, Italy; massimiliano.leigheb@gmail.com

* Correspondence: marco.donantoni@gmail.com

Abstract: Background: The treatment of the third malleolus has evolved in recent years, and surgical treatment can be carried out with traditional percutaneous osteosynthesis using anteroposterior screws or ORIF with a posterolateral plate. Methods: Our study included 54 patients divided into two groups based on the intervention type (screw or plate). Instrumental assessments comprised pre- and post-operative X-rays and pre-operative CT scans to evaluate joint step-off. The mean follow-up duration was 1 year and 9 months. Results: Radiographic control revealed no loss of reduction or mobilization of the synthesis devices, and all patients achieved fracture healing. Articular step-off > 2 mm was observed in 21 patients (38.9%), including 4 in the plate group and 17 in the screw group, with a statistically significant likelihood of step-off presence in the latter. The mean AOFAS score was 90 points, negatively correlated with age, and lower in patients with joint step-off and a 15° reduction in ROM. Conclusions: The management of posterior malleolus fractures has changed with anatomical studies and an understanding of ankle stability through CT scans. ORIF with a posterior plate is advantageous for anatomical reduction of the tibial plafond but is disadvantageous in terms of surgical invasiveness and technical difficulty.

Keywords: ankle surgery; trimalleolar fractures; posterior malleolus; posterolateral approach; percutaneous screw fixation; technique comparison; classification; mini-invasive



Citation: Ceccarini, P.; Donantoni, M.; Milazzo, F.; Prezioso, V.; Petruccelli, R.; Samaila, E.M.; Marcolli, D.; Leigheb, M.; Rinonapoli, G.; Caraffa, A. Fixation of Posterior Malleolus in Trimalleolar Ankle Fractures: Anteroposterior Screw or Posterolateral Plate? *Appl. Sci.* **2024**, *14*, 802. <https://doi.org/10.3390/app14020802>

Academic Editor: Rossella Bedini

Received: 29 November 2023

Revised: 6 January 2024

Accepted: 15 January 2024

Published: 17 January 2024



Copyright: © 2024 by the authors. Licensee MDPI, Basel, Switzerland. This article is an open access article distributed under the terms and conditions of the Creative Commons Attribution (CC BY) license (<https://creativecommons.org/licenses/by/4.0/>).

1. Introduction

Ankle fractures represent the fourth most frequent injury treated by orthopedic surgeons, with an annual incidence of approximately 187 cases per 100,000 individuals [1,2] constituting the second most common lower limb fractures after proximal femoral fractures. The distribution is bimodal, with a peak in young adult males and another in elderly women with an average incidence age of 45 years [3]. The term “posterior malleolus” was introduced in 1911 by Destot [4] and it was Henderson in 1932 who began discussing trimalleolar fractures [5]. Trimalleolar fractures constitute 10–15% of all malleolar fractures and are associated with a worse prognosis and a higher risk of post-traumatic osteoarthritis compared to bimalleolar fractures [6]. In ankle fractures, involvement of the posterior malleolus ranges from 7 to 44% [3,7] and is usually due to rotational trauma with detachment of a fragment due to the force exerted by the posterior-inferior tibiofibular ligament (PITFL). The size of the fractured fragment varies widely, from a small extra-articular

fragment to one involving up to 40% of the tibial articular surface. Anatomical reduction in the case of an unstable joint is necessary to achieve satisfactory functional outcomes. The first studies reporting posterior malleolus osteosynthesis with screws date back to 1922 [8], when conservative approaches were more prevalent. However, over the years, inferior outcomes were observed with non-surgical treatment for larger fragments [9], establishing a critical threshold for surgical synthesis. For many decades, a posterior malleolus fracture involving more than 33% and later 25% of the articular surface indicated surgery [6,10,11], especially if accompanied by a step-off ≥ 2 mm in lateral X-rays [12,13]. The introduction of CT scans provided three-dimensional information (Figure 1) not only about fragment size and composition but also about the involvement of the fibular notch, tibial plafond impaction, intercalary fragments, and syndesmosis instability [14–18].

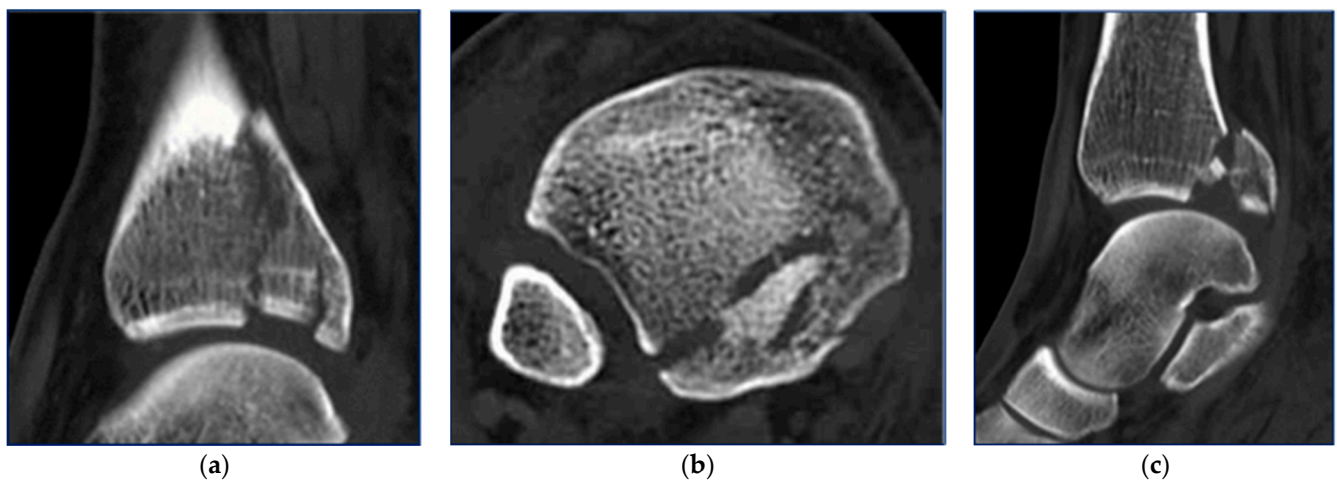


Figure 1. CT scan images of posterior malleolus fracture with plafond impaction (a), complex fracture margin, (b) and intercalary fragments (c).

These factors became considerations for the correct treatment of these fractures, altering the goals of surgical intervention.

The revised objectives are as follows [19,20]:

1. Restoration of the correct articular surface of the ankle joint.
2. PITFL reinsertion and restitution of syndesmotoc stability.
3. Reconstruction of the correct anatomy of the fibular notch, facilitating the reduction of the distal fibula.

Based on these considerations, CT-guided classifications were formulated, with notable ones being Haraguchi's and especially Bartonicek and Rammelt's [21]. Bartonicek's 2015 classification takes into account the three-dimensional aspects of the posterior fragment, including size, shape, fragment position, and integrity of the fibular notch [16,18,20,22–24].

Historically, posterior malleolus fractures were primarily treated with percutaneous anteroposterior screw fixation [25,26]. The rationale behind this technique is a minimally invasive treatment and the reduction of the posterior malleolus fracture through ligamentotaxis, an indirect reduction technique of a fracture fragment by acting on intact ligaments attached to the bony fragment. After fixing the lateral and medial malleoli, with the patient in a supine position, the posterior malleolus is synthesized using one or two screws, sized 3.5 mm/4.0 mm, from anterior to posterior percutaneously (Figure 2).

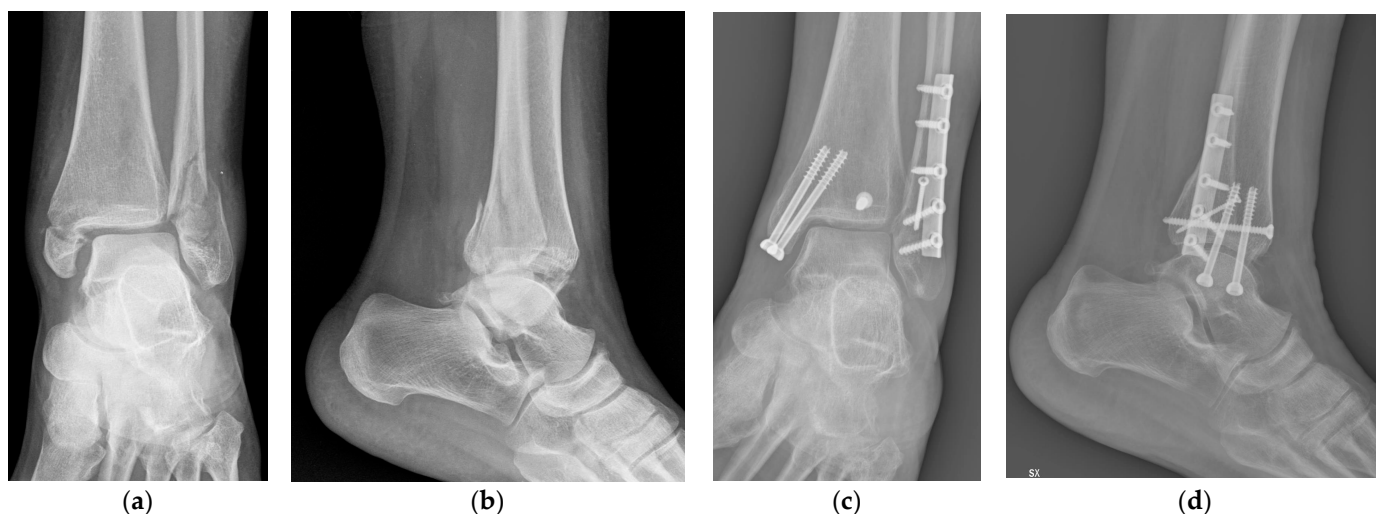


Figure 2. X-rays of trimalleolar ankle fracture in AP (a) and laterale views (b); post-operative X-rays of posterior malleolus fixation with percutaneous screw in AP (c) and laterale views (d).

This technique faces challenges in achieving adequate reduction, especially for ligamentotaxis, and has limitations in addressing interposed fragments [27–29].

Percutaneous approaches may also risk damage to the anterior tibial artery or nerve. The posterior approach has gained preference due to its ability to address fragment size, shape, and fracture line obliquity. It allows better visualization and reduction of the posterior malleolus, especially for cases involving interposed fragments [30,31]. The sequence of fixation for malleolar fractures is debated [31,32], but generally, fixation of the posterior malleolus is recommended first, followed by the medial or lateral malleolus [33].

The posterior approach is advantageous for cases with posterior subluxation, allowing stable fixation of even small fragments [34,35]. The approach is particularly important for maintaining syndesmotic integrity and restoring the fibular notch, crucial for better fracture prognosis [35,36]. In summary, the surgical treatment of trimalleolar fractures involving the posterior malleolus is a subject of growing interest. This retrospective study aimed to compare radiological and functional outcomes in patients treated with percutaneous anteroposterior screw fixation versus open posterolateral fixation with a plate.

Surgical Technique for Posterolateral ORIF with Plate

The patient is positioned prone or in lateral decubitus. A tourniquet is placed on the same side and activated just before starting the procedure. The incision on the skin is situated between the fibula medially and the Achilles tendon laterally. The sural nerve runs subcutaneously from medial to lateral, approximately 7–10 cm from the insertion of the Achilles tendon on the calcaneus. The peroneal muscle tendons are retracted laterally, and the flexor hallucis longus is elevated from the interosseous membrane and the posterior surface of the tibia. Deep dissection requires isolating and ligating collateral branches of the peroneal artery and vein that cross the tibia from lateral to medial (Figure 3).

The posterior malleolus is connected to the fibula by the posterior syndesmosis through the posterior-inferior tibiofibular ligament, typically preserved in these fractures. Surgical precautions must be taken to avoid any damage to this structure. If the posterior malleolus needs mobilization for joint surface inspection, it should be carried out from its medial edge, preserving the origin of the posterior-inferior tibiofibular ligament. Following careful debridement of the fracture, the reduction is achieved with slight traction and anterior foot push rather than only dorsal ankle flexion.

A pressor can aid in obtaining adequate reduction, confirmed by cortical congruence and lateral intensifier imaging. Provisional fixation is obtained with small Kirschner wires.

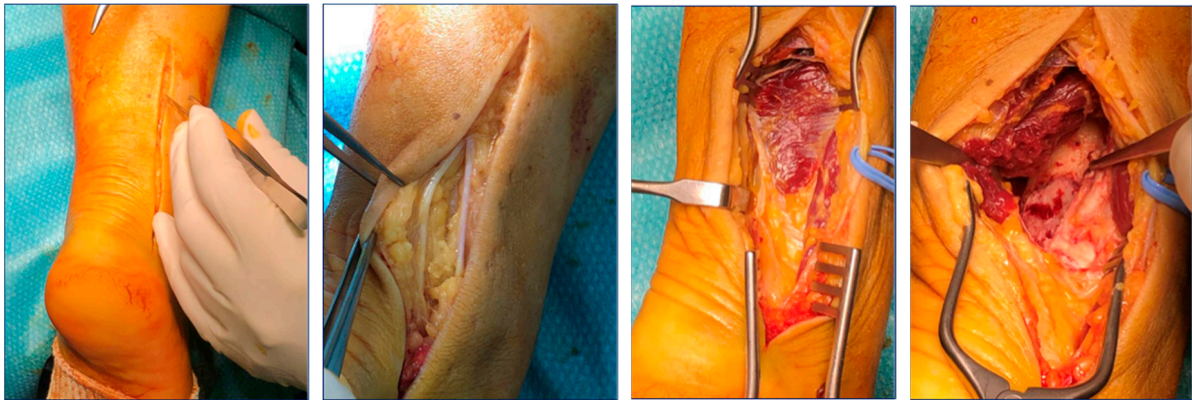


Figure 3. Posterior malleolus ORIF with plate: soft tissue dissection in posterolateral approach to the posterior malleolus.

After achieving an acceptable reduction, fixation can be performed with screws or as in our experience an antiglide plate (3.5 mm), depending on the morphology and size of the posterior fragment (Figure 4).

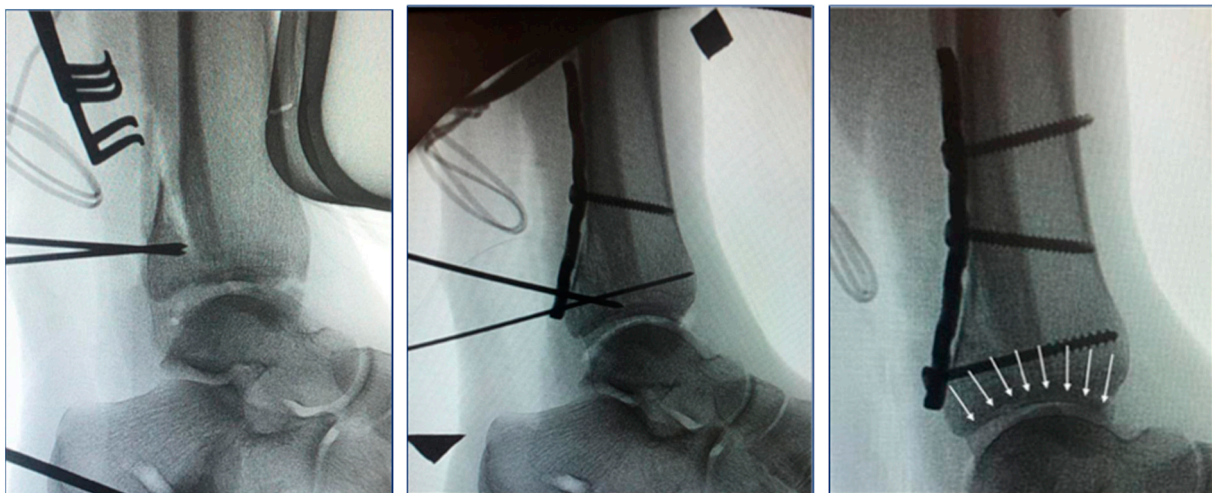

Figure 4. Intraoperative X-rays of posterior malleolus internal fixation with plate with articular surface correct reconstruction (white arrows).

Possible complications with the posterolateral approach include skin problems (especially if treating a fibular fracture with the same approach), wound infection, sural nerve neuropraxia, and complex regional pain syndrome. The complication rate is comparable to other ankle approaches.

2. Materials and Methods

From 1 January 2020 and 31 May 2022, patients surgically treated for trimalleolar fractures at the Santa Maria of Misericordia Hospital in Perugia and the “M. Bufalini” Hospital in Cesena were retrospectively evaluated. We searched the surgical databases of both hospitals (Ormaweb[®] for Perugia and Log80[®] for Cesena) for all the patients surgically treated for trimalleolar fracture. A total of 130 patients underwent surgery during the study period, with 95 treated at the Santa Maria of Misericordia Hospital in Perugia and 35 at the “M. Bufalini” Hospital in Cesena. Posterior malleolar osteosynthesis was performed in 81 patients.

The definitive osteosynthesis procedure was carried out only after the soft tissues were in suitable conditions. In 45 patients (34.61%), a temporary bridging external fixator was applied due to exposure, clear skin compromise, or severe instability.

The inclusion criteria were patients who underwent osteosynthesis of the third malleolus, aged over 18 years, with surgery performed at least in the previous 6 months, preoperative ankle CT, posterior malleolar fracture Type 2, 3, or 4 according to Bartonicek, and complete radiographic follow-up until fracture healing.

The exclusion criteria were patients requiring a posteromedial approach, open ankle fractures; previous ankle fractures; severe venous insufficiency; ankle osteoarthritis previous to surgery; and irreducible ankle dislocation.

All subjects gave their informed consent for inclusion before they participated in the study. This study was conducted in accordance with the Declaration of Helsinki.

2.1. Clinical Evaluation and Scores

Clinical evaluation of patients occurred using the American Orthopedic Foot and Ankle Society (AOFAS) ankle and hindfoot score [37] and range of motion (ROM) compared to the contralateral ankle, both at a mean follow-up of 1 year and 9 months.

2.2. Radiographics Evaluation and Measures

All the patients were assessed by pre- and post-operative X-rays and preoperative CT. The pre-operative X-rays were used to categorize patients according to the AO/OTA classification. The CT scans were used to classify patients according to the Bartonicek system. The post-operative X-rays were performed on the first day post-operatively (before discharge) and then at 30, 60, and 90 days, and at 6, 12, and 24 months, as per our standard follow-up to identify fracture healing and correct reduction, mobilization of osteosynthesis, and posterior malleolus articular surface step-off (significant if greater than 2 mm but less than 3 mm). We evaluate 12 or 24-month post-operative X-rays for our study follow-up.

2.3. Post-Operative Protocols and Rehabilitation

In the post-operative period, all ankles were protected with a brace for 3–4 weeks, to facilitate wound closure and healing.

2.4. Statistics

The database was collected using Microsoft Excel[®] software (16.43 version) and subsequently analyzed with R Software version 4.2.0. Statistical significance was set at $p < 0.05$. The performed statistical analysis aimed to

1. Highlight a potential association between the AOFAS score and other variables under consideration using non-parametric tests: Spearman's non-parametric correlation for the quantitative variable age, Mann–Whitney U-test for two-group comparisons (gender, group, and step-off), and Kruskal–Wallis H-test for comparisons involving more than two groups (AO/OTA, Bartonicek, ROM).
2. Evaluate whether the probability of joint step-off could be explained by age, gender, fracture type, or type of osteosynthesis, using logistic regression modeling.
3. Investigate the relationship between the reduction in joint mobility and other variables under consideration using ordered logistic regression modeling for polytomous variables.

3. Results

3.1. Demographic

Our study included 54 patients, consisting of 24 males (44.4%) and 30 females (55.6%), with a mean age of 59 years and a range from a minimum of 32 to a maximum of 83 years. They were treated with two different surgical approaches: 34 (63%) underwent third malleolus osteosynthesis with anteroposterior percutaneous screws, while 20 (37%) underwent plate fixation via a posterolateral approach (refer to Table 1).

Table 1. Data distribution of the variables observed in the sample.

		N	%
Sex	Male	24	44.4
	Female	30	55.6
AO/OTA	44 B 3.2	30	55.6
	44 B 3.3	18	33.3
	44 C 1.3	6	11.1
Bartonicek	2	28	51.9
	3	16	29.6
	4	10	18.5
Surgical Technique	A-P Screw	34	63
	P-L Plate	20	37

Surgical treatment for posterior malleolus was performed in 54 patients, including 30 women and 24 men, 34 with A-P screw, and 20 with P-L plate, with a median follow-up of 1 year and 9 months (minimum 12 months and maximum 24 months).

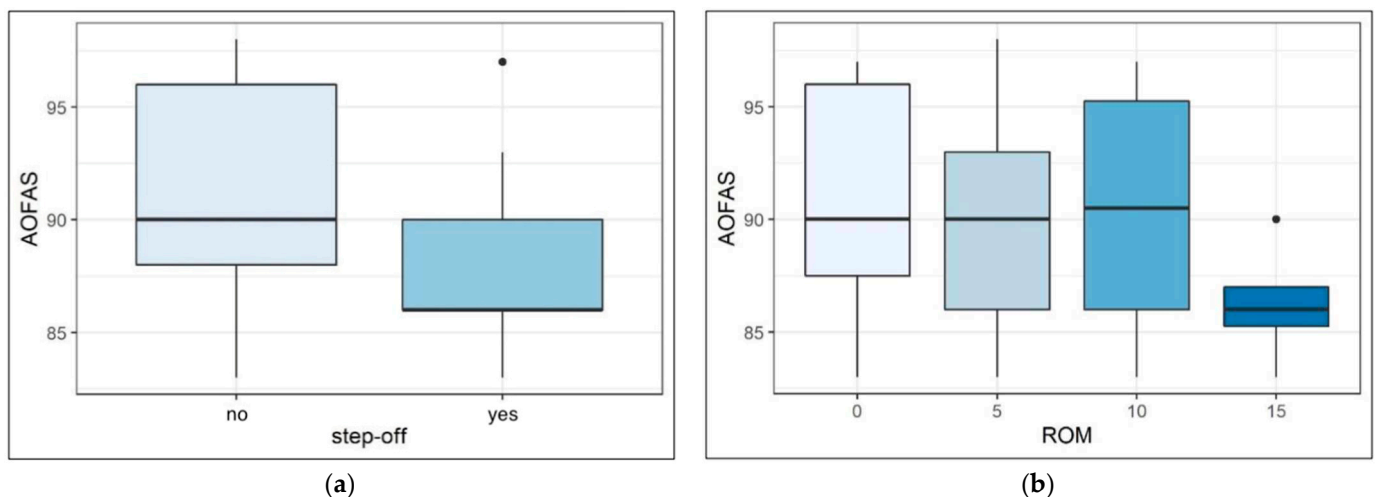
3.2. Clinical Results

3.2.1. AOFAS Score

The average AOFAS score was 90 points with a range from a minimum of 83 points to a maximum of 98 points.

AOFAS scores did not show a significant correlation with sex (U-test p value = 0.84), AO/OTA classification ($p = 0.57$), and surgical approach to posterior malleolus ($p = 0.22$).

The graphical representation of data regarding the association between AOFAS Score and articular step-off appears to suggest that lower scores are more frequently associated with the presence of articular step-off (Figure 5a), but the statistical significance for this relationship was not reached ($p = 0.07$). Similar considerations can be made regarding the association between AOFAS scores and a reduction in ROM $> 15^\circ$ compared to the contralateral ankle (Figure 5b), in this case with a p -value of 0.08.

**Figure 5.** AOFAS score correlation with articular step-off (a) and ROM reduction (b).

Bartonicek classification showed a correlation with AOFAS scores: the median score for type 2 was 93 points, for type 3 it was 90 points, and for type 4 it was 86 points, a significant difference according to the statistical test used ($p < 0.05$).

Age emerged as the only variable exhibiting a statistically significant correlation with worse AOFAS scores. In this case, the correlation is negative, meaning that as age increases, the score decreases, as indicated by Spearman's rank correlation coefficient of -0.56 , which is significantly different from zero with a p -value < 0.001 .

3.2.2. Range of Motion (ROM)

Most patients (40.8%) showed no reduction in joint mobility and only 7.4% exhibited a reduction in ROM of approximately 15°. As for AOFAS scores, age emerged as the only variable exhibiting a statistically significant correlation with ROM (Figure 6): an increase in age corresponds to poorer joint mobility.

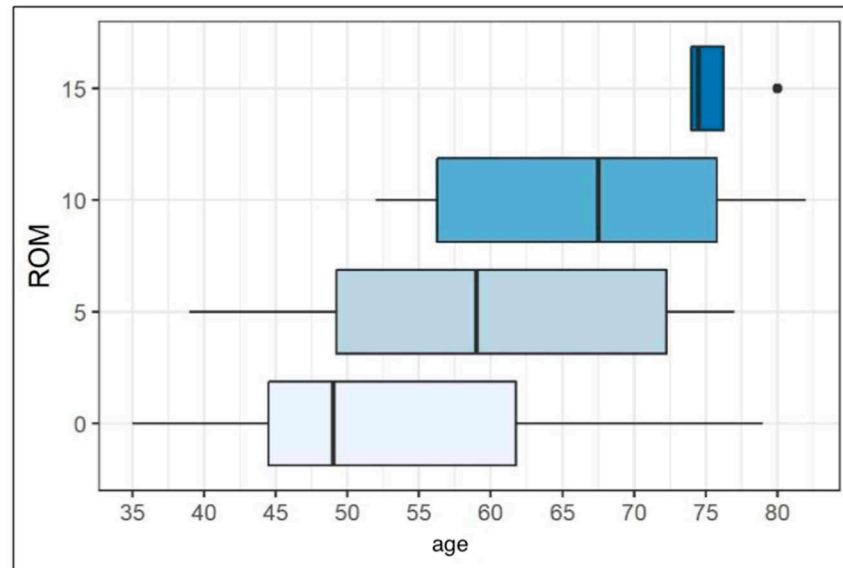


Figure 6. Age distribution based on range of motion (ROM) reduction.

3.3. Radiographic Results

Post-operative ankle X-rays in anteroposterior, lateral, and mortise projections were evaluated, showing fracture healing in all patients, with no loss of reduction or mobilization of fixation devices during the period of follow-up. In 38.9% of patients, a residual joint step-off at the third malleolus was observed, considered significant if greater than 2 mm but less than 3 mm. In these patients, the slight joint incongruence remained unchanged during the post-operative radiographic follow-up and represented the best achievable outcome at the time of surgical osteosynthesis.

Referring to our study, the presence of joint step-off compared to anatomical reduction for the screw group is four times higher than the plate group (Figure 7).

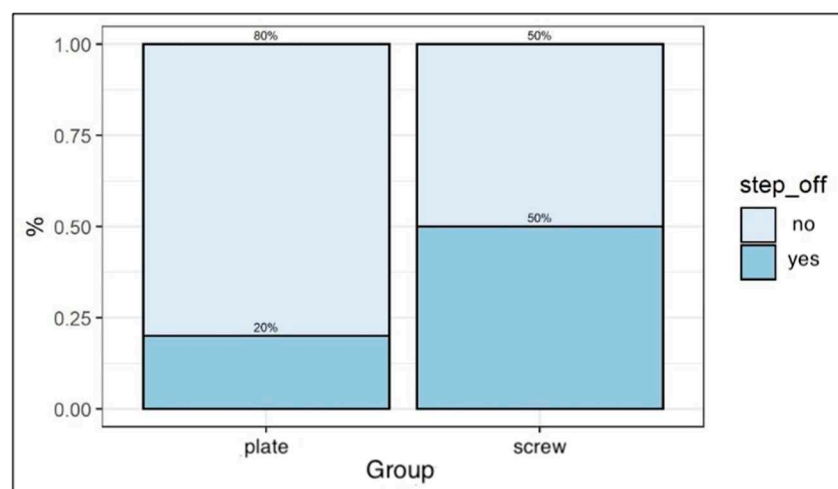


Figure 7. Percentage distribution of articular step-off based on the type of surgical osteosynthesis.

Specifically, for our patients, the probability of step-off for patients treated with anteroposterior percutaneous screws is 50%, while for those with posterior ORIF using a plate, it is 20%.

4. Discussion

In recent years, numerous studies have emphasized the critical importance of achieving an anatomical restoration of the articular surface in third malleolus fractures. Contrary to initial expectations, biomechanical studies on cadavers following posterior malleolus resection did not reveal a substantial increase in contact forces or joint instability. However, the prognosis for trimalleolar fractures, especially those involving the posterior malleolus, is associated with a less favorable prognosis, an elevated risk of post-traumatic osteoarthritis, and inferior functional outcomes compared to fractures excluding the posterior malleolus [38,39].

The presence of joint step-off has emerged as a crucial indicator for predicting osteoarthritis development, although its impact on functional outcomes remains a subject of debate [40–43]. The evolving consensus rejects reliance solely on dimensional criteria for the management of posterior malleolus fractures. Traditionally, surgical synthesis was indicated for fragments affecting over 25% of the articular surface. The recent literature, however, advocates synthesis for involvement as low as 5–10%, yielding superior clinical and radiographic results [40,42,44,45]. The third malleolus has assumed a pivotal role in trimalleolar fracture management. Nevertheless, controversies persist in defining precise indications for the correct surgical approach due to the absence of a standardized method for evaluating functional outcomes across various treatments [46].

In the current literature, there is broad consensus that the actual size and tridimensional geometry of the posterior malleolus fracture can only be diagnosed through preoperative CT examination. Sagittal and axial scans combined with 3D reconstruction can provide information for accurate classification and appropriate preoperative planning [47].

The advent of CT imaging has facilitated the introduction of classification systems like Bartonicek's [21]. These systems not only reveal factors unidentifiable with standard X-rays but also guide surgical treatment selection and suggest appropriate osteosynthesis types [48]. Historically, surgical synthesis of the third malleolus primarily involved percutaneous anteroposterior screws, a relatively straightforward and minimally invasive technique. However, challenges may arise in achieving proper anatomical reduction for small interposed fragments and synthesizing small, particularly displaced, fragments.

The open posterolateral approach to the third malleolus allows anatomical reduction for posterior and laterally extended fragments, with the possibility of reaching the lateral malleolus [49,50]. However, drawbacks include the need for a relatively extensive incision, longer operation times, and potential technical difficulties, including the risk of sural nerve damage. Skin healing difficulties for this approach are comparable to the direct lateral approach, while the infection rate ranges from 4–11% [44,51].

Few comparative studies exist on different approaches for posterior malleolus fracture surgical synthesis. Existing studies present comparable clinical and radiological outcomes between posterolateral and posteromedial approaches [52]. Our retrospective comparative study suggests that clinical evaluation, based on the AOFAS scale, is worse for older patients, likely due to lower functional demand and, consequently, less adherence to post-operative rehabilitation programs.

AOFAS scores were also lower for individuals with a joint step-off ≥ 2 mm, although our experience does not provide strong evidence to support this hypothesis, possibly due to the limited sample size. Results were compared between the group with anatomical reduction and the group with a joint step-off ≥ 2 mm. Statistical analysis confirmed better functional results in the group with anatomical reduction, regardless of the surgical technique performed. However, the comparison between the two groups based on the persistence of joint step-off yielded a borderline p -value (p -value = 0.07), not falling below the 5% significance level. However, the comparison between the two groups based on

the persistence of joint step-off yielded no differences. Nevertheless, those with a joint step-off achieved a lower AOFAS score than those without. This result needs confirmation from studies with a larger sample size, but it appears to validate that the posterior ORIF technique, enabling direct visualization and mastery of the posterior malleolus fragment, substantially enhances the surgical chances of achieving anatomical joint reduction, restoring the fibular notch, and providing stable anatomical syndesmosis fixation.

In our case series, post-operative joint incongruence (step-off ≥ 2 mm and <3 mm) at the third malleolus occurred in 50% of patients treated with screws, while in those treated with a plate, it was 20%. This difference aligns with the recent literature [50], indicating that posterolateral plate synthesis compared to the anteroposterior percutaneous screw technique increases the probability of achieving anatomical reduction and is associated with better clinical outcomes [53,54]. However, the association between joint step-off and better clinical outcomes in terms of AOFAS and ROM needs clarification. The posterolateral approach has shown superiority over anteroposterior percutaneous screws in several studies, but in the 2023 systematic review by Wang et al. [43], this was confirmed only for better radiographic restoration of correct anatomy. Superiority was not confirmed regarding AOFAS scores, osteoarthritis development, infections, and sural nerve damage.

Despite these limitations, our study suggests a fundamental contribution to improving outcomes, partly highlighted in our case series, due to the restoration of the fibular notch achieved through anatomical reduction of the posterior fragment and subsequent stabilization of the posterior-inferior tibiofibular ligament [55,56].

From our study and the recent scientific literature data, we believe that in treating trimalleolar fractures, the three fundamental objectives are the following:

1. Anatomical reconstruction of the tibial plafond.
2. Anatomic restitution of the fibular notch.
3. Anatomical stabilization of the syndesmosis.

These aspects need to be achieved for the surgeon to improve the outcomes of patients with trimalleolar fractures, forming the basis for selecting the correct treatment [57].

Study Limitations and Future Perspectives

Critically analyzing our study reveals limitations, including a small sample size (54 patients) and uneven distribution of patients treated with two different techniques. This limited statistical power prevents the definition of subsets with greater comparability, such as age. Moreover, the distribution of ages in the two groups was not homogeneous.

Other limitations of our study are a lack of post-operative CT analysis, lack of data about surgical times and complications, and surgeries performed by different surgeons in two different hospitals.

In our study, two entirely different techniques were compared, and the results are understandably linked to this aspect. An intriguing aspect would have been the inclusion of third malleolus osteosynthesis with percutaneous postero-anterior screws and open reduction and internal fixation (ORIF) via postero-medial approach. Unfortunately, the percutaneous posteroanterior screw osteosynthesis is not performed in the two hospitals, and the available data for ORIF via the posteromedial approach in our possession were too limited, potentially further compromising the obtained results.

The conduct of scientific studies that encompass larger case series involving all possible types of third malleolus osteosynthesis can provide a more in-depth understanding of which technique is optimal for each patient.

5. Conclusions

The treatment of posterior malleolus fractures has undergone a radical transformation in recent years. Anatomical studies and a more complete understanding of the pivotal functional role played by the posterior malleolus in maintaining ankle stability have prompted a more aggressive surgical approach for these fractures [58].

Starting from conservative treatment and progressing through percutaneous anteroposterior screw osteosynthesis, we have now come to assign a significant role to open osteosynthesis of the third malleolus via the posterolateral approach. However, indications for the use of posterior ankle approaches are still a subject of discussion in the literature.

Osteosynthesis of third malleolus fractures with ORIF using a posterolateral plate, compared to the technique with percutaneous anteroposterior screws, allows the surgeon to have greater control in achieving an anatomical restoration of the tibial plafond, the reconstruction of the fibular notch, and anatomical stabilization of the syndesmosis. It remains crucial to consider that the ORIF technique with a plate is disadvantageous in terms of surgical invasiveness, operation times, and technical difficulties.

Although posterior osteosynthesis of the third malleolus is gaining increasing interest in scientific literature, it remains a technique to be used in selected patients. Percutaneous osteosynthesis with anteroposterior screws still allows for excellent results, especially in Type 4 fractures according to Bartonicek, with a large fragment and without interposed fragments or joint depression.

Author Contributions: The conceptualization of this study was performed by F.M., P.C., G.R. and A.C. The collection of all data was performed by F.M. and R.P.; statistics validation was performed by F.M. and V.P.; the first version of the manuscript was written by M.D. and E.M.S.; writing—review and editing were performed by M.D., P.C., D.M. and M.L. All authors have read and agreed to the published version of the manuscript.

Funding: This research received no external funding.

Institutional Review Board Statement: All subjects gave their informed consent for inclusion before they participated in the study. This study was conducted in accordance with the Declaration of Helsinki.

Informed Consent Statement: Informed consent was obtained from all subjects involved in the study.

Data Availability Statement: The database utilized and examined in the course of the present study is accessible to all authors upon reasonable request. To guarantee the confidentiality of data and to avoid data loss or alteration, the data are restricted to authorized members only. Authorized members are Donantoni MD, Milazzo MD, Petruccelli MD, Rinonapoli MD Prof, and Caraffa MD Prof. All information about the patients included in our study is saved in our protected server, and database access is possible only through a password that regularly changes. Only the authors have the key to access. Paper material about the clinical and radiographic evaluation is stored in a closet in the office of Ceccarini MD.

Conflicts of Interest: The authors declare no conflict of interest.

Abbreviations

AP: anteroposterior; CT: computed tomography; ORIF: open reduction internal fixation; PITFL: posterior-inferior tibiofibular ligament.

References

1. Daly, P.J.; Fitzgerald, R.H.J.; Melton, L.J.; Ilstrup, D.M. Epidemiology of ankle fractures in Rochester, Minnesota. *Acta Orthop. Scand.* **1987**, *58*, 539–544. [[CrossRef](#)] [[PubMed](#)]
2. Garrett, W.E.J.; Swiontkowski, M.F.; Weinstein, J.N.; Callaghan, J.; Rosier, R.N.; Berry, D.J.; Harrast, J.; Derosa, G.P. American Board of Orthopaedic Surgery Practice of the Orthopaedic Surgeon: Part-II, certification examination case mix. *J. Bone Jt. Surg. Am.* **2006**, *88*, 660–667. [[CrossRef](#)]
3. Elsoe, R.; Ostgaard, S.E.; Larsen, P. Population-based epidemiology of 9767 ankle fractures. *Foot Ankle Surg. Off. J. Eur. Soc. Foot Ankle Surg.* **2018**, *24*, 34–39. [[CrossRef](#)] [[PubMed](#)]
4. Destot, E. *Traumatismes Du Pied et Rayons x: Malléoles, Astragale, Calcanéum, Avant-Pied*; Masson: Sainte-Hélène, France, 1911.
5. Henderson, M.S. Trimalleolar fracture of the ankle. *Surg. Clin. N. A.* **1932**, *12*, 867–872.
6. Hancock, M.J.; Herbert, R.D.; Stewart, M. Prediction of outcome after ankle fracture. *J. Orthop. Sports Phys. Ther.* **2005**, *35*, 786–792. [[CrossRef](#)] [[PubMed](#)]

7. Jaskulka, R.A.; Ittner, G.; Schedl, R. Fractures of the posterior tibial margin: Their role in the prognosis of malleolar fractures. *J. Trauma* **1989**, *29*, 1565–1570. [[CrossRef](#)]
8. Lounsbury, B.F.; Metz, A.R. Lipping fracture of lower articular end of tibia. *Arch. Surg.* **1922**, *5*, 678–690. [[CrossRef](#)]
9. Nelson, M.C.; Jensen, N.K. The treatment of trimalleolar fractures of the ankle. *Surg. Gynecol. Obs.* **1940**, *71*, 509–514.
10. Heim, D.; Niederhauser, K.; Simbrey, N. The Volkmann dogma: A retrospective, long-term, single-center study. *Eur. J. Trauma Emerg. Surg.* **2010**, *36*, 515–519. [[CrossRef](#)]
11. Heim, U. Indications and technic for the stabilization of the posterior Volkmann’s triangle in malleolar fractures. *Unfallheilkunde* **1982**, *85*, 388–394.
12. Weber, B.G. *Die Verletzungen des Oberen Sprunggelenkes. Aktuelle Probleme in der Chirurgie*; Published Online; Huber: Bern, Switzerland; Stuttgart, Germany, 1933.
13. Me, M.; Allgower, M.; Schneider, R.; Willenegger, H.; Perren, S.M. *Manual of Internal Fixation*; Published Online; Springer: Berlin/Heidelberg, Germany, 1991.
14. Verhage, S.M.; Boot, F.; Schipper, I.B.; Hoogendoorn, J.M. Open reduction and internal fixation of posterior malleolar fractures using the posterolateral approach. *Bone Jt. J.* **2016**, *98*, 812–817. [[CrossRef](#)] [[PubMed](#)]
15. Miller, A.N.; Carroll, E.A.; Parker, R.J.; Helfet, D.L.; Lorch, D.G. Posterior malleolar stabilization of syndesmotic injuries is equivalent to screw fixation. *Clin. Orthop. Relat. Res.* **2010**, *468*, 1129–1135. [[CrossRef](#)]
16. Gardner, M.J.; Brodsky, A.; Briggs, S.M.; Nielson, J.H.; Lorch, D.G. Fixation of posterior malleolar fractures provides greater syndesmotic stability. *Clin. Orthop. Relat. Res.* **2006**, *447*, 165–171. [[CrossRef](#)]
17. Klammer, G.; Kadakia, A.R.; Joos, D.A.; Seybold, J.D.; Espinosa, N. Posterior pilon fractures: A retrospective case series and proposed classification system. *Foot Ankle Int.* **2013**, *34*, 189–199. [[CrossRef](#)] [[PubMed](#)]
18. Mason, L.W.; Marlow, W.J.; Widnall, J.; Molloy, A.P. Pathoanatomy and associated injuries of posterior malleolus fracture of the ankle. *Foot Ankle Int.* **2017**, *38*, 1229–1235. [[CrossRef](#)]
19. Weber, M. Trimalleolar fractures with impaction of the posteromedial tibial plafond: Implications for talar stability. *Foot Ankle Int.* **2004**, *25*, 716–727. [[CrossRef](#)] [[PubMed](#)]
20. Bartoniček, J.; Rammelt, S.; Tuček, M. Posterior malleolar fractures: Changing concepts and recent developments. *Foot Ankle Clin.* **2017**, *22*, 125–145. [[CrossRef](#)] [[PubMed](#)]
21. Bartoniček, J.; Rammelt, S.; Kostlivý, K.; Vaněček, V.; Klika, D.; Trešl, I. Anatomy and classification of the posterior tibial fragment in ankle fractures. *Arch. Orthop. Trauma Surg.* **2015**, *135*, 505–516. [[CrossRef](#)]
22. Haraguchi, N.; Haruyama, H.; Toga, H.; Kato, F. Pathoanatomy of posterior malleolar fractures of the ankle. *JBJS* **2006**, *88*, 1085–1092. [[CrossRef](#)]
23. Sultan, F.; Zheng, X.; Pan, Z.; Zheng, Q.; Li, H.; Wang, J. Characteristics of intercalary fragment in posterior malleolus fractures. *Foot Ankle Surg.* **2020**, *26*, 289–294. [[CrossRef](#)]
24. Donken, C.; Goorden, A.J.F.; Verhofstad, M.H.J.; Edwards, M.J.; van Laarhoven, C. The outcome at 20 years of conservatively treated ‘isolated’ posterior malleolar fractures of the ankle: A case series. *J. Bone Jt. Surg. Br. Vol.* **2011**, *93*, 1621–1625. [[CrossRef](#)]
25. Odak, S.; Ahluwalia, R.; Unnikrishnan, P.; Hennessy, M.; Platt, S. Management of posterior malleolar fractures: A systematic review. *J. Foot Ankle Surg.* **2016**, *55*, 140–145. [[CrossRef](#)] [[PubMed](#)]
26. Verhage, S.M.; Hoogendoorn, J.M.; Krijnen, P.; Schipper, I.B. When and how to operate the posterior malleolus fragment in trimalleolar fractures: A systematic literature review. *Arch. Orthop. Trauma Surg.* **2018**, *138*, 1213–1222. [[CrossRef](#)]
27. Zhong, S.; Shen, L.; Zhao, J.; Chen, J.; Xie, J.; Shi, Q.; Wu, Y.; Zeng, X. Comparison of posteromedial versus posterolateral approach for posterior malleolus fixation in trimalleolar ankle fractures. *Orthop. Surg.* **2017**, *9*, 69–76. [[CrossRef](#)] [[PubMed](#)]
28. Duan, X.; Kadakia, A.R. Suppl-4, M14: Operative Treatment of Posterior Malleolar Fractures. *Open Orthop. J.* **2017**, *11*, 732. [[CrossRef](#)]
29. Evers, J.; Barz, L.; Wähnert, D.; Grüneweller, N.; Raschke, M.J.; Ochman, S. Size matters: The influence of the posterior fragment on patient outcomes in trimalleolar ankle fractures. *Injury* **2015**, *46*, S109–S113. [[CrossRef](#)]
30. Tenenbaum, S.; Shazar, N.; Bruck, N.; Bariteau, J. Posterior malleolus fractures. *Orthop. Clin.* **2017**, *48*, 81–89. [[CrossRef](#)] [[PubMed](#)]
31. Verhage, S.M.; Krijnen, P.; Schipper, I.B.; Hoogendoorn, J.M. Persistent postoperative step-off of the posterior malleolus leads to higher incidence of post-traumatic osteoarthritis in trimalleolar fractures. *Arch. Orthop. Trauma Surg.* **2019**, *139*, 323–329. [[CrossRef](#)]
32. Karim, A.; So, E.; Taylor, B.C.; Degenova, D.; Nace, W.C. Ankle fracture fixation: Medial or lateral first? *J. Foot Ankle Surg.* **2019**, *58*, 75–79. [[CrossRef](#)]
33. Heyes, G.J.; Khashkusha, T.R.; Mason, L. Posterolateral Approach to Posterior Malleolar Fractures: A Literature Review. *Foot Ankle Spec.* **2023**, *16*, 149–158. [[CrossRef](#)]
34. Branca Vergano, L.; Monesi, M.; Vicenti, G.; Bizzoca, D.; Solarino, G.; Moretti, B. Posterior approaches in malleolar fracture: When, why and how. *J. Biol. Regul. Homeost. Agents* **2020**, *34* (Suppl. 2), 89–95.
35. Miller, M.A.; McDonald, T.C.; Graves, M.L.; Spitler, C.A.; Russell, G.V.; Jones, L.C.; Replogle, W.; Wise, J.A.; Hydrick, J.; Bergin, P.F. Stability of the syndesmosis after posterior malleolar fracture fixation. *Foot Ankle Int.* **2018**, *39*, 99–104. [[CrossRef](#)]
36. Sagi, H.C.; Shah, A.R.; Sanders, R.W. The functional consequence of syndesmotic joint malreduction at a minimum 2-year follow-up. *J. Orthop. Trauma* **2012**, *26*, 439–443. [[CrossRef](#)] [[PubMed](#)]

37. Leigheb, M.; Janicka, P.; Andorno, S.; Marcuzzi, A.; Magnani, C.; Grassi, F. Italian translation, cultural adaptation and validation of the “American Orthopaedic Foot and Ankle Society’s (AOFAS) ankle-hindfoot scale”. *Acta Biomed.* **2016**, *87*, 38–45. [[PubMed](#)]
38. De Vries, J.S.; Wijnman, A.J.; Sierevelt, I.N.; Schaap, G.R. Long-term results of ankle fractures with a posterior malleolar fragment. *J. Foot Ankle Surg.* **2005**, *44*, 211–217. [[CrossRef](#)]
39. Day, G.A.; Swanson, C.E.; Hulcombe, B.G. Operative treatment of ankle fractures: A minimum ten-year follow-up. *Foot Ankle Int.* **2001**, *22*, 102–106. [[CrossRef](#)] [[PubMed](#)]
40. Xu, H.-L.; Li, X.; Zhang, D.-Y.; Fu, Z.-G.; Wang, T.-B.; Zhang, P.-X.; Jiang, B.-G.; Shen, H.-L.; Wang, G.; Wang, G.-L.; et al. A retrospective study of posterior malleolus fractures. *Int. Orthop.* **2012**, *36*, 1929–1936. [[CrossRef](#)] [[PubMed](#)]
41. Langenhuijsen, J.F.; Heetveld, M.J.; Ultee, J.M.; Steller, E.P.; Butzelaar, R.M.J.M. Results of ankle fractures with involvement of the posterior tibial margin. *J. Trauma Acute Care Surg.* **2002**, *53*, 55–60. [[CrossRef](#)]
42. Drijfhout van Hooff, C.C.; Verhage, S.M.; Hoogendoorn, J.M. Influence of fragment size and postoperative joint congruency on long-term outcome of posterior malleolar fractures. *Foot Ankle Int.* **2015**, *36*, 673–678. [[CrossRef](#)]
43. Wang, J.; Jia, H.-B.; Zhao, J.-G.; Wang, J.; Zeng, X.-T. Plate versus screws fixation for the posterior malleolar fragment in trimalleolar ankle fractures. *Injury* **2023**, *54*, 761–767. [[CrossRef](#)]
44. Shi, H.-F.; Xiong, J.; Chen, Y.-X.; Wang, J.-F.; Qiu, X.-S.; Huang, J.; Gui, X.-Y.; Wen, S.-Y.; Wang, Y.-H. Comparison of the direct and indirect reduction techniques during the surgical management of posterior malleolar fractures. *BMC Musculoskelet. Disord.* **2017**, *18*, 109. [[CrossRef](#)] [[PubMed](#)]
45. Huber, M.; Stutz, P.M.; Gerber, C. Open reduction and internal fixation of the posterior malleolus with a posterior antiglide plate using a postero-lateral approach—A preliminary report. *Foot Ankle Surg.* **1996**, *2*, 95–103. [[CrossRef](#)]
46. Egol, K.A.; Dolan, R.; Koval, K.J. Functional outcome of surgery for fractures of the ankle: A prospective, randomised comparison of management in a cast or a functional brace. *J. Bone Jt. Surg. Br. Vol.* **2000**, *82*, 246–249. [[CrossRef](#)]
47. De Marchi Neto, N.; Nesello, P.F.T.; Bergamasco, J.M.; Costa, M.T.; Christian, R.W.; Severino, N.R. Importance of computed tomography in posterior malleolar fractures: Added information to preoperative X-ray studies. *World J. Orthop.* **2023**, *14*, 868–877. [[CrossRef](#)] [[PubMed](#)]
48. Palmanovich, E.; Ohana, N.; Yaacobi, E.; Segal, D.; Iftach, H.; Sharfman, Z.T.; Vidra, M.; Atzmon, R. Preoperative planning and surgical technique for optimizing internal fixation of posterior malleolar fractures: CT versus standard radiographs. *J. Orthop. Surg. Res.* **2020**, *15*, 119. [[CrossRef](#)]
49. Talbot, M.; Steenblock, T.R.; Cole, P.A. Posterolateral approach for open reduction and internal fixation of trimalleolar ankle fractures. *Can. J. Surg.* **2005**, *48*, 487–490. [[PubMed](#)]
50. Tornetta, P., III; Ricci, W.; Nork, S.; Collinge, C.; Steen, B. The posterolateral approach to the tibia for displaced posterior malleolar injuries. *J. Orthop. Trauma* **2011**, *25*, 123–126. [[CrossRef](#)]
51. Berkes, M.B.; Little, M.T.; Lazaro, L.E.; Pardee, N.C.; Schottel, P.C.; Helfet, D.L.; Lorich, D.G. Articular congruity is associated with short-term clinical outcomes of operatively treated SER IV ankle fractures. *JBJS* **2013**, *95*, 1769–1775. [[CrossRef](#)]
52. Marinus, S.; Leijdesdorff, A.; Birgitta, I. The Foot Open reduction and internal fixation of the posterior malleolus fragment via the posterolateral approach is radiologically superior to ‘A to P’ screw fixation. *Foot* **2022**, *51*, 101894. [[CrossRef](#)]
53. Vidović, D.; Elabjer, E.; Muškardin, I.V.A.; Milosevic, M.; Bekic, M.; Bakota, B. Posterior fragment in ankle fractures: Anteroposterior vs posteroanterior fixation. *Injury* **2017**, *48*, S65–S69. [[CrossRef](#)]
54. O’Connor, T.J.; Mueller, B.; Ly, T.V.; Jacobson, A.R.; Nelson, E.R.; Cole, P.A. “A to p” screw versus posterolateral plate for posterior malleolus fixation in trimalleolar ankle fractures. *J. Orthop. Trauma* **2015**, *29*, e151–e156. [[CrossRef](#)] [[PubMed](#)]
55. Kalem, M.; Şahin, E.; Songür, M.; Keser, S.; Kinik, H. Comparison of three posterior malleolar fixation methods in trimalleolar ankle fractures. *Acta Orthop. Belg.* **2018**, *84*, 203–212. [[PubMed](#)]
56. Gardner, M.J.; Demetrakopoulos, D.; Briggs, S.M.; Helfet, D.L.; Lorich, D.G. Malreduction of the tibiofibular syndesmosis in ankle fractures. *Foot Ankle Int.* **2006**, *27*, 788–792. [[CrossRef](#)]
57. Fernández-Rojas, E.; Herrera-Pérez, M.; Vilá-Rico, J. Posterior malleolar fractures: Indications and surgical approaches. *Rev. Esp. Cir. Ortop. Traumatol.* **2023**, *67*, 160–169. [[CrossRef](#)] [[PubMed](#)]
58. Miksch, R.C.; Herterich, V.; Barg, A.; Böcker, W.; Polzer, H.; Baumbach, S.F. Open Reduction and Internal Fixation of the Posterior Malleolus Fragment in Ankle Fractures Improves the Patient-Rated Outcome: A Systematic Review. *Foot Ankle Int.* **2023**, *44*, 727–737. [[CrossRef](#)] [[PubMed](#)]

Disclaimer/Publisher’s Note: The statements, opinions and data contained in all publications are solely those of the individual author(s) and contributor(s) and not of MDPI and/or the editor(s). MDPI and/or the editor(s) disclaim responsibility for any injury to people or property resulting from any ideas, methods, instructions or products referred to in the content.