applied sciences

MDPI

Article

Precision of Composite Restoration Removal When Using a Dental Operating Microscope for the First Time: An Exploratory Volumetric Study

Marius Bud [1], Andra Solea [1], Lucia Dumitrascu-Timis [1,*], Francesca Zotti [2], Ada Delean [1] and Sanda Cîmpean [1]

[1] Department of Conservative Odontology, Faculty of Dentistry, Iuliu Haţieganu University of Medicine and Pharmacy, 400347 Cluj-Napoca, Romania
[2] Department of Surgery, Dentistry, Paediatrics and Gynaecology, University of Verona, 37134 Verona, Italy
* Correspondence: timis.lucia@elearn.umfcluj.ro

Abstract

Magnification is widely recommended to improve precision when defective composite restorations are removed, but it is unclear whether this benefit is available to an operator using a microscope for the first time. This exploratory in vitro study quantified the effect of a dental operating microscope on the volumetric accuracy and consistency of composite removal performed by a novice. Forty-four extracted human mandibular molars each received one standardised cervical Class V cavity ($3 \times 2 \times 1$ mm), restored with a nanohybrid composite. A single third-year dental student without clinical or magnification experience removed the restorations either under a dental operating microscope at the second magnification step ($n = 22$) or without magnification ($n = 22$). Cavity volume was determined before restoration and after removal by cone-beam computed tomography (0.12 mm voxel) and intraoral scanning. Mean volumetric change (ΔV) did not differ between groups (microscope 0.589 ± 1.239 mm^3; no magnification 0.807 ± 0.396 mm^3; $p = 0.44$), but its variance was almost ten times greater with the microscope ($p < 0.001$). For this operator at first use, magnification did not improve the accuracy of removal, as estimated by net volumetric change, and markedly reduced its consistency. These exploratory findings, obtained from a single operator, suggest that a structured introduction of magnification may be needed and should be tested in larger samples.

Keywords: dental operating microscope; magnification; composite restoration removal; precision direct restorations; novice operator; dental education; cone-beam computed tomography; intraoral scanning

Check for updates

Academic Editor: Eduardo Maximiliano Fernández-Godoy

Received: 23 October 2026
Revised: 19 November 2026
Accepted: 21 November 2026
Published: 24 November 2026

Copyright: © 2026 by the authors. Licensee MDPI, Basel, Switzerland. This article is an open access article distributed under the terms and conditions of the Creative Commons Attribution (CC BY) license.

1. Introduction

Replacement of defective direct restorations is one of the most frequent procedures in restorative dentistry, and each replacement tends to enlarge the cavity. Tooth-coloured composite is difficult to distinguish from enamel and dentin under conventional lighting, so removal often extends into sound tissue or leaves composite remnants behind [1,2]. The precision of removal therefore depends largely on how well the operator can see the composite–tooth interface.

Optical magnification is the most widely recommended aid for this task. Expert consensus lists the accurate replacement of existing restorations among the operative indications of the dental operating microscope (DOM) [3]. Magnification improves near visual acuity at clinical working distances [4,5], and loupes reduced enamel damage and composite

residues after removal of orthodontic adhesive [6]. However, the benefit of magnification for marginal sealing is less clear: in an in vitro comparison of occlusal layering techniques, composite restorations placed under the dental operating microscope did not show significantly lower microleakage than those placed with other techniques [7]. When crown preparations were refined under the microscope, marginal gaps were substantially smaller than after refinement with loupes [8].

Most of this evidence comes from operators who were already familiar with magnification. Studies in dental students are less consistent. Reviews report that loupes improve preparation performance in about two-thirds of comparisons, with posture benefiting more reliably than technical quality [9–11]. In a randomised crossover study, loupes improved the precision of a two-dimensional task but not of a three-dimensional preparation [12], whereas a recent pilot trial found that preclinical students performed best with the microscope [13]. Students without prior experience adopt a better posture with magnification but report an adjustment period, discomfort and difficulty mastering the device at first [14–16]. Lack of training during dental school is also one of the main reasons practising dentists do not use magnification [17].

The precision a novice achieves at the very first use of a microscope has not been measured objectively. This matters for curriculum design: if magnification improves precision immediately, it can be introduced directly into clinical tasks; if it does not, a structured adaptation phase is needed. Cone-beam computed tomography (CBCT) and intraoral scanning (IOS) allow volumetric quantification of small dental structures [18–20] and can measure how much tissue is removed during a restorative procedure.

The aim of this exploratory study was to determine whether a dental operating microscope improves the volumetric precision of composite restoration removal performed by a novice operator at first use. The null hypothesis was that the volumetric change in the cavity after composite removal would not differ between removal with and without magnification.

2. Materials and Methods

2.1. Study Design and Operator

This was an exploratory, randomised in vitro study. All procedures (cavity preparation, restoration, composite removal and volumetric measurement) were performed by a single operator, a third-year dental student with no previous clinical experience and no previous experience with loupes or an operating microscope. A single operator was chosen to remove inter-operator variability, so that the only systematic difference between groups was the visual condition during removal. The study workflow is summarised in Figure 1.

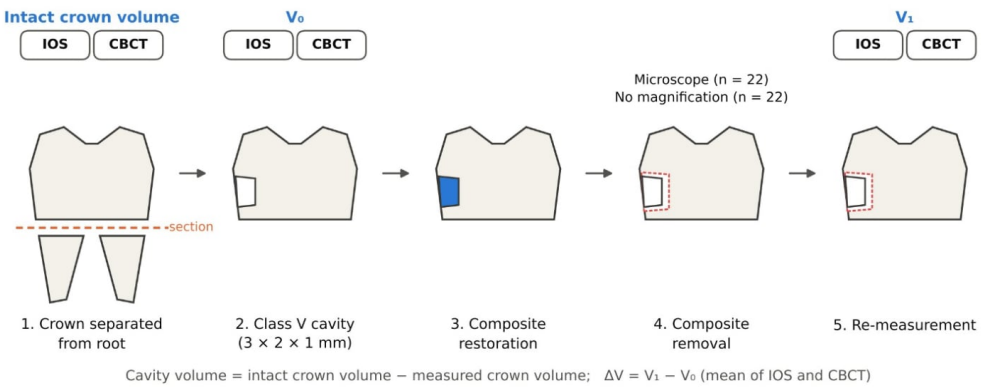

Figure 1. (1) The crown was separated from the root and its intact volume was recorded with intraoral scanning (IOS) and cone-beam computed tomography (CBCT). (2) A standardised cervical Class V

cavity (3 × 2 × 1 mm) was prepared and the crown was re-imaged to obtain the initial cavity volume (V_0). (3) The cavity was restored with composite. (4) The composite was removed under the dental operating microscope ($n = 22$) or without magnification ($n = 22$). (5) The crown was re-imaged to obtain the final cavity volume (V_1). Cavity volume was calculated as the intact crown volume minus the measured crown volume; $\Delta V = V_1 - V_0$, using the mean of the IOS and CBCT measurements. The dashed outline in steps 4 and 5 indicates possible enlargement of the cavity during removal.

2.2. Specimens and Cavity Preparation

Forty-four freshly extracted human mandibular molars were used. Each tooth received a single standardised Class V cavity on the buccal or oral cervical surface, for a total of 44 cavities. Cavities measured 3 mm mesiodistally, 2 mm occlusogingivally and 1 mm in depth and were prepared with a cylindrical diamond bur, 1 mm in diameter (Komet Dental (Gebr. Brasseler GmbH & Co. KG, Lemgo, Germany)), in a high-speed handpiece under water cooling, without magnification. Dimensions were checked with a periodontal probe during preparation. Because V_0 was measured volumetrically for each cavity and ΔV was calculated within the same cavity, small differences in initial cavity size did not affect the outcome. To simulate clinical working conditions as closely as possible, each sectioned crown was fixed on a stable support with a silicone-based adhesive, oriented along the long axis of the tooth in a position reproducing that of a mandibular molar in the patient's mouth; the adhesive allowed the crown to be detached for imaging and repositioned between steps. Cavity preparation, restoration and composite removal were all performed under indirect vision using a dental mirror (Figure 2).

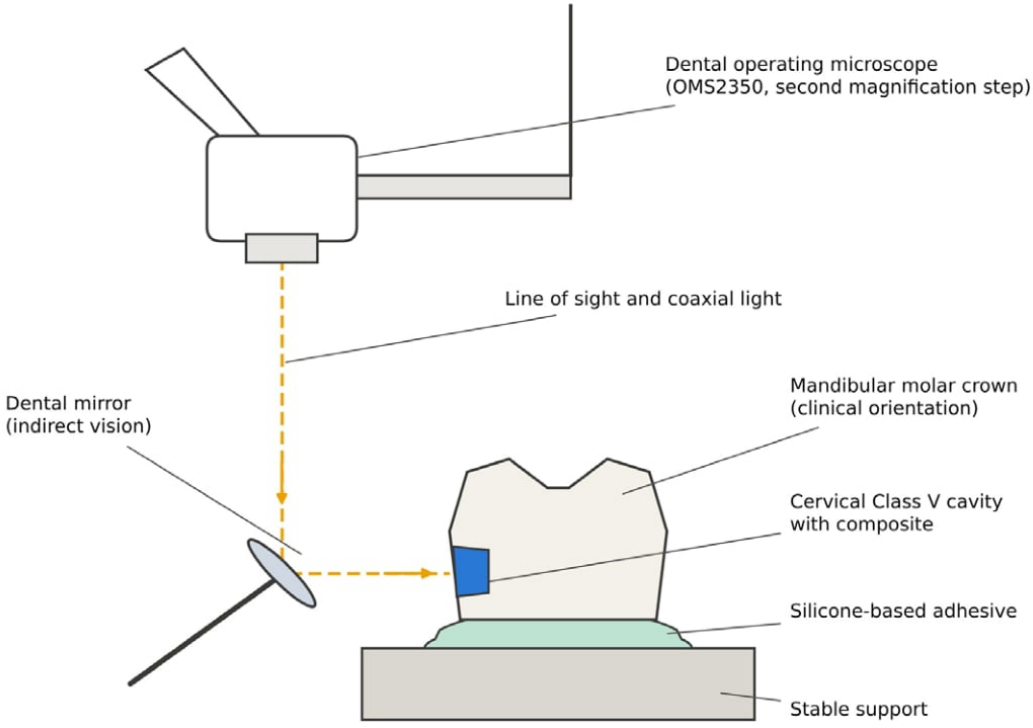

Figure 2. The sectioned mandibular molar crown was fixed with a silicone-based adhesive on a stable support in a clinical orientation. All procedures were performed under indirect vision with a dental mirror; in the microscope group, the dental operating microscope (OMS2350, second magnification step) was positioned above the mirror, and the line of sight and coaxial light reached the cervical Class V cavity through the mirror.

2.3. Restorative Procedure

Enamel was etched with 37% phosphoric acid gel (Ivoclar Vivadent AG, Schaan, Liechtenstein) for 30 s and dentin for 15 s, rinsed and gently dried. OptiBond FL (Kerr Corporation, Orange, CA, USA) was applied according to the manufacturer's instructions and light-cured. Cavities were restored in bulk with a light-cured nanohybrid composite (Evetric, Ivoclar Vivadent AG, Schaan, Liechtenstein) using LM-Arte instruments (LM-Instruments Oy, Parainen, Finland) and light-cured for 20 s.

2.4. Randomisation and Composite Removal

The 44 restored teeth were randomly allocated to two groups of 22 cavities each. As the specimens were similar and had no characteristics expected to influence the outcome, they were handed to the operator in random order, and the order of processing was not recorded. The two conditions were:

- **Group 1 (microscope):** composite removal using a dental operating microscope (OMS2350, Zumax Medical Co., Suzhou, China) at the second step of its six-step magnification changer (changer factor 0.5×; total magnification ≈4.25×). The second step was selected as an intermediate magnification suitable for a first-time user: it provides a sufficiently wide field of view and depth of field for orientation and instrument control, whereas higher steps progressively narrow the field and would have added difficulty unrelated to the aim of the study, which was to examine the working process under magnification at first use. The microscope was used in its standard configuration, without optional accessories such as a fluorescence filter, as this is the set-up most commonly available to students and practitioners.
- **Group 2 (control):** composite removal with the naked eye, without magnification, under indirect vision with a dental mirror, with the same operatory light and otherwise identical conditions.

Composite was removed with cylindrical diamond burs, 1 mm in diameter (Komet Dental, Gebr. Brasseler GmbH & Co. KG, Lemgo, Germany), of the same type and size in both groups; a new bur was used for each group, and because conditions were alternated specimen by specimen, bur wear was distributed equally between groups. Removal was considered complete when, on visual inspection, the operator judged that no composite remained in the cavity. Visual inspection is subjective and does not reliably distinguish over-removal of sound tooth structure from microscopic composite remnants; this limitation is likely to be greater for a student who is also using the microscope for the first time. This end-point was chosen because it reflects routine clinical practice. To avoid confounding the visual condition with learning or fatigue within the session, the two conditions were alternated specimen by specimen rather than performed in blocks. The operator had never used the microscope before the session. Immediately before the session, the operator received an explanation and a demonstration of the steps for adjusting the microscope image and then performed a correct adjustment independently under supervision.

2.5. Volumetric Measurement

Cavity volumes were determined by subtraction (Figure 1). For each tooth, the crown was separated from the root and its volume was measured intact. After cavity preparation the crown was measured again, and the initial cavity volume (V_0) was calculated as the difference between the two measurements. After composite removal the crown was measured a third time, and the final cavity volume (V_1) was calculated as the difference between the intact-crown volume and the post-removal volume.

The same subtraction procedure was applied with both imaging methods. Intraoral scans were obtained with a CEREC scanner (Dentsply Sirona, Bensheim, Germany) and

crown volumes were calculated in 3D Builder (20.0.3.0, Microsoft Corporation, Redmond, WA, USA). CBCT scans were acquired with a PaX-i3D unit (Vatech Co., Hwaseong, Republic of Korea) at an isotropic voxel size of 0.12 mm; datasets were processed in 3D Slicer (version 5.10.0; https://www.slicer.org, 25 September 2026) [21], where the crown was segmented and its volume calculated from the number and dimensions of the voxels. For each cavity, the CBCT- and IOS-derived volumes were averaged, and the mean of the two measurements was used for all analyses. At a voxel size of 0.12 mm, a single voxel corresponds to approximately 0.0017 mm^3, several hundred times smaller than the mean volumetric changes measured (0.6–0.8 mm^3). Because ΔV was calculated within the same cavity with the same method, systematic errors of each method were expected to cancel out, and averaging the two methods was intended to reduce random error. The method remains susceptible to measurement error, but it is realistic to apply in a preclinical setting.

2.6. Outcome Variable

For each cavity, volumetric change was calculated as $\Delta V = V_1 - V_0$ (mm^3). Positive values indicate a net increase and negative values a net decrease in cavity volume. Because ΔV is a net value, it cannot independently identify loss of tooth structure and retained composite within the same cavity; it was therefore used as a surrogate of removal accuracy rather than as a direct measure of it. ΔV was the primary outcome; values closer to zero indicate a smaller net change in cavity volume.

2.7. Statistical Analysis

The cavity was the unit of analysis ($n = 22$ per group). Descriptive statistics (mean ± standard deviation and standard error of the mean) were calculated for V_0, V_1, ΔV and the percentage change in cavity volume ($\Delta V/V_0 \times 100$). Equality of variances between groups was assessed with the F-test. Because variances differed, group means were compared with Welch's two-sample *t*-test; the equal-variance *t*-test gave the same conclusions. Within each group, the linear relationship between V_0 and V_1 was assessed with Pearson's correlation coefficient, and the two coefficients were compared using Fisher's r-to-z transformation. All tests were two-tailed with $\alpha = 0.05$. Data were organised in Microsoft Excel (Microsoft Corporation, Redmond, WA, USA).

3. Results

All 44 cavities were restored, removed and measured, and all were included in the analysis.

Initial cavity volumes were similar in the two groups (no magnification 5.773 ± 0.548 mm^3; microscope 5.637 ± 0.613 mm^3; $p = 0.44$). After removal, final volumes were 6.580 ± 0.740 mm^3 and 6.226 ± 1.211 mm^3, respectively ($p = 0.25$).

In both groups the cavity was, on average, larger after composite removal than before restoration. Mean ΔV was 0.807 ± 0.396 mm^3 (SEM 0.084) without magnification and 0.589 ± 1.239 mm^3 (SEM 0.264) with the microscope, corresponding to a mean increase in cavity volume of 13.95 ± 6.42% and 11.12 ± 21.59%. Mean ΔV did not differ significantly between groups (Welch's *t*-test, t = 0.79, $p = 0.44$), nor did the percentage change ($p = 0.56$). The mean difference (microscope minus no magnification) was −0.22 mm^3 (95% CI −0.79 to 0.35) for ΔV and −2.8% (95% CI −12.7 to 7.1) for the percentage change.

The variability in ΔV, however, differed markedly. The variance of ΔV was 9.8 times greater in the microscope group than in the control group ($F(21,21) = 9.79$; variance ratio 95% CI 4.1 to 23.6, $p < 0.001$), and the same applied to the percentage change ($p < 0.001$) (Figure 3).

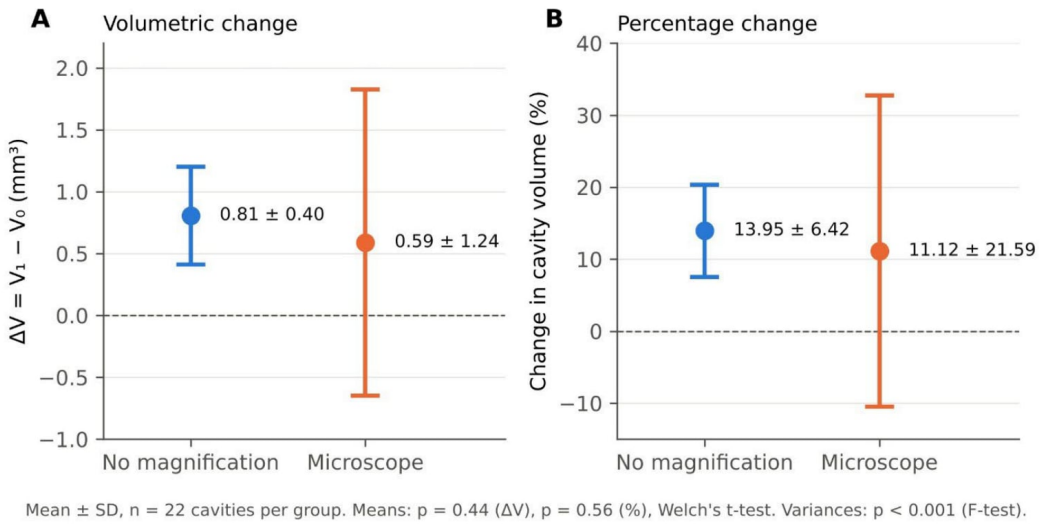

Figure 3. Volumetric change after composite removal with and without the dental operating microscope. (**A**) Volumetric change $\Delta V = V_1 - V_0$ (mm^3). (**B**) Percentage change in cavity volume. Points show the mean and whiskers the standard deviation ($n = 22$ cavities per group); the dashed line marks no change. Means did not differ between groups (Welch's *t*-test, $p = 0.44$ for ΔV and $p = 0.56$ for percentage change), whereas variances differed (F-test, $p < 0.001$).

Initial and final cavity volumes were not significantly correlated in the microscope group ($r = 0.151$, $p = 0.503$) and showed a moderate positive correlation in the control group ($r = 0.429$, $p = 0.046$). The difference between the two correlation coefficients was not statistically significant ($z = 0.95$, $p = 0.344$).

4. Discussion

This study measured how precisely a novice removed composite restorations at his or her first use of a dental operating microscope. The microscope did not improve the accuracy of removal, as estimated by net volumetric change: the mean volumetric change was similar with and without magnification. This absence of a significant difference should not, however, be interpreted as equivalence: the confidence interval of the difference was wide and does not exclude a relevant effect in either direction. It did, however, change the consistency of the result. Without magnification, almost every cavity showed a similar, small net enlargement; under the microscope, the outcome varied almost ten times more from one cavity to the next. For this operator at first use, magnification therefore made composite removal less predictable, which is the opposite of what is expected from studies of experienced users [3,8].

4.1. Why Magnification Did Not Help at First Use

The most plausible explanation is that the novice had not yet adapted to the device. At first use, the operator must manage a narrow field of view, a shallow depth of field, a fixed working distance and hand–eye coordination outside direct view, while also performing the task [3]. These demands compete with the task itself. Students without magnification experience report an adjustment period and initial difficulty in mastering the device [15,16]. In this situation, the visual gain offered by magnification may be offset by the cost of controlling the instrument in an unfamiliar visual field. In this study, all procedures were performed under indirect vision, so the operator had to coordinate a mirror image and a magnified image at the same time, a combination that demands hand–eye coordination the novice had not yet developed. Based on the markedly greater volumetric variability observed under the microscope (variance almost ten times higher than without magnification),

we hypothesise that, during the learning phase, coordination of hand movements while working in a dental mirror under magnification is still deficient, and that this unstable coordination, rather than a systematic error, may account for the inconsistent removal observed in the novice operator. In addition, ergonomic set-up was not standardised beyond the initial adjustment of the microscope. A novice has no established routine for positioning the specimen, the microscope and himself or herself, so small variations in posture and microscope alignment between specimens may have translated into variable instrument control. Both factors, ergonomic instability and mirror-assisted coordination under magnification, would be expected to increase variability rather than introduce a systematic bias, which is consistent with the pattern observed: similar means but markedly different variances. Under the microscope, each small change in posture or microscope position also shifted the magnified field, so that the operator had to re-establish orientation and mirror coordination for each specimen; without magnification, such variations had little effect on the view.

The loss of correlation between initial and final cavity volume under the microscope is consistent with this interpretation. Because $V_1 = V_0 + \Delta V$, V_1 follows V_0 only when the amount removed is relatively constant, as it was without magnification. Under the microscope, the variance of ΔV exceeded that of V_0 about fourfold, so the final volume reflected mainly the variable amount removed rather than the initial cavity size. As the difference between the two correlation coefficients was not statistically significant, this observation should be regarded as descriptive.

The nature of the task also matters. Removing composite from a cervical cavity is a three-dimensional task: the operator must judge depth and the position of the cavity walls, not only the surface outline. Loupes improved the precision of a two-dimensional task in undergraduates but not of a three-dimensional preparation [12] and did not improve the geometry of crown preparations [22]. In access cavities, the microscope improved outline form but not gouging or residual roof [23]. Our result is consistent with this pattern: a novice may see the margin better without being able to control depth better.

The operator subjectively reported better visibility of the restoration margins under the microscope, yet the measured result was less consistent. This discrepancy is educationally relevant. Students perceive magnification positively from the start [15], but perception is not a reliable indicator of performance during the first exposure.

4.2. Comparison with Other Studies

Our findings differ from a pilot trial in which preclinical students produced better crown preparations and provisional restorations with a microscope than with protective glasses [13]. Several differences may explain this. Students in that study had several semesters of preclinical training, the task was more extensive, and the outcome was a quality score rather than a volumetric measure. In addition, only a low magnification step was used in our study; studies with Galilean loupes suggest that moderate magnification (about 3×) gives the best balance between posture and preparation quality in students [24]. Posture improves almost immediately with magnification [14], whereas posture-related discomfort and neck angle continue to improve over the first weeks of use, partly through habituation [25]. Technical precision may follow a slower learning curve than posture. The ergonomic advantage of the microscope over loupes is measurable even in experienced users [26], and postural risk under magnification can be further reduced by short educational interventions [25,27]. In first-year postgraduate students, musculoskeletal risk also differed according to the magnification device used [28]. In contrast, objective data on how quickly technical precision improves with repeated use of the microscope remain scarce, and the present results suggest that this learning curve is longer than that for posture.

4.3. Over-Removal or Residual Composite?

Both groups enlarged the cavity on average, by about 14% without magnification and 11% with the microscope. This agrees with reports that conventional removal of tooth-coloured composite tends to remove sound tissue beyond the original cavity [1]. Without magnification, the small standard deviation indicates that the net enlargement was systematic and modest. Under the microscope, the standard deviation was larger than the mean, which indicates a wide dispersion of ΔV but does not by itself demonstrate that over-removal and residual composite were both present. In the control group, the mean ΔV was about twice its standard deviation, indicating a similar, moderate enlargement of virtually all cavities; in the microscope group, the standard deviation was about twice the mean, and the greater variance may be compatible with marked net enlargement in some cavities and little change, or possibly retained composite, in others; because individual cavity values were not analysed in this respect, this interpretation remains tentative. A reduction in volume after removal can only be explained by composite left in the cavity. Because the end-point of removal was the operator's visual judgement, residual composite cannot be excluded: visual inspection does not reliably distinguish composite from tooth structure at the cavity walls, and composite remnants are known to be difficult to detect without fluorescence aids, for students and experienced dentists alike [2]. Moreover, ΔV is a net value; over-removal of tooth structure in one area and residual composite in another area of the same cavity may partly cancel each other out, so the volumetric method cannot separate the two. Thus, a ΔV close to zero may also reflect over-enlargement of one wall compensated by composite left on another, a situation that may occur clinically as well, perhaps even more frequently. Future studies should report the sign of ΔV for each cavity and detect remnants directly, for example, with fluorescence-aided identification [2]. Optional microscope accessories, such as a fluorescence filter, might facilitate this task and reduce variability, but were deliberately not used here in order to reflect the standard configuration most commonly available.

4.4. Educational Implications

For the novice investigated here, the microscope was not an immediate aid to precision. Magnification may therefore need to be introduced in a structured way: first with set-up, focusing and hand–eye coordination exercises, then with simple two-dimensional tasks, and only later with clinical procedures that require depth control. A short training programme improved students' ergonomic compliance with loupes [25], and a step-by-step microscope course moving from planar to three-dimensional tasks improved students' knowledge and attitudes [29]. Our results, although limited to one operator, suggest that such training may need to precede, not follow, the use of magnification for precision tasks. Based on these studies and on our results, we suggest, as a hypothesis to be tested in future studies, a criterion-based programme in three stages: (1) set-up of the microscope, ergonomic positioning and focusing; (2) two-dimensional coordination exercises, first under direct and then under indirect vision; and (3) three-dimensional preclinical tasks, such as cavity preparation and restoration removal on models, with magnification increased progressively. Progression from one stage to the next should depend on reaching predefined performance criteria rather than on a fixed duration. Training in dental school is also associated with later use of magnification in practice [17]. Objective and reproducible assessment of students' preparations is feasible with simple measuring tools [30], and volumetric methods such as the one used here could complement such assessment.

4.5. Limitations

This study has some limitations. First, all procedures were performed by one operator, so the results describe a single novice's first exposure to the microscope and cannot be

generalised to novices as a group. Alternating conditions specimen by specimen reduced, but did not eliminate, the possibility of adaptation within the session. Because the order of processing was not recorded, the time course of performance within the session could not be analysed; any adaptation would, however, have affected both conditions similarly. Second, the sample (22 cavities per group) is modest and appropriate only for an exploratory study. Third, ergonomic set-up was not standardised, and all procedures were performed under indirect vision, which may have contributed to the variability observed under the microscope. Fourth, the end-point of removal was visual, and the volumetric method measures only the net change in cavity volume; it cannot distinguish over-removal of tooth structure from residual composite. Accordingly, ΔV reflects net volumetric change rather than removal accuracy as such. In addition, the periodontal probe used to check cavity dimensions has limited precision, and progressive bur wear within each group may have influenced cutting efficiency. The agreement between CBCT and IOS was not formally assessed (e.g., by Bland–Altman analysis or intraclass correlation), so the averaged volumes may combine measurement errors of different magnitude from the two methods. In addition, the F-test used to compare variances is sensitive to departures from normality, and the variance ratio should therefore be interpreted with caution. Fifth, the in vitro model does not reproduce clinical conditions such as rubber dam isolation, moisture and bleeding control, limited access, patient movement and time pressure; these factors would be expected to increase the difficulty of working under magnification, so the variability observed here is probably a conservative estimate. Sixth, only one, intermediate magnification level was tested; whether lower or higher steps would produce a different pattern of accuracy and consistency in a novice remains unknown. Future studies should include several novice operators, repeated sessions with counterbalanced magnification levels to describe the learning curve, standardised ergonomic set-up, direct detection of residual composite, assessment of the cavities after removal by independent, experienced observers, a protocol relating the operator's visual end-point to objective measurements, and three-dimensional superimposition of pre- and post-removal scans.

5. Conclusions

In this exploratory study, a dental operating microscope used for the first time by an untrained novice did not improve the accuracy of composite restoration removal, as estimated by net volumetric change: the mean volumetric change was similar with and without magnification. Under the microscope, however, the result was almost ten times more variable, so removal became less predictable for this operator. For this operator, the precision benefit of magnification was therefore not available at first use and may require prior training and adaptation. As a potential implication, magnification could be introduced into preclinical curricula progressively, with set-up and coordination exercises before precision-critical procedures; this should be tested in studies of structured training. Studies with multiple operators and repeated sessions are needed to describe the learning curve for precision under magnification.

Author Contributions: Conceptualization, S.C.; Methodology, M.B.; Software, A.S.; Validation, A.D.; Investigation, A.S.; Resources, S.C.; Writing—original draft, L.D.-T.; Project administration, L.D.-T. and F.Z. This study used only anonymised teeth extracted for clinical reasons and otherwise discarded, with no patient data collected. All authors have read and agreed to the published version of the manuscript.

Funding: This research received no external funding.

Institutional Review Board Statement: Not applicable.

Informed Consent Statement: Not applicable.

Data Availability Statement: The original contributions presented in this study are included in the article. Further inquiries can be directed to the corresponding author.

Conflicts of Interest: The authors declare no conflicts of interest.

References

1. Kiran, R.; Chapman, J.; Tennant, M.; Forrest, A.; Walsh, L.J. Fluorescence-aided selective removal of resin-based composite restorative materials: An in vitro comparative study. *J. Esthet. Restor. Dent.* **2020**, *32*, 310–316. [CrossRef] [PubMed]
2. Magni, E.; Leontiev, W.; Soliman, S.; Dettwiler, C.; Klein, C.; Krastl, G.; Weiger, R.; Connert, T. Accuracy of the Fluorescence-Aided Identification Technique (FIT) for Detecting Residual Composite Remnants after Trauma Splint Removal—A Laboratory Study. *Appl. Sci.* **2022**, *12*, 10054. [CrossRef]
3. Liu, B.; Zhou, X.; Yue, L.; Hou, B.; Yu, Q.; Fan, B.; Wei, X.; Qiu, L.; Huang, Z.; Xia, W.; et al. Experts consensus on the procedure of dental operative microscope in endodontics and operative dentistry. *Int. J. Oral Sci.* **2023**, *15*, 43. [CrossRef] [PubMed]
4. Perrin, P.; Neuhaus, K.W.; Lussi, A. The impact of loupes and microscopes on vision in endodontics. *Int. Endod. J.* **2014**, *47*, 425–429. [CrossRef] [PubMed]
5. Perrin, P.; Ramseyer, S.T.; Eichenberger, M.; Lussi, A. Visual acuity of dentists in their respective clinical conditions. *Clin. Oral Investig.* **2014**, *18*, 2055–2058. [CrossRef] [PubMed]
6. Baumann, D.F.; Brauchli, L.; van Waes, H. The influence of dental loupes on the quality of adhesive removal in orthodontic debonding. *J. Orofac. Orthop.* **2011**, *72*, 125–132. [CrossRef] [PubMed]
7. Bud, M.G.; Pop, R.C.; Pricope, R.; Mesaros, A.; Voina, A.; Delean, A.; Lucaciu, O.; Cimpean, S. Comparative microleakage outcomes of different techniques used for creating the occlusal anatomy in occlusal direct restorations using the dental operating microscope. *Clin. Exp. Dent. Res.* **2022**, *8*, 1623–1629. [CrossRef] [PubMed]
8. Atlas, A.; Janyavula, S.; Elsabee, R.; Alper, E.; Isleem, W.; Bergler, M.; Setzer, F. Comparison of loupes versus microscope-enhanced CAD-CAM crown preparations: A microcomputed tomography analysis of marginal gaps. *J. Prosthet. Dent.* **2024**, *131*, 643–651. [CrossRef] [PubMed]
9. de Oliveira, F.A.S.; Moraschini, V.; de Almeida, D.C.F.; dos Santos, G.O. Effects of magnification on restorative dental preparation performance: A scoping review and level of evidence mapping. *Clin. Oral Investig.* **2024**, *28*, 447. [CrossRef] [PubMed]
10. Costa, R.T.F.; Miranda, S.B.; Montes, M.A.J.R.; Ribeiro, A.K.C.; Carreiro, A.F.P.; Moraes, S.L.D. Impact of using magnifying dental loupes on clinical performance during tooth preparation: A systematic review. *J. Clin. Exp. Dent.* **2024**, *16*, e186–e197. [CrossRef] [PubMed]
11. Ramesh, A.; Guo, A.J.; Patel, H.J.; Huang, J.; Huang, C.-C.; Martins de Mello-Neto, J.; Rodrigues Amaral, R. The impact of magnification on undergraduate dental students' performance during cavity preparations: A systematic review. *J. Dent. Educ.* **2024**, *88*, 1091–1100. [CrossRef] [PubMed]
12. Eggmann, F.; Irani, D.R.; Fehlbaum, P.A.; Neuhaus, K.W. Do magnification loupes affect the precision of cavity preparations made by undergraduates? A randomized crossover study. *BMC Oral Health* **2022**, *22*, 189. [CrossRef] [PubMed]
13. Prause, E.; Rechlin, J.; Peroz, S.; Steinke, A.; von Stein-Lausnitz, M.; Beuer, F. Impact of dental loupes and operating microscopes on restorative performance of preclinical and clinical dental students: A pilot study. *BMC Med. Educ.* **2026**, *26*, 364. [CrossRef] [PubMed]
14. Bud, M.G.; Pricope, R.; Pop, R.C.; Onaca, R.; Swerts, P.-J.; Lucaciu, O.; Delean, A. Comparative analysis of preclinical dental students' working postures using dental loupes and dental operating microscope. *Eur. J. Dent. Educ.* **2021**, *25*, 516–523. [CrossRef] [PubMed]
15. Wajngarten, D.; Botta, A.C.; Garcia, P.P.N.S. Magnification loupes in dentistry: A qualitative study of dental students' perspectives. *Eur. J. Dent. Educ.* **2021**, *25*, 305–309. [CrossRef] [PubMed]
16. Abasseri, T.; Ha, W. Value of including loupes in prosthodontic and endodontic components of dental degrees: A systematic review. *Br. Dent. J.* **2023**, 1–7. [CrossRef] [PubMed]
17. Alghilan, M.A.; AlShehri, A.; Almeshrafi, A.; Alrumi, A.; Aldibasi, O. Decision-making factors among dentists for using dental magnifying loupes: A cross-sectional study. *Clin. Cosmet. Investig. Dent.* **2025**, *17*, 99–110. [CrossRef] [PubMed]
18. Kim, R.J.; Park, J.M.; Shim, J.S. Accuracy of 9 intraoral scanners for complete-arch image acquisition: A qualitative and quantitative evaluation. *J. Prosthet. Dent.* **2018**, *120*, 895–903.e1. [CrossRef] [PubMed]
19. Zimmermann, M.; Mehl, A.; Mörmann, W.H.; Reich, S. Intraoral scanning systems—A current overview. *Int. J. Comput. Dent.* **2015**, *18*, 101–129. [PubMed]
20. Yilmaz, F.; Sonmez, G.; Kamburoglu, K.; Ocak, M.; Celik, H.H. Accuracy of CBCT images in the volumetric assessment of residual root canal filling material: Effect of voxel size. *Niger. J. Clin. Pract.* **2019**, *22*, 1091–1098. [CrossRef] [PubMed]

21. Fedorov, A.; Beichel, R.; Kalpathy-Cramer, J.; Finet, J.; Fillion-Robin, J.-C.; Pujol, S.; Bauer, C.; Jennings, D.; Fennessy, F.; Sonka, M.; et al. 3D Slicer as an image computing platform for the Quantitative Imaging Network. *Magn. Reson. Imaging* **2012**, *30*, 1323–1341. [CrossRef]
22. Murbay, S.; Neelakantan, P.; Li, K.Y.; Pow, E.H.N. Effect of magnifying loupes on tooth preparation of complete coverage crown: A quantitative assessment using a digital approach. *Eur. J. Dent. Educ.* **2023**, *27*, 1053–1059. [CrossRef] [PubMed]
23. Almaslamani, M.; Mahmoud, O.; Ali, A.; Abdelmagied, M. Benefits of using magnification in access cavity preparation by undergraduate dental students: A micro-computed tomography study. *Eur. J. Dent. Educ.* **2026**, *30*, 77–86. [CrossRef] [PubMed]
24. Pazos, J.M.; Canonici, M.M.; Garcia, P.P.N.S. Effects of Galilean loupes on dental students' posture and cavity preparation quality. *Eur. J. Dent. Educ.* **2026**, *30*, 639–643. [CrossRef] [PubMed]
25. Pazos, J.M.; de Abreu Silva, J.K.; Garcia, P.P.N.S. Training program for the use of magnification loupes in dentistry. *Eur. J. Dent. Educ.* **2026**, *30*, 1316–1324. [CrossRef] [PubMed]
26. Hong, S.; Park, J.; Jeon, M.-J.; Shin, S.-J.; Park, J.H.; Park, J.-W. Effect of loupe and microscope on dentists' neck and shoulder muscle workload during crown preparation. *Sci. Rep.* **2024**, *14*, 17489. [CrossRef] [PubMed]
27. García Alcaide, A.; Conde Villar, A.J.; Pérez Alfayate, R.; Loroño, G.; Valencia De Pablo, O.; Estévez, R.; Aguilar Fernandez-Abellan, F.B.; Meza, M.S.; Adorno, C.G. Effect of an educational intervention on postural risk among endodontic residents under different magnification conditions. *Eur. J. Dent. Educ.* **2026**, 1–6. [CrossRef] [PubMed]
28. Tedone, M.; Adorno, C.G.; Ortiz-Hugues, J.C.; Conde Villar, A.J.; Pérez Alfayate, R.; Loroño, G.; Estévez, R.; Díaz-Flores, V.; Meza, M.S. Musculoskeletal risk of first-year postgraduate endodontic students using dental microscope, ergonomic loupes or no magnification. *Int. Endod. J.* **2026**, *59*, 1102–1109. [CrossRef] [PubMed]
29. Li, Z.; Yang, G.; Zhang, H.; Huang, C.; Liang, S. Undergraduate dental students' knowledge, attitudes, and satisfaction following a step-by-step course in microscopic dentistry. *BMC Med. Educ.* **2025**, *25*, 1376. [CrossRef] [PubMed]
30. Waligóra, J.; Ryniewicz, J.; Bereziewicz, W.; Bereziewicz, J.; Gajdzica, M.; Pytko-Polończyk, J. Quality of education and the evaluation of its outcomes in tooth preparation among dental students in Poland. *Dent. Med. Probl.* **2025**, *62*, 671–679. [CrossRef] [PubMed]

Disclaimer/Publisher's Note: The statements, opinions and data contained in all publications are solely those of the individual author(s) and contributor(s) and not of MDPI and/or the editor(s). MDPI and/or the editor(s) disclaim responsibility for any injury to people or property resulting from any ideas, methods, instructions or products referred to in the content.