



Contents lists available at ScienceDirect

European Journal of Medical Genetics

journal homepage: www.elsevier.com/locate/ejmg

SOX2: Not always eye malformations. Severe genital but no major ocular anomalies in a female patient with the recurrent c.70del20 variant

Edoardo Errichiello^{a,*}, Cristina Gorgone^b, Loretta Giuliano^c, Barbara Iadarola^d, Emanuela Cosentino^d, Marzia Rossato^d, Nehir Edibe Kurtas^a, Massimo Delledonne^d, Teresa Mattina^e, Orsetta Zuffardi^a

^a Department of Molecular Medicine, University of Pavia, Pavia, Italy

^b Speciality School of Medical Genetics, University of Catania, Catania, Italy

^c Department of Medical and Surgical Sciences and Advanced Technologies "G.F. Ingrassia", University of Catania, Catania, Italy

^d Department of Biotechnologies, University of Verona, Verona, Italy

^e Department of Biomedical and Biotechnological Sciences, University of Catania, Catania, Italy

ARTICLE INFO

Keywords:

SOX2
Anophthalmia/microphthalmia
Hypogonadotropic hypogonadism
Vaginal agenesis
Hypoplastic uterus
Undetectable ovaries

ABSTRACT

SOX2 variants have been identified in multiple patients with severe ocular anomalies and pituitary dysfunction, in addition to various systemic features.

We investigated a 26-year-old female patient suffering from spastic paraparesis, hypoplasia of corpus callosum, hypogonadotropic hypogonadism (HH) and intellectual disability, who was monitored for over 20 years, allowing a detailed genotype-phenotype correlation along time. Whole exome sequencing on the patient and her relatives identified a *de novo* SOX2 c.70del20 variant, which has been frequently reported in individuals with SOX2-related anophthalmia. Importantly, our patient lacked major ocular phenotype but showed vaginal agenesis, a feature never reported before. Although the involvement of male urogenital tract (cryptorchidism, hypospadias, small penis), is a well known consequence of SOX2 variants, their effect on the female genitalia has never been properly addressed, even considering the paradoxical female excess of SOX2 cases in the literature. Our findings emphasize the importance of testing for SOX2 variants in individuals with HH and genital anomalies even though anophthalmia or microphthalmia are not observed. Moreover, our case strengthens the role of SOX2 as a master regulator of female gonadal differentiation, as widely demonstrated for other SOX genes related to 46, XX sex reversal, such as SOX3 and SOX9.

1. Introduction

SOX2 (OMIM 206900), a SOX1B-HMG box transcription factor involved in early embryonic development with a critical role in eye, forebrain, and hypothalamo-pituitary development, has been shown to cause uni- and bilateral anophthalmia/microphthalmia (A/M) as well as related disorders such as anophthalmia/esophageal-genital syndrome (AEG) or A/M and esophageal atresia (AMEA). In addition, SOX2 variants are associated with a wide range of extra-ocular manifestations: intrauterine growth restriction, postnatal growth retardation, male hypogonadism, hypogonadotropic hypogonadism (HH), hypoplasia of the corpus callosum, seizures, sensorineural hearing loss, learning disability with speech delay, spastic diplegia/quadruplegia, vertebral and dental anomalies (Fantes et al., 2003; Williamson et al., 2006; Kelberman et al., 2008; Schneider et al., 2009; Numakura et al.,

2010; Chacon-Camacho et al., 20015). Aside from the infrequent mosaic cases, SOX2-positive cases without or only with minor eye phenotypes have been very rarely reported (Dennert et al., 2017).

Surprisingly, the intra-familial recurrence of deleterious SOX2 variants is extremely infrequent. One explanation might be the occurrence of genital tract abnormalities, plausibly related to reduced hypothalamic-pituitary-gonadal axis hormones, or direct effect of SOX2 haploinsufficiency on the germ cells (Bakrania et al., 2007). In the mouse, Sox2 is expressed in both male and female genitalia, and Sox2 heterozygotes show male (but not female) reduced fertility, associated with testicular abnormalities, diminished epididymal sperm count and motility (Avilion et al., 2003; Kelberman et al., 2006). In keeping with these findings, SOX2 gonosomal mosaicism has been specifically detected in the maternal samples (Faivre et al., 2006; Chassaing et al., 2007; Schneider et al., 2008), suggesting that female gametogenesis is

* Corresponding author. Department of Molecular Medicine, University of Pavia, Via Forlanini 14, 27100, Pavia, Italy.
E-mail address: edoardo.errichiello01@universitadipavia.it (E. Errichiello).

<https://doi.org/10.1016/j.ejmg.2018.01.011>

Received 2 October 2017; Received in revised form 29 November 2017; Accepted 19 January 2018
1769-7212/ © 2018 Elsevier Masson SAS. All rights reserved.

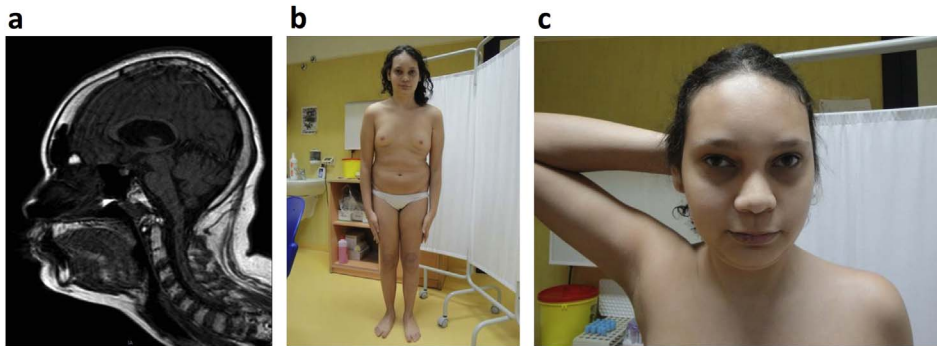


Fig. 1. Clinical features of the 26-year-old proband. (a) Brain MRI showing atrophy of corpus callosum. (b) Patient's picture showing large chest, widely spaced nipples, and thin lower limbs. (c) Facial dysmorphisms: high forehead and frontal hairline, wide sparse eyebrows, upslanted palpebral fissures, hypertelorism, squint, long filtrum, thin upper lip.

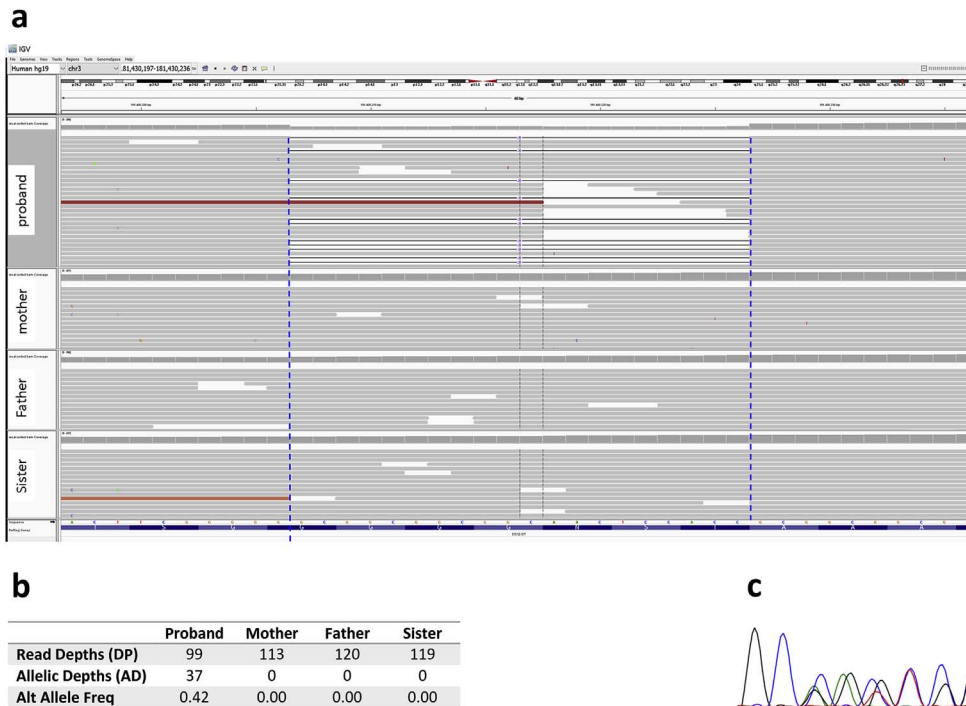


Fig. 2. WES analysis in the family. (a) IGV (Integrative Genomics View) visualization of the *SOX2* c.70del20 variant in the patient and relatives. The deletion's boundaries are delimited by dashed blue lines. (b) Read depths (DP), Allelic Depths (AD) and Mutation Allelic Fraction (Alt Allele Freq) of the *SOX2* variant. (c) Sanger sequencing validation, showing the heterozygous frameshifting alteration. (For interpretation of the references to colour in this figure legend, the reader is referred to the Web version of this article.)

more tolerant of reduced *SOX2* dosage than is spermatogenesis.

The involvement of male urogenital tract (cryptorchidism, hypospadias and micropenis) is a well known consequence of *SOX2* variants in humans (Fantes et al., 2003; Williamson et al., 2006; Kelberman et al., 2006; Bakrania et al., 2007). Nevertheless, their effect on female genitalia has never been properly addressed, although slight female excess of *SOX2* cases have been reported in the literature.

We studied a female patient with a *SOX2* variant showing severe genital anomalies, HH, spastic paraparesis, but no major ocular phenotype. We also provided an extensive revision of *SOX2* patients carrying the recurrent c.70del20 variant with a specific focus on females showing similarly rare genital anomalies.

1.1. Clinical report

The patient, a 26-year-old woman, was diagnosed with focal frontal lobe epilepsy, spastic paraparesis and HH. She is second child of healthy non-consanguineous parents, born after uneventful pregnancy. Family history was unremarkable. At birth, weight was 3100 g and length 50 cm (50th centile). During infancy, speech development was normal, while motor development was delayed. Hypertonia of the lower limbs was diagnosed when she was 18 months and she is presently wheelchair due to spastic gait. At the age of 20, she manifested stereotyped episodes characterized by deviation of the eyes to the right followed by

sudden loss of consciousness with reduction of muscle tone and traumatic falls. Video-EEG revealed no abnormalities, while brain MRI showed normal pituitary gland, corpus callosum hypoplasia and agenesis of the septum pellucidum (Fig. 1a). Neurological examination revealed dysarthria, spastic-ataxic gait, spasticity of the upper and lower limbs, and intellectual disability. At the last anthropometric evaluation, weight was 57.6 Kg (50-75th centile), height 158 cm (25th centile), head circumference 53 cm (25th centile), and arm span 166 cm (45th centile). Physical examination detected various facial dysmorphisms: high forehead and frontal hairline, wide sparse eyebrows, upslanted palpebral fissures, hypertelorism, wide nasal bridge, long filtrum, thin upper lip, large ears. Curiously, she had two supernumerary teeth with persistence of deciduous central lower incisors. In addition, we observed large chest, widely spaced nipples, thin lower limbs, cervical lordosis, truncal obesity and flat feet (Fig. 1b and c). Cardiological evaluation (ECG, echo, Holter) did not identify anomalies. Endocrinological and gynecological assessment revealed primary amenorrhea and oedematous labia, while abdominal ultrasounds detected vaginal agenesis, hypoplastic uterus, and rudimentary gonads. At the last hormonal evaluation, FSH was 0.2 mUI/ml, LH 0.1 mUI/ml, oestradiol < 5.0 pg/ml, and testosterone 0.003 mg/ml; TSH, FT3, FT4 and PRL were in the normal range. Ophthalmological examination revealed hypermetropia of +1.25D sphere in the right eye and +0.75D sphere in the left eye, and only minor ocular alterations: bilateral

Table 1
Summary of major clinical features in patients with the c.70del20 SOX2 variant.

Reference	Age	Sex	Origin	Growth	A/M	Neurological anomalies	Brain malformations	Dysmorphisms
Zenteno et al., 2005	11 m	F	Mexican	HC < 3rd centile	Bilateral anophthalmia	Motor delay	Partial CCA, ventriculomegaly, suprasellar cyst	Frontal bossing, large nose
Zenteno et al., 2006 Twin A	37 wog	M	Mexican	SGA	Left anophthalmia			Flat nasal bridge, retrognathia, low set ears, irregular skull
Zenteno et al., 2006 Twin B	37 wog	M	Mexican	SGA				
Kelberman et al., 2006 Patient 2	22 y	F			Left anophthalmia, right microphthalmia	Motor delay, learning disability	Hippocampal anomalies, pituitary hypoplasia	
Bakrania et al., 2007 Case 3	49 m	F		Postnatal growth failure	Right microphthalmia, left anterior segment dysgenesis and coloboma	Motor delay, ID, speech delay		
Bakrania et al., 2007 Case 5	5 m	F			Bilateral anophthalmia			
Kelberman et al., 2008 Patient 3	14.5 y	F		Postnatal short stature	Bilateral anophthalmia		Suprasellar arachnoid cyst	
Schneider et al., 2009 Patient 2	27 m	F	Hispanic	Postnatal growth failure	Bilateral microphthalmia	Motor delay, GDD, speech delay	Hamartoma of the tuber cinereum	
Schneider et al., 2009 Patient 3	9 y	M	Hispanic	Postnatal growth failure	Bilateral anophthalmia	Motor delay, GDD, ASD		Microcephaly, slightly cupped ears, mild dolicocephaly, lateral flaring of the eyebrows, widely-spaced central incisors
Schneider et al., 2009 Patient 4	8 y	M	Caucasian		Bilateral anophthalmia	Hypotonia, GDD, verbal apraxia, seizures		Low-set prominent ears
Reis et al., 2010 Patient 1		M	African American		Right microphthalmia and optic nerve hypoplasia	GDD		
Osborne et al., 2011 Case 22		F			Bilateral anophthalmia			
Gerth-Kahlert et al., 2013 Patient 3432	3 y	M	German		Right anophthalmia	Motor delay, speech delay	Cavum vergae	
Gerth-Kahlert et al., 2013 Patient 3433	27.5 y	F	German		Left anophthalmia	Spastic gait, speech delay		
Suzuki et al., 2014 Case 3	1 y	F		Postnatal growth failure	Bilateral anophthalmia		Hamartoma	
Chacon-Camacho et al., 2015	2 y	M	Mexican	Postnatal growth failure	Left anophthalmia, right microphthalmia	Motor delay, GDD, speech delay	Pituitary hypoplasia	Plagiocephaly, tall forehead, frontal bossing, underdeveloped supraorbital ridges, prominent antihelices, microstomia, dental anomalies

(continued on next page)

Table 1 (continued)

Reference	Age	Sex	Origin	Growth	A/M	Neurological anomalies	Brain malformations	Dysmorphisms
Ramirez-Botero and Pachajoa, 2016 Present study	4 y 26 y	M F	Colombian Italian	Postnatal growth failure	Bilateral microphthalmia	Motor delay, speech delay Motor delay, spastic paraparesis, ID, focal frontal lobe epilepsy	CCA CCA, agenesis of the septum pellucidum	High forehead and frontal hairline, wide sparse eyebrows, upslanted palpebral fissures, hypertelorism, wide nasal bridge, longiltrum, thin upper lip, large ears, supernumerary teeth
Overall frequency				10/18 (56%)	16/18 (89%)	12/18 (67%)	9/18 (50%)	6/18 (33%)
Reference	Genital anomalies	Renal anomalies	Endocrine dysfunction	Skeletal anomalies	Cardiovascular anomalies	Gastrointestinal anomalies	Inheritance	
Zenteno et al., 2005 Zenteno et al., 2006 Twin A Zenteno et al., 2006 Twin B Kelberman et al., 2006 Patient 2 Bakrania et al., 2007 Case 3 Bakrania et al., 2007 Case 5 Kelberman et al., 2008 Patient 3 Schneider et al., 2009 Patient 2 Schneider et al., 2009 Patient 3 Schneider et al., 2009 Patient 4 Reis et al., 2010 Patient 1 Osborne et al., 2011 Case 22 Gerth-Kahlert et al., 2013 Patient 3432 Gerth-Kahlert et al., 2013 Patient 3433 Suzuki et al., 2014 Case 3	Bilateral cryptorchidism Tiny uterus no identifiable ovaries Horseshoe kidney	HH HH	Hip dislocation Slipped right femoral epiphysis Pectus excavatum, 2-3 toes syndactyly	Esophageal atresia Esophageal atresia Esophageal atresia	De novo De novo De novo De novo De novo Maternal (mosaic) De novo De novo De novo Maternal (patient 3433) De novo De novo			

(continued on next page)

Table 1 (continued)

Reference	Genital anomalies	Renal anomalies	Endocrine dysfunction	Skeletal anomalies	Cardiovascular anomalies	Gastrointestinal anomalies	Inheritance
Chacon-Camacho et al., 2015	Bifid and hypopigmented scrotum, micropenis						<i>De novo</i>
Ramirez-Botero and Pachajoa, 2016	Hypoplastic testicles, micropenis					Esophageal stenosis	
Present study	Vaginal agenesis, hypoplastic uterus, ovarian agenesis		HH, obesity	Cervical lordosis, flat feet, large chest			<i>De novo</i>
Overall frequency	8/18 (44%)	1/18 (6%)	3/18 (17%)	4/18 (22%)	1/18 (6%)	5/18 (28%)	

ASD: Autism spectrum disorder; CCA: corpus callosum agenesis; GDD: Global developmental delay; HC: head circumference; HH: Hypogonadotropic hypogonadism; ID: intellectual disability; SGA: Small for gestational age; wog: weeks of gestation.

microexotropia, mild corio-retinal dystrophy, and small vitreous retinal retraction of the left eye.

Written informed consent was obtained in accordance with the institutional review boards of the University of Catania Ethics Committee.

2. Results

Karyotype revealed a normal 46, XX chromosomal pattern, while no pathogenic CNVs were detected by the array-CGH. After an inconclusive preliminary screening of genes commonly associated with spastic paraparesis (*SPG4*, *SPG3A*) and HH (*KAL1*, *FGFR1*, *PROK2*, *PROKR2*), whole exome sequencing (WES) was performed on DNA extracted from peripheral blood samples of the proband and her relatives. The analysis identified the recurrent NM_003106.3(*SOX2*):c.70_89del20 frameshift variant (also known as c.70del20) in the proband's DNA. This deletion predicts a p. Asn24fs*65 mutation upstream of the High Mobility Group (HMG) box and loss of the majority of the protein, including the DNA-binding HMG and C-terminal transactivation domains. The variant was not detected in both parents and older healthy sister, indicating its *de novo* origin (Fig. 2). The c.70del20 variant is unreported in ExAC, ESP, GoNL, 2000 Danes WES (Diabetes Type 2 Study), and HGVD, while it is recorded in dbSNP149 (#rs398123693), HGMD (#CD054424) and ClinVar (#RCV000359617.1), and was previously described in 17 patients from different ethnic groups (Table 1). WES failed to identify variants in other genes commonly associated with HH or hereditary spastic paraplegia (Supplementary Tables 1 and 2).

3. Discussion

The c.70del20 is the most common *SOX2* variant, accounting for up to 20% of individuals with *SOX2*-related anophthalmia (Schneider et al., 2009; Reis et al., 2010). It has been previously shown that it generates a truncated protein lacking the DNA-binding HMG domain and nuclear localization signals, thereby causing abnormal nuclear transport of the mutant protein and inability to activate transcription of different DNA targets (e.g. the promoter of *HESX1*) required for the normal development of forebrain, eyes, olfactory placodes and pituitary gland (Kelberman et al., 2006). The ocular phenotype in patients carrying the c.70del20 variant usually include uni- or bilateral A/M, with only very rare exceptions (Zenteno et al., 2006). Importantly, genital anomalies (diagnosed in approximately 30% of cases) were exclusively reported in male patients and included short penis, cryptorchidism, foreskin adhesions and bifid scrotum. To our knowledge, this is the first report of a patient carrying the c.70del20 or any other *SOX2* variant with minimal expression of eye anomalies (corio-retinal dystrophy and vitreous retraction) but vaginal agenesis. Indeed, previous studies reported *SOX2* variants in four female patients (aged 12.3–28 years) in which A/M and HH coexisted with small or absent ovaries and rudimentary uterus, but without vaginal involvement (Kelberman et al., 2006, 2008; Sato et al., 2007). Schneider et al. (2009) described vaginal adhesions in a 2-year-old female with right anophthalmia, left microphthalmia, coloboma, glaucoma, and cataract. Since vaginal adhesions represent a common finding in prepubertal females, it cannot be unequivocally linked to the *SOX2* variant (c.16G > T) identified in that patient. Finally, a female patient reported in DECIPHER (#281790) harbouring a 7.63 Mb *de novo* heterozygous deletion including *SOX2*, had anophthalmia, microcephaly and ambiguous genitalia. Although the deleted region contains several other morbid genes, none of them is associated with sexual development (as well as microcephaly and anophthalmia) at the heterozygous state, suggesting *SOX2* as major contributor. Together with our observations, all these data definitely expand the phenotypic spectrum of *SOX2* haploinsufficiency to sexual development in XX subjects. Accordingly, immunocytochemistry studies in the ovary of adult mice found high levels of *SOX2* protein in the oocytes (Avilion et al., 2003), and Runck et al. (2014) demonstrated

that *Shh* knockout mice lack *Sox2* expression and show abnormal cloacal morphogenesis, leading to improper septation of the urethra, vagina and rectum. Altogether these findings are in line with the critical role of human SOX genes during embryogenesis and, considering their expression pattern, in the developing reproductive and central nervous systems.

Curiously, a study on a cohort of 346 patients with Mayer-Rokitansky-Küster-Hauser syndrome (MRKHS; OMIM 277000), the second most common cause of primary amenorrhea characterized by uterovaginal aplasia in karyotypically normal females, identified ophthalmologic defects in twelve of them (Rall et al., 2015). Although MRKHS etiology is still mainly unknown, *HNF1B*, one of the candidate genes, interacts with *SOX9* (STRING database, version 10.5). In addition, *LHX1*, another promising candidate for the disease, is connected to the Sonic hedgehog signalling pathway (SHH), which in turn is associated with isolated microphthalmia with coloboma 5 (MCOPCB5; OMIM 611638). Collectively, these findings provide more compelling evidence of the crosstalk between pathways involved in eye and uterovaginal development, although with some exceptions due to incomplete penetrance and extreme phenotypic variability, as underlined by our SOX2 case.

Our patient also showed spastic paraparesis, a clinical feature only rarely documented in SOX2 patients (Fantes et al., 2003; Numakura et al., 2010; Kelberman et al., 2006). Animal studies demonstrated that *Sox2* is expressed in the ventricular zone and plays a key role in spinal cord regeneration (Muñoz et al., 2015), whose inefficient activation recapitulates paraplegia and quadriplegia conditions observed in humans. These observations suggest the potential benefit of a SOX2 gene therapy, which has been recently applied in retinal pigment epithelium cells and proposed for the treatment of age-related macular degeneration (Ezati et al., 2017), not only to revert the ocular manifestations of SOX2 haploinsufficiency but also its detrimental neurological implications.

In conclusion, our case strengthens the extraordinary pleiotropic effects of SOX2 dysregulation, and confirms that SOX2 targeted testing is not exclusively recommended in the case of obvious A/M. We speculate that female genital anomalies might be underestimated, since most of SOX2 female patients that are reported in the literature were diagnosed in early childhood and did not undergo prolonged clinical follow-up.

Conflicts of interest

EE, CG, LG, BI, EC, MR, NEK, MD, TM, and OZ have no conflict of interest.

Appendix A. Supplementary data

Supplementary data related to this article can be found at <http://dx.doi.org/10.1016/j.ejmg.2018.01.011>.

References

Avilion, A.A., Nicolis, S.K., Pevny, L.H., Perez, L., Vivian, N., Lovell-Badge, R., 2003. Multipotent cell lineages in early mouse development depend on SOX2 function.

- Genes Dev. 17 (1), 126–140.
- Bakrania, P., Robinson, D.O., Bunyan, D.J., et al., 2007. SOX2 anophthalmia syndrome: 12 new cases demonstrating broader phenotype and high frequency of large gene deletions. *Br. J. Ophthalmol.* 91 (11), 1471–1476.
- Chacon-Camacho, O.F., Fuerte-Flores, B.I., Ricardez-Marcial, E.F., Zenteno, J.C., 2015. SOX2 anophthalmia syndrome and dental anomalies. *Am. J. Med. Genet. A* 167A (11), 2830–2833.
- Chassaing, N., Gilbert-Dussardier, B., Nicot, F., et al., 2007. Germinal mosaicism and familial recurrence of a SOX2 mutation with highly variable phenotypic expression extending from AEG syndrome to absence of ocular involvement. *Am. J. Med. Genet. A* 143A (3), 289–291.
- Dennert, N., Engels, H., Cremer, K., et al., 2017. De novo microdeletions and point mutations affecting SOX2 in three individuals with intellectual disability but without major eye malformations. *Am. J. Med. Genet. A* 173 (2), 435–443.
- Ezati, R., Etemadzadeh, A., Soheili, Z.S., et al., 2017. The influence of rAAV2-mediated SOX2 delivery into neonatal and adult human RPE cells; a comparative study. *J. Cell. Physiol.* <http://dx.doi.org/10.1002/jcp.25991> [Epub ahead of print].
- Faivre, L., Williamson, K.A., Faber, V., et al., 2006. Recurrence of SOX2 anophthalmia syndrome with gonosomal mosaicism in a phenotypically normal mother. *Am. J. Med. Genet. A* 140 (6), 636–639.
- Fantes, J., Ragge, N.K., Lynch, S.A., et al., 2003. Mutations in SOX2 cause anophthalmia. *Nat. Genet.* 33 (4), 461–463.
- Gerth-Kahlert, C., Williamson, K., Ansari, M., et al., 2013. Clinical and mutation analysis of 51 probands with anophthalmia and/or severe microphthalmia from a single center. *Mol. Genet. Genomic Med* 1 (1), 15–31.
- Kelberman, D., de Castro, S.C., Huang, S., et al., 2008. SOX2 plays a critical role in the pituitary, forebrain, and eye during human embryonic development. *J. Clin. Endocrinol. Metab.* 93 (5), 1865–1873.
- Kelberman, D., Rizzoti, K., Avilion, A., et al., 2006. Mutations within Sox2/SOX2 are associated with abnormalities in the hypothalamo-pituitary-gonadal axis in mice and humans. *J. Clin. Invest.* 116 (9), 2442–2455.
- Muñoz, R., Edwards-Faret, G., Moreno, M., Zuñiga, N., Cline, H., Larraín, J., 2015. Regeneration of *Xenopus laevis* spinal cord requires Sox2/3 expressing cells. *Dev. Biol.* 408 (2), 229–243.
- Numakura, C., Kitanaka, S., Kato, M., et al., 2010. Supernumerary impacted teeth in a patient with SOX2 anophthalmia syndrome. *Am. J. Med. Genet. A* 152A (9), 2355–2359.
- Osborne, R.J., Kurinczuk, J.J., Ragge, N.K., 2011. Parent-of-origin effects in SOX2 anophthalmia syndrome. *Mol. Vis.* 17, 3097–3106.
- Rall, K., Eisenbeis, S., Henninger, V., Henes, M., Wallwiener, D., Bonin, M., Brucker, S., 2015. Typical and atypical associated findings in a group of 346 patients with mayer-rokitansky-kuester-hauser syndrome. *J. Pediatr. Adolesc. Gynecol.* 28 (5), 362–368.
- Ramirez-Botero, A.F., Pachajoa, H., 2016. Syndromic microphthalmia-3 caused by a mutation on gene SOX2 in a Colombian male patient. *Congenital. Anom.* 56 (6), 250–252.
- Reis, L.M., Tyler, R.C., Schneider, A., Bardakjian, T., Semina, E.V., 2010. Examination of SOX2 in variable ocular conditions identifies a recurrent deletion in microphthalmia and lack of mutations in other phenotypes. *Mol. Vis.* 16, 768–773.
- Runck, L.A., Method, A., Bischoff, A., et al., 2014. Defining the molecular pathologies in cloaca malformation: similarities between mouse and human. *Dis. Mol. Med.* 7 (4), 483–493.
- Sato, N., Kamachi, Y., Kondoh, H., et al., 2007. Hypogonadotropic hypogonadism in an adult female with a heterozygous hypomorphic mutation of SOX2. *Eur. J. Endocrinol.* 156 (2), 167–171.
- Schneider, A., Bardakjian, T., Reis, L.M., Tyler, R.C., Semina, E.V., 2009. Novel SOX2 mutations and genotype-phenotype correlation in anophthalmia and microphthalmia. *Am. J. Med. Genet. A* 149A (12), 2706–2715.
- Schneider, A., Bardakjian, T.M., Zhou, J., et al., 2008. Familial recurrence of SOX2 anophthalmia syndrome: phenotypically normal mother with two affected daughters. *Am. J. Med. Genet. A* 146A (21), 2794–2798.
- Suzuki, J., Azuma, N., Dateki, S., et al., 2014. Mutation spectrum and phenotypic variation in nine patients with SOX2 abnormalities. *J. Hum. Genet.* 59 (6), 353–356.
- Williamson, K.A., Hever, A.M., Rainger, J., et al., 2006. Mutations in SOX2 cause anophthalmia-esophageal-genital (AEG) syndrome. *Hum. Mol. Genet.* 15 (9), 1413–1422.
- Zenteno, J.C., Gascon-Guzman, G., Tovilla-Canales, J.L., 2005. Bilateral anophthalmia and brain malformations caused by a 20-bp deletion in the SOX2 gene. *Clin. Genet.* 68 (6), 564–566.
- Zenteno, J.C., Perez-Cano, H.J., Aguinaga, M., 2006. Anophthalmia-esophageal atresia syndrome caused by an SOX2 gene deletion in monozygotic twin brothers with markedly discordant phenotypes. *Am. J. Med. Genet. A* 140 (18), 1899–1903.