

C A S E R E P O R T

A pseudotumoral lesion diagnosed for a hypertrophic fibrosis at the proximal stump in anterior tibialis tendon missed rupture: a case report

Elena Manuela Samaila¹, Filippo Luiso¹, Giacomo Trivellin¹, Matteo Brunelli², Bruno Magnan¹

¹Department of Orthopaedics and Trauma Surgery, University of Verona, Azienda Ospedaliera Universitaria Integrata, Verona, Italy; ²Department of Anatomy, University of Verona, Azienda Ospedaliera Universitaria Integrata, Verona, Italy

Summary. The Anterior Tibialis is the most important muscle in ankle dorsiflexion. The anterior tibialis tendon (ATT)'s rupture is an infrequent condition which can be both traumatic and spontaneous. Clinic is poor and it is necessary to confirm the suspect by US or MRI. The reported case refers to a 40 years old man who had a direct trauma at ankle and midfoot which was originally conservatively treated for an ankle sprain. Three months later he returned with pain, swelling and paresthesia. MRI was performed showing a neoformation in the contest of ATT's rupture. The patient underwent open excisional biopsy which was diagnostic for hypertrophic fibrosis. After two weeks, the symptoms were completely decreased and patient didn't want to undergo surgery for tendon reconstruction because he had no limitation in daily activity life. (www.actabiomedica.it)

Key words: anterior tibialis tendon, tendon rupture, pseudotumor, hypertrophic fibrosis

Introduction

Anterior Tibialis is the most important muscle in ankle dorsiflexion and accounts for more than 80% of the strength required for this motion (1, 2). It runs from lateral condyle of the tibia, lateral surface of tibial shaft, interosseous membrane and fascia cruris to medial cuneiform and first metatarsal (3, 4). Different anatomical variants of distal insertions have been reported in literature. Brenner described a wide band of insertion on the medial cuneiform and a small band of insertion on the base of the first metatarsal (45%), two bands of equal width insertion (27%) and then a narrow band on the medial cuneiform and a wide band of insertion on the base of the first metatarsal (26%). Other types of insertion – only on the medial cuneiform or only at the base of the first metatarsal – were

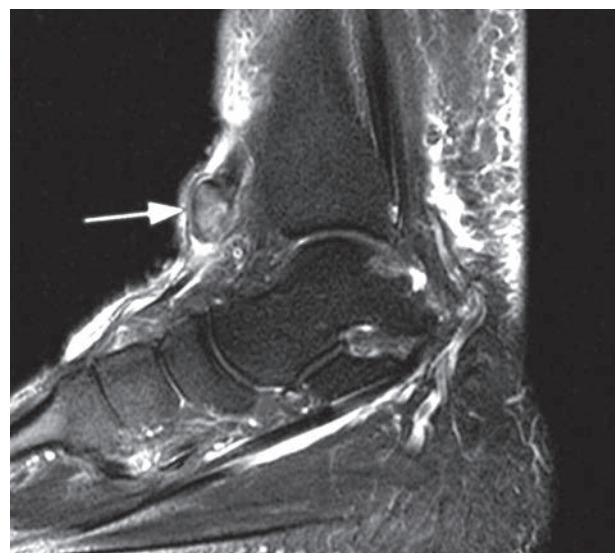


Figure 1. Pre-operative MRI

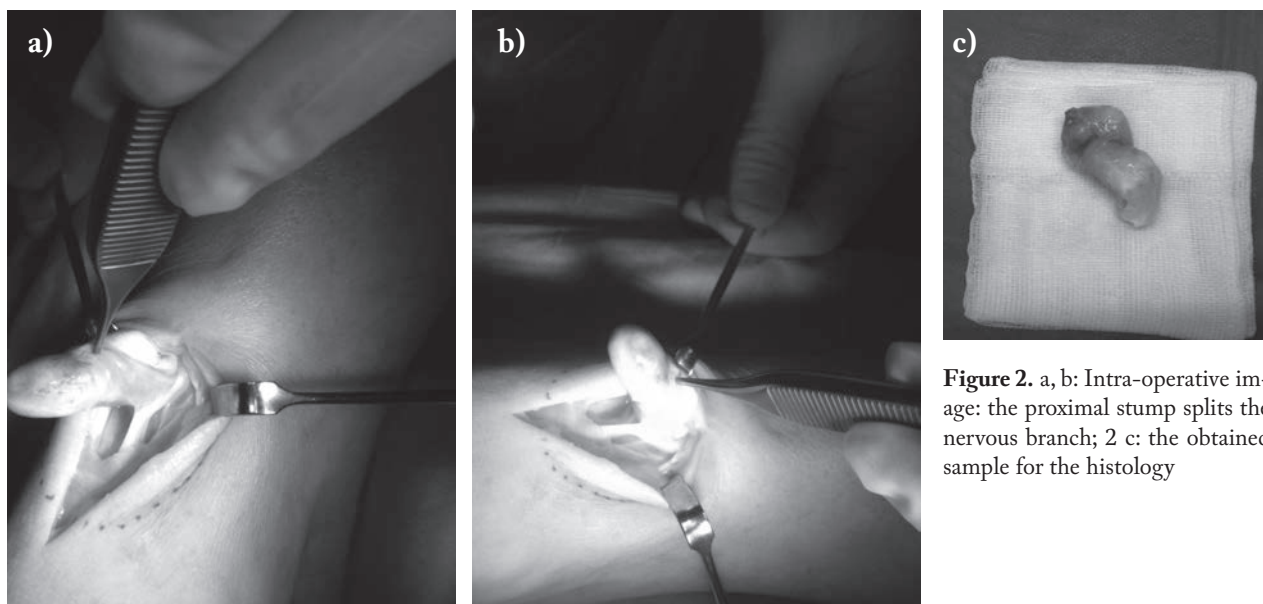


Figure 2. a, b: Intra-operative image: the proximal stump splits the nervous branch; 2 c: the obtained sample for the histology

rarely present (5). There is an avascular zone in the anterior half where the tendon wraps around the superior and inferior retinacula. This is the region where spontaneous ruptures mostly occur being located 0,5 to 3 cm from its distal insertion, beneath the oblique superomedial branch of the inferior extensor retinaculum (6). Anterior Tibialis muscle is innervated by the deep peroneal nerve. Anterior Tibialis Tendon (ATT) allows dorsiflexion of the foot and assists the gait function with inversion of the foot, primarily during the unloaded swing phase, and then limiting the plantar flexion at the initial heel strike (2, 7). In literature, traumatic lesions of ATT are briefly described being an uncommon condition. Rupture can be spontaneous or traumatic. Generally, ruptures occur in older people because of degeneration and friction underneath the extensor retinaculum (8-10). The ruptures may in part be due to metabolic conditions such as diabetes mellitus, gout, systemic lupus erythematosus and rheumatoid arthritis (11-15). Traumatic ruptures result from lacerations or blunt trauma, typically due to forced plantar flexion of the foot and ankle (16, 17). The symptomatology of this rupture is very poor (18). The tear can go clinically unrecognized mainly because of a preserved capability of active dorsiflexion of the foot, which although significantly weakened, is usually

still possible due to integrity of the digitorum longus and hallucis longus (19).

Clinical examination is the best tool for the diagnosis if both feet are comparatively evaluated and can be supported by sonography and MRI (7, 20).

Surgical treatment is mandatory in traumatic ruptures (21), because it is associated with better functional outcomes and lower complication rates compared with conservative treatment (22, 23).

The purpose of this case report is to document the sequels of an ATT missed rupture.

Case report

This is the case of a 40 years old hard worker man, who was admitted to ER after a direct trauma at the anterior part of ankle and the midfoot. Clinically he presented swelling and pain all over, functional limitation and widespread paresthesia on the dorsal foot. Standard X-rays were performed and resulted negative for fractures. He was immobilized with a below knee brace with the diagnosis of ankle sprain. After two weeks, the patient was clinically reevaluated, pain and paresthesia was referred decreased, function was improved, so the brace was removed and he was ad-

vised to begin physiotherapy for articular and muscular recovery. Three months later the patient returned to ER for persistent paresthesia and the presence of a neoformation on the anterior aspect of the ankle that worried him. It was performed a MRI that revealed the presence of an oval neoformation (Fig. 1) under the skin without a clear interpretation, so that radiologist counseled a biopsy in the suspect of a neoplasia. For this reason, the patient was address to our orthopaedic department and underwent surgery. Intraoperatively a pseudotumoral hypertrophic fibrosis was found at the retracted proximal stump of an AIT neglected rupture. This neoformation splatted and compressed the deep peroneal nerve and its branches at this level, provoking the neurological symptoms to the patient. The bulge was resected for histological exam (Fig. 2a, 2b, 2c).

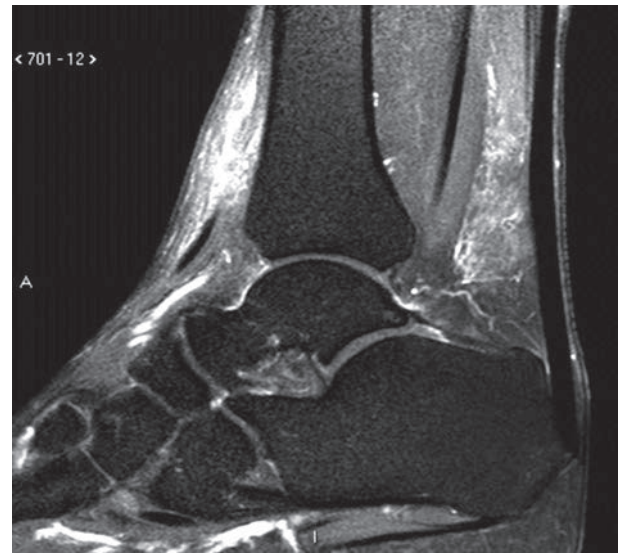


Figure 3. Post-operative MRI

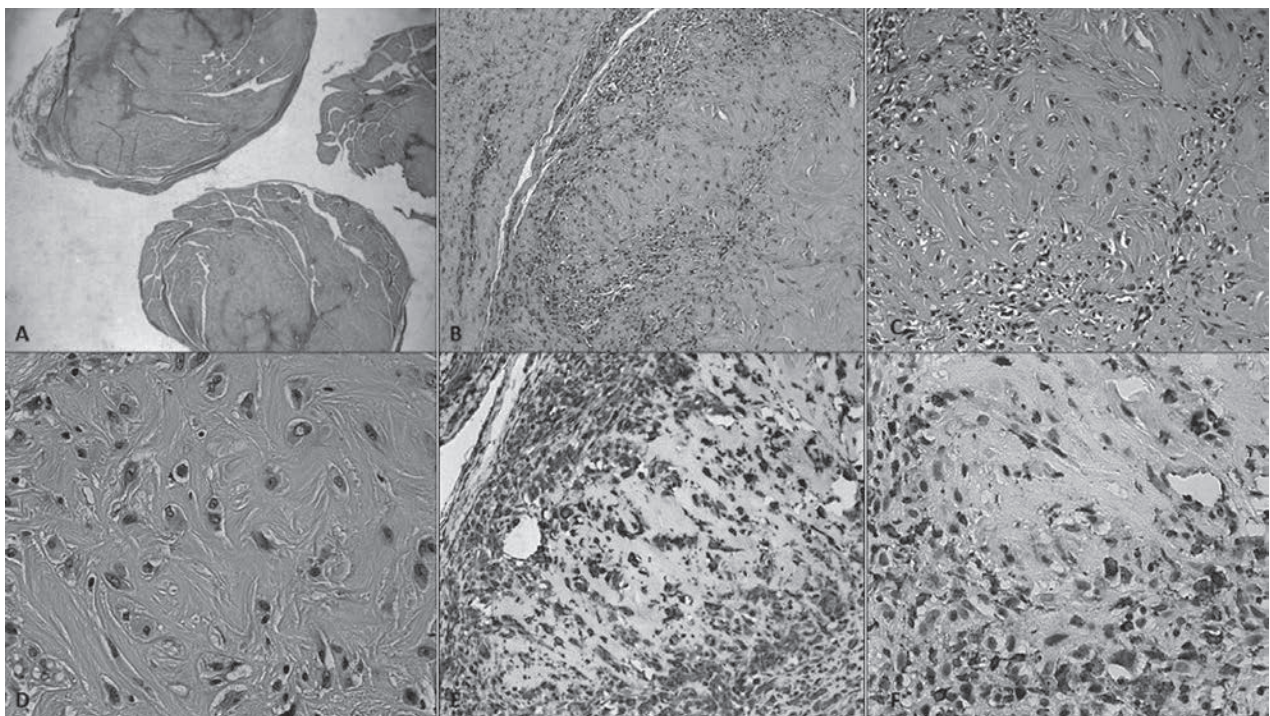


Figure 4. (A) Sections of the nodular lesion with Hematoxylin and eosin staining at low power view (2x). (B) The lesion is composed of two part: a fibrous component and a histiocytic component: the first one is amorphous and pink, the last one is more cellular and blue (5x). (C, D) At high power view the histiocytic component is more evident: there are plump cells with a large cytoplasm, an irregular cytoplasmatic membrane and one eccentric nucleus (20x; 40x). (E, F) Immunohistochemistry is very useful to identified the two component. (E) Vimentin antibody identified the mesenchimal origin of the lesion and is positive both in the fibrous and in the histiocytic part. (F) CD68 antibody result positive in the histiocytic part of the lesion

We clinically evaluated the patient in the first days after surgery. He presented no more paresthesia and pain, dorsiflexion and supination were possible. Two weeks later, we assessed the muscular strength with the Oxford Scale and it was found shifted from 0/5 to 3/5. The patient returned at work. A reconstruction surgery was then proposed, but patient didn't accept it because of a very few weakness in dorsiflexion which didn't bother him in his daily activities. The result of the histological exam and a new MRI, performed a month later, confirmed the intraoperative diagnosis (Fig. 3, 4) Clinical evaluation of ATT revealed a strength grade of 4/5.

Discussion

Isolated rupture of ATT is uncommon. This is probably because it is rarely diagnosed in the acute post traumatic phase and late diagnosis becomes more difficult. In some cases, there is also a soft-tissue swelling. A sonography, which would show the retracted stump, can be made in order to confirm this diagnosis. When in doubt, additional examinations such as magnetic resonance imaging can be helpful. An injury of the peroneal nerve should also be excluded. There is not a standard treatment because of the rare occurrence of the lesion. In our case the ATT rupture gave no functional limitations and the articular recovery was good and rapid. The neurological symptoms due to the hypertrophic fibrosis of the proximal stump were the cause of the decision making for surgery. It was important, as first step, to exclude a neoplastic lesion and prevent peripheral neurological disorders.

References

- Rodrigues ME, Pereira A, Alpoim B, Muras Geadá J. Traumatic rupture of the tibialis anterior tendon: a case report. *Rev Bras Ortop* 2013; 48(3): 278-81.
- Borley NR, Healy JC, Collins P, Johnson D, Crossman AR, Mahadevan V, et al. Leg. In: Standring S, et al., editors. *Grays anatomy*. 40. New York: Churchill Livingstone Elsevier; 2008: 1417.
- Saraffian SK, Kelikian AS. Tendon sheaths and bursae. In: Saraffian SK, Kelikian AS, editors. *Anatomy of the foot and ankle: descriptive, topographic, functional*. Philadelphia: Lippincott; 2011: 292.
- Arthornthurasook A, Gaew Im K. Anterior tibial tendon insertion: an anatomical study. *J Med Assoc Thai* 1990; 73: 692-6.
- Brenner E. Insertion of the tendon of the tibialis anterior muscle in feet with and without hallux valgus. *Clin Anat* 2002; 15: 217-223. doi: 10.1002/ca.10021.
- Petersen W, Stein V, Tillmann B. Blood supply of the tibialis anteriortendon. *Arch Orthop Trauma Surg* 1999; 199: 371-5.
- Varghese A, Bianchi S. Ultrasound of tibialis anterior muscle and tendon: anatomy, technique of examination, normal and pathological appearance. *J Ultrasound* 2014 Jun; 17 (2): 113-23. Published online 2013 Dec 19.
- Patten A, Pun WK. Spontaneous rupture of the tibialis anterior tendon: a case report and literature review. *Foot Ankle Int* 2000; 21: 697-700.
- Bernstein RM. Spontaneous rupture of the tibialis anterior tendon. *Am J Orthop* 1995; 24(4): 354-6.
- Burman M. Subcutaneous Rupture of the tendon of the tibialis anticus. *Ann Surg* 1934; 100: 368-372.
- Di Domenico LA, Williams K, Petrolla AF. Spontaneous rupture of the anterior tibial tendon in a diabetic patient: results of operative treatment. *J Foot Ankle Surg* 2008; 47(5): 463-7.
- Patten A, Wai-Ki P. Spontaneous rupture of the tibialis anterior tendon: A case report and literature review *Foot AnkleInt* Aug 2000; 21(8): 697-700.
- Galluzzo E, Lischi DM, Taglione E, Lombardini F, Pasero G, Perri G, Riente L. Sonographic analysis of the ankle in patients with psoriatic arthritis. *Scand J Rheumatol* 2000; 29: 52-5.
- Morgan J, McCarty DJ. Tendon ruptures in patients with systemic lupus erythematosus treated with corticosteroids. *Arthritis Rheum* 1974; 17: 1033-6.
- Jerome JTJ, Varghese M, Sankaran B, Thomas S, Thirumagal SK. Tibialis anterior tendon rupture in gout – case report and literature review. *Foot Ankle Surg* 2008; 14(3): 166-9.
- Moyer J, Kosanovich R. Anterior tibial tendon injuries. *Clin Podiatr Med Surg* 2002; 19(3): 433-40.
- Rajeev A, McDonald M, Newby M, Patterson P. Traumatic avulsion of tibialis anterior following an industrial accident: a case report. *Int J Surg Case Rep* 2015; 14: 125-8. Published online 2015 Jul 31.
- Jerome JT, Varghese MS, Sankaran B, Thirumagal K. Tibialis anterior rupture: A missed diagnosis. *The Foot and Ankle Online Journal* 2010; 3: 2.
- Wulker N, Hurschler C, Emmerich J. In vitro simulation of stance phase gait. II: simulated anterior tibial tendon dysfunction and potential compensation. *Foot Ankle Int* 2003; 24: 623-9.
- Gallo RA, Kolman BH, Daffner RH, Sciulli RL, Roberts CC, DeMeo PJ. MRI of tibialis anterior tendon rupture *Skeletal Radiol*. 2004 Feb; 33(2): 102-6. Epub 2003 Nov 6.

21. Sammarco VJ, Sammarco GJ, Henning C, Chaim S. Surgical repair of acute and chronic tibialis anterior tendon ruptures. *J Bone Joint Surg Am* 2009; 91(2): 325-32.
22. Carvalho Júnior AE, Bittar CK, Salomão O, Miranda JB, Ninomiya A, Silva. DB. Tendinopatia do compartimento anterior do tornozelo. *Rev Bras Ortop* 2010; 2010; 45(2): 141-7.
23. Ouzounian TJ, Anderson R. Anterior tibial tendon rupture. *Foot Ankle Int* 1995; 16(7): 406-1.

Received: 18 August 2017

Accepted: 5 September 2017

Correspondance:

Elena Manuela Samaila

Department of Orthopaedics and Trauma Surgery,
University of Verona

Azienda Ospedaliera Universitaria Integrata, Verona, Italy

Tel. 045-8123542

E-mail: elenasamaila@yahoo.it