

Case Report

The recurrent causal mutation for osteogenesis imperfecta type V occurs at a highly methylated CpG dinucleotide within the *IFITM5* gene

Massimiliano Corradi^a, Elena Monti^a, Giacomo Venturi^a, Alberto Gandini^a, Monica Mottes^{b,*} and Franco Antoniazzi^a

^aDepartment of Life and Reproduction Sciences, Section of Pediatrics, University of Verona, Verona, Italy

^bDepartment of Life and Reproduction Sciences, Section of Biology and Genetics, University of Verona, Verona, Italy

Received 1 April 2014

Revised 11 April 2014

Accepted 11 April 2014

Abstract. Recent studies have identified the molecular defect underlying autosomal dominant osteogenesis imperfecta (OI) type V. Unlike all other OI types, which are characterized by high genetic heterogeneity, OI type V appears consistently associated to a unique *de novo* C>T transition within the 5' UTR of the *IFITM5* gene. Although the precise frequency of OI type V is not known, this recurrent base substitution may well represent a mutational hotspot in the human genome. We show that it occurs at a CpG dinucleotide that is highly methylated in several tissues and particularly in the sperm DNA, suggesting a mutational mechanism common to other *de novo* recurrent dominant mutations.

Keywords: Osteogenesis imperfecta, *IFITM5*, DNA methylation, CpG dinucleotide deamination

1. Introduction

Osteogenesis imperfecta (OI) is a heterogeneous group of disorders, which share common features such as bone fragility, frequent fractures, deformities of the spine and limbs.

The current classification comprises five forms (OI types I–V) with autosomal dominant (AD) inheritance and eight rare forms (OI types VI–XIII) with recessive

inheritance. The majority of OI cases falls within types I–IV, caused by dominant mutations in either of the type I collagen coding genes (*COL1A1* and *COL1A2*) [1, 2]. OI type V (MIM 610967), which is also characterized by AD inheritance, has distinguishing clinical and radiological features: absence of blue sclerae, absence of dentinogenesis imperfecta, propensity to hyperplastic callus formation, calcification of the forearm interosseous membrane, radial-head dislocation, and a subphyseal-metaphyseal radiodense line [3]. The disease gene, coding for *IFITM5* (interferon-induced transmembrane protein 5) was identified recently. A c.-14C>T recurrent mutation in its 5'UTR has been found in >60 patients so far [4–7]. The *de novo*

*Corresponding author: Dr. Monica Mottes, PhD, Professor of Applied Biology, Department of Life and Reproduction Sciences, University of Verona, Strada le Grazie, 8 37134 Verona, Italy. Tel.: +390458027184; Fax: +390458027180; E-mail: monica.mottes@univr.it.

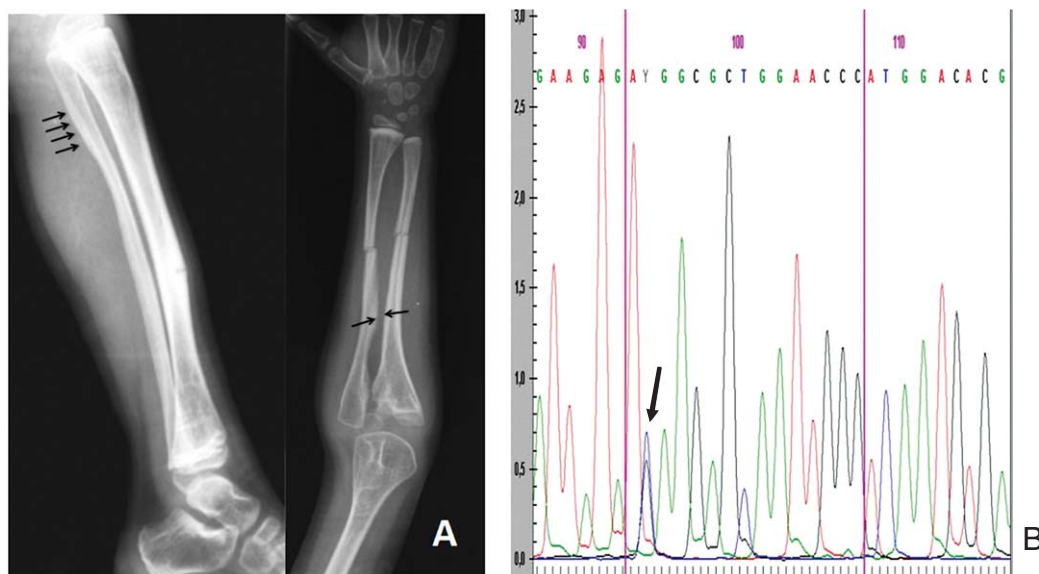


Fig. 1. (A) Radiographs of the patient's limbs showing fractures and interosseous membrane calcifications development as well as the initial evidence of periosteal calcification (arrows). Radial head dislocation is visible on the forearm anteroposterior view. (B) Sequence of patient's genomic DNA obtained from leukocytes showing C/T heterozygosity at -14 nt within the 5'UTR region of *IFITM5*.

C>T substitution which occurs at a CpG dinucleotide and creates an upstream ATG codon in frame with the canonical start codon, might be the prevailing, if not the only, causative mutation for type V OI. The mutation adds five residues to the N-terminus of the *IFITM5* transmembrane protein, possibly with a gain-of-function effect. We have found the same base substitution in a young male patient showing typical radiographic and clinical features of type V OI. We then decided to investigate this mutational hotspot further within the *IFITM5* gene in relation to the methylation state of c.-14C.

2. Case report

The proband is a 7-year-old boy born at term to non-consanguineous unaffected parents, after a pregnancy characterized by mild oligohydramnios. His weight was on the 10th percentile (2.600 g at 38 wk of gestational age). He was diagnosed as affected with OI soon after birth because of a forearm fracture. He was started and currently is on bisphosphonate (Neridronate) treatment because of high fracture rate. He was classified as OI type V only after age 5 because of pathognomonic outcomes such as interosseous membrane calcifications, the initial evidence of periosteal

calcification and the emergence of hyperplastic callous formation (Fig. 1A). His growth and his bone density are around the 10–25th percentile. As for biological data he has elevated bone alkaline phosphatase ($>120 \mu\text{g/L}$; mean value in our age/gender matched controls: $70 \pm 30 \mu\text{g/L}$) and high carboxy-terminal collagen cross-links level (0.888 nmol/L ; normal values: $0.150\text{--}0.450$) only slightly decreasing during bisphosphonate treatment. Joints movements are regular except for functional limitations of elbow extension and forearms pronation. On the basis of the radiological signs, we addressed the molecular investigation towards the *IFITM5* gene and confirmed the presence of the pathognomonic mutation, c.-14C>T, in heterozygosity (Fig. 1B). Parental DNAs, obtained from peripheral blood leukocytes, did not bear the mutation (data not shown), thus confirming its *de novo* occurrence.

A large proportion of spontaneous mutations occur at 5-methyl-cytosines at CpG dinucleotide sites which undergo deamination [8]. In order to test whether the nucleotide c.-14C in *IFITM5* gene may be a mutational hotspot, we investigated its methylation state in sperm DNA and a few somatic tissues, as described in materials and methods. The methylation rate (p) for any CpG within the sequenced region was calculated as $p = H_{\text{minor}} / (H_{\text{major}} + H_{\text{minor}})$ as described

[9]. Sequence analysis revealed that c.-14C is 100% methylated in sperm and leukocytes while it appears $\geq 80\%$ methylated in bone marrow and in fibroblasts (Table 1). We also observed that, among the different DNAs tested, fibroblast DNA showed the lowest methylation levels within the *IFITM5* promoter region.

Patient's data and biological samples were obtained after fully informed parental consent according to the procedures established by the local bioethical committee. Genomic DNA samples from leukocytes, sperm, bone marrow, cultured skin fibroblasts, were prepared using PureGene DNA isolation kits (Gentra Systems, Minneapolis, MN, USA).

2.1. Mutation detection

Heterozygosity of the proband for the c.-14C>T transition was revealed by direct sequencing of amplified genomic DNA obtained from a peripheral blood sample.

2.2. Methylation analysis

Total genomic DNA was extracted from cultured skin fibroblasts, leukocytes, sperm and bone marrow, obtained from six healthy subjects. In detail, two male subjects were investigated for leukocyte, sperm, bone marrow and fibroblast DNA; two additional male individuals were investigated for leukocyte and sperm DNA only; two female subjects were investigated for leukocyte, bone marrow and fibroblast DNA. DNA was sodium-bisulfite modified with an Epitect kit (Qiagen, Valencia, CA, USA) according to the manufacturer's instructions. For each bisulfite treatment we used 1 μ g of DNA. Briefly, in this reaction all unmethylated cytosines are deaminated to be converted into uracil bases, while 5-methylcytosines remain unaltered. Treated DNAs were subsequently amplified (primer sequences available upon request). The PCR products spanning the c.-302 to c.186 region of *IFITM5* gene were then purified and sequenced by DTCS quick start mix on a CEQ 8800 Genetic Analysis System (Beckman Coulter, Brea, CA, USA).

3. Discussion

OI is traditionally recognized as a collagen disorder. Mutations in the genes coding for type I collagen are responsible for the great majority of AD forms, while

mutations in genes whose products are involved in post-translational modifications, folding, chaperoning, cross-linking of type I collagen have been associated to both recessive and dominant rarer forms of OI [2]. AD OI type V is not a collagen disorder and it features distinctive defects in bone mineralization [3]. OI type V has been associated to a single recurrent mutation in *IFITM5* gene. The pathophysiological role of *IFITM5* gene product, a transmembrane protein named BRIL highly expressed in osteoblasts during mineralization, is just starting to get clarified. Recently a missense mutation within *IFITM5* was characterized in a OI patient with a distinctive clinical phenotype [10]. The study results suggest a regulatory role of BRIL over the production of Pigment Epithelium-Derived Factor, a multifunctional protein which plays a crucial role in bone mineralization, and which is absent in a recessive clinical form, OI type VI [11]. Further investigations hopefully will shed light over the relationship between Pigment Epithelium-Derived Factor and BRIL and the discovery of new mutations in their respective genes will help us understand the connection between types V and VI OI.

All the type V OI cases reported are sporadic and belong to different ethnic groups; the above observations suggest that nucleotide c.-14C in the 5' UTR of *IFITM5* is a mutational hotspot. Evidence from both evolutionary studies and human diseases show that methylated CpG sequences may undergo deamination and represent mutational hotspots [12]. Our data demonstrate that the recurrent *de novo* mutation causing type V OI involves deamination at a CpG dinucleotide, which is 100% methylated in male germ cells. The same mutational mechanism is responsible for the highly recurrent c.1138G>A *FGFR3* gene mutation, which causes achondroplasia (OMIM 100800). Spermatogonial mutations in achondroplasia are the most common cause; a paternal age effect has been inferred, owing to the increasing number of DNA replication cycles, which spermatogonia undergo before embarking on the meiotic divisions that lead to mature sperm [13]. It would be interesting to track the parental origin of *IFITM5* c.-14C-T mutations to investigate if there is a paternal-age effect.

Acknowledgments

We thank the proband and his family for their participation to the study. We acknowledge the financial

support of Azienda Ospedaliera Universitaria Integrata and of Italian Ministry of University and Research. We are also grateful to the Italian O.I. association for continuous support.

References

- [1] Marini JC, Forlino A, Cabral WA, Barnes AM, San Antonio JD, Milgrom S, et al. Consortium for osteogenesis imperfecta mutations in the helical domain of type I collagen: Regions rich in lethal mutations align with collagen binding sites for integrins and proteoglycans. *Hum Mutat* 2007;28(3):209-21.
- [2] Forlino A, Cabral WA, Barnes AM, Marini JC. New perspectives on osteogenesis imperfecta. *Nat Rev Endocrinol* 2011;7(9):540-57.
- [3] Glorieux FH, Rauch F, Plotkin H, Ward L, Travers R, Roughley P, et al. Type V osteogenesis imperfecta: A new form of brittle bone disease. *J Bone Miner Res* 2000;15(9):1650-8.
- [4] Hanagata N, Li X, Morita H, Takemura T, Li J, Minowa T. Characterization of the osteoblast-specific transmembrane protein IFITM5 and analysis of IFITM5-deficient mice. *J Bone Miner Metab* 2011;29(3):279-90.
- [5] Cho TJ, Lee KE, Lee SK, Song SJ, Kim KJ, Jeon D, et al. A single recurrent mutation in the 5'-UTR of IFITM5 causes osteogenesis imperfecta type V. *Am J Hum Genet* 2012;91(2):343-8.
- [6] Semler O, Garbes L, Keupp K, Swan D, Zimmermann K, Becker J, et al. A mutation in the 5'-UTR of IFITM5 creates an in-frame start codon and causes autosomal-dominant osteogenesis imperfecta type V with hyperplastic callus. *Am J Hum Genet* 2012;91(2):349-57.
- [7] Rauch F, Moffatt P, Cheung M, Roughley P, Lalic L, Lund AM, et al. Osteogenesis imperfecta type V: Marked phenotypic variability despite the presence of the IFITM5 c.-14C>T mutation in all patients. *J Med Genet* 2013;50(1):21-4.
- [8] Cooper DN, Krawczak M. Cytosine methylation and the fate of CpG dinucleotides in vertebrate genomes. *Hum Genet* 1989;83(2):181-8.
- [9] Qiu P, Soder GJ, Sanfiorenzo VJ, Wang L, Greene JR, Fritz MA, et al. Quantification of single nucleotide polymorphisms by automated DNA sequencing. *Biochem Biophys Res Commun* 2003;309(2):331-8.
- [10] Farber CR, Reich A, Barnes AM, Becerra P, Rauch F, Cabral WA, et al. A Novel IFITM5 mutation in severe atypical osteogenesis imperfecta type VI impairs osteoblast production of pigment epithelium-derived factor. *J Bone Miner Res* 2014 (in press).
- [11] Homan EP, Rauch F, Grafe I, Lietman C, Doll JA, Dawson B, et al. Mutations in SERPINF1 cause osteogenesis imperfecta type VI. *J Bone Miner Res* 2011;26(12):2798-803.
- [12] Qu W, Hashimoto S, Shimada A, Nakatani Y, Ichikawa K, Saito TL, et al. Genome-wide genetic variations are highly correlated with proximal DNA methylation patterns. *Genome Res* 2012;22(8):1419-25.
- [13] Wilkin DJ, Szabo JK, Cameron R, Henderson S, Bellus GA, Mack ML, et al. Mutations in fibroblast growth-factor receptor 3 in sporadic cases of achondroplasia occur exclusively on the paternally derived chromosome. *Am J Hum Genet* 1998;63(3):711-6.