
Neuroimaging of Epilepsy: EEG-fMRI in the Presurgical Evaluation of Focal Epilepsy

Mirko Avesani, Silvia Giacomuzzi and
Antonio Fiaschi

Additional information is available at the end of the chapter

<http://dx.doi.org/10.5772/55197>

1. Introduction

Epilepsies of surgical interest are focal and drug-resistant forms associated with various different conditions (malformations, stroke, tumors, infectious and/or inflammatory processes, brain injuries). There is mounting evidence that early resective surgery can achieve seizure-free status or reduce seizure frequency. The main challenge in the presurgical assessment of patients with epilepsy is to localize the area of seizure onset (the epileptogenic zone) and to distinguish it from lesional and interictal foci (the irritative zone) because it is only by treating the epileptogenic zone that seizure freedom or a reduction in events may be attained (Thorton, 2010).

This is explained by the fact that since the interictal focus is larger than the epileptogenic zone, the epileptogenic zone does not always overlap the lesional area and the epileptogenic focus is often larger than lesional area (Avesani, 2008/a; Manganotti, 2008; Thorton, 2010). In general, interictal epileptic discharges may affect brain areas well beyond the presumed region in which they are generated (Gotman, 2008). While resection of the lesional area alone is not sufficient, neither can the entire interictal focus be removed due to the high risk of cognitive, motor, sensitive or language deficits.

Presurgical evaluation involves invasive investigation by stereoelectroencephalography (SEEG) performed after other routine exams (standard EEG, video-EEG, functional neuroimaging) to identify the interictal focus within the epileptogenic zone. The lesional area, instead, is nowadays studied with advanced MRI techniques developed to better identify the interictal focus.

2. Functional imaging in epilepsy

Functional imaging refers to noninvasive methods to identify the interictal focus and the epileptogenic zone which, in a subsequent step, is studied with an invasive technique (SEEG, electrocortical mapping). The most widely used are:

- positron-emission tomography (PET)
- single-photon-emission computed tomography (SPECT)
- magnetic resonance spectroscopy (MRS)
- functional magnetic imaging (fMRI)

These techniques allow the study of a specific area of the brain, obviating the need for invasive studies of the entire brain. PET and SPECT were initially utilized for this purpose. While both provide a better knowledge of the brain's functional anatomy, they rarely allow for a precise localization of an epileptogenic focus, making them less useful for surgical planning (Marks, 1992; Henry, 1993; Newton, 1995).

The rationale for SPECT is based on its ability to reveal, *in vivo*, the volume distribution of a radiotracer after intravenous injection, and to evaluate, quantitatively and qualitatively, regional brain perfusion (Devous, 2005). The application of SPECT in epilepsy derives from a known association between an electrical event and brain perfusion: brain perfusion increases during the ictal phase and decreases during the interictal phase. Studies using dynamic and static SPECT have demonstrated interictal temporal hypoperfusion in 50% patients with temporal-lobe epilepsy (TLE). Nevertheless, the limitation of this technique is that 5-10% of patients demonstrate contralateral hypoperfusion, which raises the risk of false localization (Krausz, 1991). The localization power of SPECT during the interictal phase is, therefore, variable, with a sensitivity of 36% and a specificity of 95% (Engel, 1982). For this reason, SPECT is useful as a comparative study of ictal and interictal perfusion in selected patients. When applied during a seizure, it demonstrates the dynamic aspect of the seizure during its development. Unlike interictal studies, ictal SPECT, in both temporal and extratemporal epilepsy, is accurate in localizing an epileptogenic focus. During the ictal phase it can reveal, with a sensitivity of 70-95%, hyperperfusion in an area activated by seizures (Engel, 1983; Lee, 1994).

PET is a powerful imaging technique to quantify, *in vivo* and noninvasively, cerebral blood flow, metabolism and receptorial links. Its main application derives from the need to identify epileptogenic foci in patients with drug-resistant epilepsy, potential candidates for surgical treatment to control or abolish drug-resistant focal seizures. In up to 20-30% of such patients, who are candidates for surgical treatment, the MRI exam is negative (Duncan, 1997) because microscopic structural malformations, identifiable only by histological study, are not detectable with conventional MRI (Kuzniecky, 1991). Using [¹¹C]flumazenil positron-emission tomography ([¹¹C]FMZ-PET), Hammers studied 18 patients with TLE and normal MRI: 16 demonstrated abnormalities in the binding of ¹¹C-FMZ in the temporal lobe; 7 of these were concordant with clinical and standard EEG data; 3 patients underwent surgical treatment of

the anterior temporal lobe, with marked clinical improvement. The neuropathological data revealed microdysgenesis not detected by MRI (Hammers, 2002).

In patients with focal seizures, glucose metabolism and cerebral blood flow in a particular focal region are increased during an ictal event (Engel, 1983). In the postictal phase, hyperperfusion gradually returns to the basal level, but glucose metabolism remains elevated for 24-48 hours after seizure termination (Leiderman, 1994). In the interictal phase, PET demonstrates a decrease in glucose metabolism and cerebral blood flow in the epileptogenic focus. Studies using 18-fluoro-2-deoxy-glucose-positron emission tomography (18F-FDG-PET) demonstrated hypometabolism in the temporal lobe in 60-90% of patients with interictal spikes (Duncan, 1997). Nevertheless, an area with abnormal cerebral blood flow and metabolism, as detected with PET, is larger than the real structural anomaly generating an epileptogenic focus probably because of deafferentation phenomena in the surrounding neurons in areas of seizure propagation (Duncan, 1997). Since this carries the risk of false localization, PET is regarded as being more suitable for studying lateralization than localization (Tai, 2004).

MR spectroscopy can be utilized in the noninvasive assessment of specific cerebral metabolites. In epilepsy the aim is to determine a focal change in the main metabolites deriving from focal brain dysfunction. The initial aim of the method was to delimit the epileptogenic focus and to analyze the distant repercussions of the lesion and the focus. For example, spectroscopy can reveal bilateral hippocampal abnormalities in unilateral mesial temporal sclerosis (MTS). The technique has demonstrated its utility in identifying metabolic dysfunction in patients with TLE. Nevertheless, owing to its high sensitivity, metabolic abnormalities may be revealed in regions without an epileptogenic focus, making it difficult to distinguish the causal abnormalities from their consequences (Ruben, 2005).

In patients with drug-resistant TLE, spectroscopy demonstrated a lower N-acetyl aspartate/creatinine (NAA/Cr) ratio, a reliable marker of neuronal integrity, in the ipsi- and contralateral lobes, and this finding correlated negatively with seizure duration (Bernasconi, 2002). Patients with frequent generalized seizures were noted to have a lower NAA/Cr ratio than those with rare or no seizures. Another interesting finding was the demonstration of reversible dysfunction in the cortical area after surgical treatment (Hugg, 1996). What all this suggests is that seizures may induce additional neuronal damage that will progress with the duration of epilepsy. From this point of view, spectroscopy may be useful as a metabolic marker of disease progression. In the future, it may be possible to decide whether evidence of disease progression on spectroscopy may be sufficient to suggest a change of therapy (Petroff, 2002).

Functional MRI (fMRI) provides high-resolution images using the classical principles of MRI, with the difference that signal recording exploits the paramagnetic properties of hemoglobin when its iron atom changes from Fe³⁺ (oxygenated hemoglobin) to Fe²⁺ (deoxygenated hemoglobin). Only Fe²⁺ has the ability to locally modify the magnetic state of cerebral tissues (Berns, 1999). Activation of a cerebral area causes both oxidative metabolism and local cerebral blood flow to increase, leading to greater oxygen extraction by the tissues. This results in a local increase of deoxyhemoglobin. Functional MRI reveals the activation of a cerebral area from the higher level of deoxyhemoglobin compared to the basal condition. And it does this indirectly by measuring the vascular response to activation of the cerebral area under study.

The response has a variable latency (from 3-5 to 10 seconds), which is why this kind of information is defined as “functional”, and the recorded signal, related to hemoglobin oxygenation, is defined as BOLD (Blood Oxygen Level Dependent) (Ogawa, 1990; Pritchard, 1994).

fMRI works by comparing the images obtained in rest condition with those acquired during a task. Whether and to what extent physiological correlates match different BOLD phases (Menon, 2001) continues to fuel debate, though studies suggest that the fMRI signal is closely related to neuronal activation (Logothetis, 2001). The method was first applied to localize areas associated with motor, sensory and cognitive functions in epileptic patients and to obtain a precise localization of these functions in the presurgical evaluation of epilepsy (Puce, 1995; Binder, 1996; Dupon, 2002).

3. EEG-fMRI

This noninvasive technique provides reliable information to localize cerebral regions generating interictal epileptic activity. It involves the simultaneous recording of EEG and fMRI. With ongoing refinement of the technology (first of all removal of magnetic field artifact on EEG), initial technical limitations have been overcome (Ives, 1993). EEG-fMRI permits the study cerebral activation and deactivation related to infra-clinical spikes by comparing EEG with spiked activity against EEG without abnormalities (Krakow, 1999 and 2001; Lazeyras 2000; Archer, 2003).

Research to date has investigated lesional epilepsy in the temporal region in particular, the most frequent cause of epilepsy of surgical interest. Up until several years ago, triggered EEG-fMRI was used. EEG was recorded during a scanning session, and fMRI acquisition was performed when a neurologist identified, on line, interictal (spikes, polyspikes, spike waves) activity on EEG. Acquisition was performed after a fixed latency (3-5 seconds) from detected interictal activity, which was decided before starting acquisition. The technique had several limitations: it was based on the concept of standardized cerebral hemodynamic activity, even if we know that such activity varies widely (from 3 up to 10 seconds); analysis had to be performed offline using, as a task, spikes with different morphology; and the temporal dynamics of hemodynamic responses could not be identified. Owing to these limitations, early studies with triggered EEG-fMRI (Krakow, 1999 and 2001) showed low sensitivity (60%) in detecting hemodynamic activation related to interictal activity.

Later studies (Lazeyras, 2001; Lemieux, 2001; Al-Asmi, 2003) demonstrated the superiority of continuous EEG-fMRI based on offline analysis after simultaneous EEG recording during a fMRI scanning session and following artifact removal. This development brought about clear advantages: since it was no longer necessary to decide beforehand which abnormal events were to be studied (and recorded) during a single acquisition, the temporal evolution of activations (after 1 to 10 seconds) could be identified and pathophysiological hypotheses about their propagation postulated. Continuous EEG-fMRI detects activation with a sensitivity of 80%.

Numerous studies have applied continuous EEG-fMRI to investigate various different epileptic syndromes (Boor, 2003; Salek-Haddadi, 2003 and 2006; Bagshaw, 2004 and 2006; Aghakhani, 2004 and 2005; Gotman, 2004 and 2005; Kobayashi, 2005 and 2006; Laufs, 2006; Di Bonaventura, 2006; Vaudano, 2009). Some studied focal epilepsies, while others examined idiopathic generalized forms underlying absence seizures.

4. EEG-fMRI in absence seizures

The application of EEG-fMRI in idiopathic generalized epilepsy (IGE), for evident technical problems, is limited to absence seizures or nonconvulsive status, to analyze the network underlying impaired consciousness related to generalized spike wave (GSW) discharges. Clinically, absences are characterized by a blank stare and impaired consciousness. Activities requiring vigilant attention have been coupled with a lesser likelihood of absences, whereas an increased frequency of seizures during relaxation is well established (Andermann, 2000; Guey, 1969). These findings suggest a causal link between changes in the level of awareness and the occurrence of GSW discharges.

Recent functional imaging studies have revealed the existence of a set of brain regions which show increased functional and metabolic activity during rest, compared to attention-demanding tasks (Raichle, 2000; Mazoyer, 2001). Involved brain areas (the posterior cingulate cortex, the precuneus, the medial prefrontal cortex, the mid-dorsolateral prefrontal and the anterior temporal cortices) have been hypothesized to constitute the so-called default mode network (DMN) (Raichle, 2000). Decreased DMN activity during cognitive tasks indicates that the network sustains spontaneous thought processes or self-oriented mental activity that characterizes the brain's resting state.

Additionally, the precuneus/posterior cingulate node has been recently demonstrated to have the highest degree of interactions (as shown by a partial correlation approach to fMRI data) with the rest of the DMN (Frasson, 2008), suggesting a pivotal role of this area within the network. This interpretation is in line with evidence from previous PET studies that this brain region, and the precuneus in particular, has the highest metabolic rate, consuming 35% more glucose than any other area of the cerebral cortex at rest (Gusnard, 2001).

The DMN shows decreased activity during both attention-demanding tasks and states of reduced vigilance and, especially in the posteromedial cortical regions, during altered states of consciousness (Laureys, 2004; Faymonville, 2006). From these observations, several authors (Cavanna, 2006 and 2007; Boly, 2008) suggested a pivotal role of the posteromedial cortical region in self-consciousness inside the DMN.

EEG-correlated functional magnetic resonance imaging (EEG-fMRI) studies have shown a common pattern of BOLD signal decrease in the precuneus and other DMN areas, together with an increase in the thalamic BOLD signal, during ictal and interictal GSW discharges (Aghakhani, 2004; Archer, 2003; Gotman, 2005; Hamandi, 2006; Laufs, 2006; Salek-Haddadi, 2003; De Tiege, 2007; Labate, 2005). Decreased cerebral blood flow consistent with a decrease

in neuronal activity was demonstrated in DMN regions during GSW discharges (Hamandi, 2008). Therefore, these relative BOLD signal decreases can be interpreted as a transitory suspension of the brain's "default state" which occurs in association with an altered level of awareness observed during GSW discharges and absences, respectively (Gotman, 2005; Hamandi, 2006; Laufs, 2006; Salek-Haddadi, 2003).

The pathophysiological substrate of GSW remains enigmatic. Studies in animals and humans have tried to answer persistent questions about the putative role of the thalamus and cortex as generators. Data from invasive recordings and manipulations in well-validated genetic models of absence epilepsy have lent support to the hypothesis that absence seizures are of cortical origin (Steriade, 1998; Meeren, 2002 and 2005; Polack, 2007; Holmes, 2004; Tucker, 2007).

Following on the suggestion of the involvement of dorsal cortical regions (particularly the posterior-medial cortical regions) in GSW discharges from neuroimaging studies (Gotman, 2005; Hamandi, 2006; Laufs, 2006; Salek-Haddadi, 2003) and their role in conscious awareness (Faymonville, 2006; Boly, 2008), a recent work (Vaudano, 2009) attempted to elucidate the interaction between these areas and the (frontal)cortical-thalamic loop by means of dynamic causal modeling (DCM) to study effective connectivity based on simultaneously recorded EEG-fMRI data in 7 patients with GSW discharges.

The results of this study are consistent with the concept of the precuneus as a key region that changes its activity with altered states of vigilance, thus influencing the occurrence of generalized seizures: changes in the precuneus state (an increase or decrease in its neuronal activity), which reflects spontaneous fluctuations in awareness, act on the thalamic-(frontal) cortical network, facilitating the development of GSW. This contrasts with previous observations (Gotman, 2005; Hamandi, 2006; Laufs, 2006) that decreases in precuneal activity reflect the semiology of impaired consciousness and are a consequence of GSW.

A similar hypothesis was advanced by Archer et al. (Archer, 2003) who observed a significant posterior cingulate negative BOLD response in 5 IGE patients with interictal GSW discharges but no BOLD signal changes in the thalamus or prefrontal cortex. The authors suggested that decreases in posterior cingulate activity and associated regions may be involved in the initiation of GSW activity.

Additionally, a fMRI study showed a BOLD signal decrease in the posterior cingulate in IGE subjects following photic stimulation whether or not GSW activity occurred, while the control subjects showed no change in this region (Hill, 1999). Such changes would be consistent with a decrease in posterior cingulate activity being a precursor (or facilitator) of GSW activity rather than a secondary phenomenon. The posterior cingulate cortex is adjacent to the precuneus and some authors would define it as part of the precuneal cortical area (Frackowiak, 1997; Frasson, 2008).

Current thinking about the pathophysiology of GSW has it that the neuronal state of the precuneus, and the level of awareness, may reflect a "physiological initiator" of generalized synchronous discharges. In this connection, EEG-fMRI adds electrophysiological data to GSW generation and precuneal involvement where, besides the scant evidence for a strict consequentiality between a particular state of vigilance and the occurrence of GSW discharges, there

is a notable lack of studies on the possible role of cortical structures (particularly the precuneus) other than the thalamus and frontal cortex in GSW.

Unlike surface electrophysiological recordings, fMRI studies with concurrent EEG in patients with GSW discharges have shown common hemodynamic changes not only in the thalamus and frontal cortex, but also in the precuneus and other brain regions (including the fronto-parietal association cortices) of the DMN (Aghakhani, 2004; Archer, 2003; Gotman, 2005; Laufs, 2007). Moreover, fMRI's relatively homogeneous sensitivity across the brain compared to that of scalp EEG may explain why recent EEG-fMRI studies have been able to reveal precuneal involvement in epilepsies characterized by impaired consciousness and associated with GSW (Gotman, 2005; Hamandi, 2006; Laufs, 2006).

In brief, there is an active role in generalized epilepsy for the precuneus, a region previously neglected in electrophysiological studies of GSW. DCM based on EEG-fMRI data has shown that the precuneus is not only strongly connected with the frontal cortex and the thalamus but also that the neuronal activity in this area may facilitate epileptic activity within a thalamo-cortical loop, the existence of which is well established. These findings suggest that GSW may arise through the direct influence of the neuronal state of the precuneus associated with spontaneous changes in the level of awareness.

5. EEG-fMRI in focal seizures: Introduction

5.1. Interictal focal spiked activity correlated BOLD signal changes: Aims and results

EEG-fMRI provides insight into the pathophysiology of changes in the level of awareness during GSW discharges in absence seizures; however, the practical usefulness of technique resides in the study of focal epilepsy, especially if drug resistant and associated with a condition which, if amenable to removal, could achieve seizure freedom or a reduction of frequency. Numerous studies have applied EEG-fMRI to focal seizures to identify the interictal focus and the ictal onset zone (Krakow 1999 and 2001; Boor, 2003; Salek Haddadi, 2006; Bagshaw, 2004 and 2006; Aghakani, 2005; Kobayashi, 2005 and 2006). Some also applied SEEG and electrocortical mapping to study areas previously identified with EEG-fMRI and confirmed co-localization between interictal events (IEDs) and hemodynamic activation detected on fMRI (Krakow, 1999; Kobayashi, 2006; Benar, 2006).

All these studies analyzed patients with spiked activity on focal EEG (spikes, spikes and waves, polyspikes) that differed in frequency. It was then suggested that a limiting factor to obtain sufficient BOLD activation is IED frequency. Two studies (Krakow, 1999 and 2001) proposed 1 IED/minute as the minimum value to obtain sufficient activation. But because a lower frequency does not have sufficient power to stimulate an IED-correlated BOLD signal change, the sensitivity of the technique is very low. More recent studies applied EEG-fMRI to compare the location of IED-correlated BOLD signal change with the resected area and postoperative outcome (Thorton, 2010). Seven out of 10 surgically treated patients were seizure-free following surgery and the area of maximal BOLD signal change was concord-

ant with resection in 6 out of 7 patients. In the remaining 3 patients with reduced seizure frequency post-surgically, the areas of significant IED-correlated BOLD signal change lay outside the resection, thus confirming that the epileptogenic zone (to be removed) is different from the lesional area.

5.2. Interictal focal slow wave activity correlated BOLD changes: The first case reports

Although some studies analyzed focal epilepsies (Liu, 2008), focal slow-wave activity as a marker of activation of cerebral blood flow was initially studied in only two single case reports (Laufs, 2006/a; Avesani 2008/a-b). The one additionally used SEEG to demonstrate co-localization between IEDs and fMRI activation. The second, our case report (Avesani 2008/a), involved a patient with temporal lobe epilepsy (TLE) due to a cavernoma, who had undergone surgical treatment without attaining freedom of seizures. This woman had no medical history of note until the age of 24 years (1975), when symptoms characterized by painful sensations including a lightening stabbing pain developed in the left parietal region of the head, preceded by absence attacks lasting 30 seconds. After seizures she always experienced profound weakness. Her seizures recurred at a variable rate, ranging from more than one a day to one every 10-15 days. During the seizure-free periods she remained healthy. The EEG at that time was negative for an interictal focus. In 1986, when the patient was 35 years old, the EEG disclosed an interictal focus in left temporal regions, characterized by very frequent, and polymorphous, theta-delta activity in association with sharp waves, blocked by eye opening and without contralateral diffusion. Subsequent EEG confirmed the irritative focus in the left fronto-temporal region. When the patient was 37-year-old she began therapy with phenobarbitone (PB) and carbamazepine (CBZ), benefiting from a decrease in seizure intensity (but not frequency). A computed tomographic (CT) brain scan disclosed a mild, non-homogeneous, subcortical hyperdensity on the mesial side of the left temporal lobe, containing rough calcifications with no contrast enhancement. An MRI scan revealed two small lesions in the left temporal lobe, similar to cavernomas (one anterior, in the Sylvian fissure and another posterior, in the paratrigonal region). The patient underwent surgery but the partial seizures remained unchanged. Treatment with PB and CBZ was therefore continued. Twelve years later (2002), another MRI scan revealed three small independent cavernomas in the left temporal lobe (left temporo-basal, left temporo-mesial, and in the left post-central gyrus). A year later (2003), bleeding of the large lesion (localized in the left temporo-basal region) caused the patient to be re-admitted to the neurosurgical ward to undergo a second operation. Despite repeat surgery the seizures continued so she needed further therapy. A following MRI scan (2005), confirmed the presence of the previous cavernomas without bleeding.

Using interictal focus of slow waves recorded in the left temporal region as a trigger of activation (Fig. 1), we obtained activation in the left posterior cortical region around the poroencephalic cavity (residual of previous surgical treatment) (Fig. 2). Our findings confirmed observations by Thorton of 3 patients in whom surgical treatment failed to achieve seizure freedom: in these situations areas of significant IED correlated BOLD signal change lay outside the resection (Thorton, 2010).

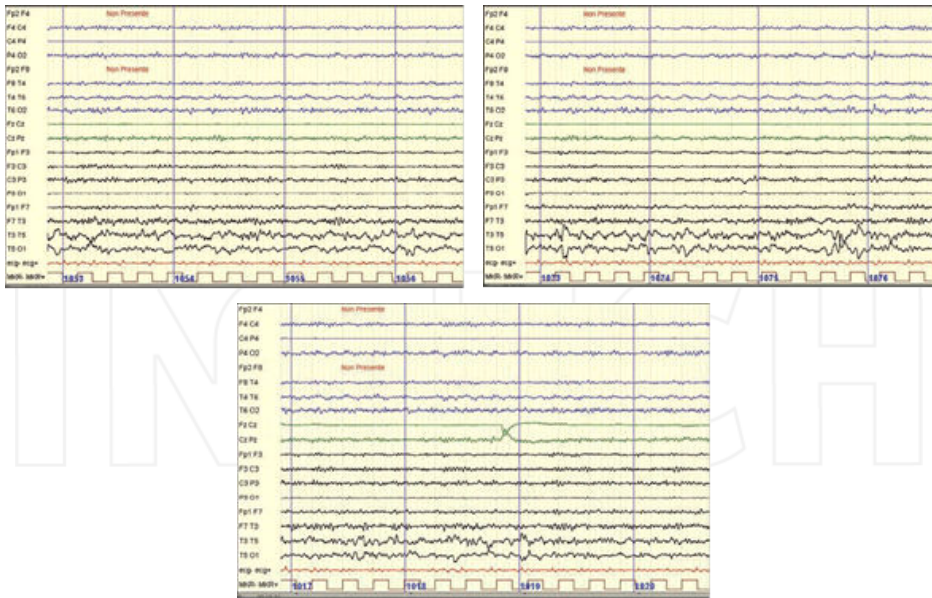


Figure 1. Interictal EEG of patient affected by cavernoma. Focal IEDs in left temporal region

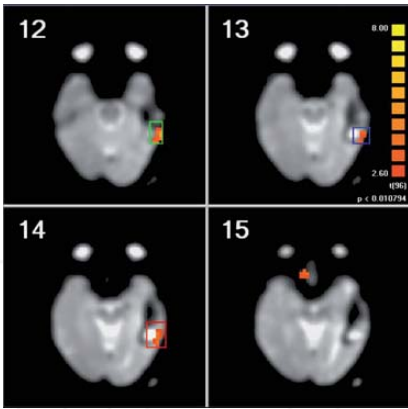
6. EEG fMRI in focal seizures: The first study of interictal slow wave activity correlated bold changes

6.1. Patients enrolled in the study

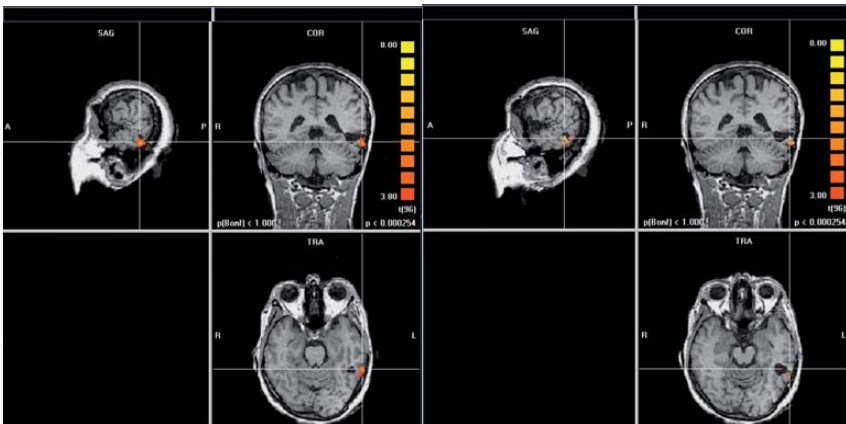
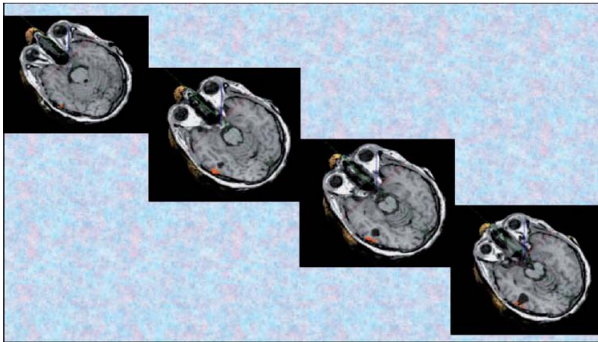
In a previous study involving 8 patients with focal slow-wave interictal discharges on EEG (Manganotti, 2008), we suggested that an IED-correlated BOLD change triggered by interictal slow-wave activity could be obtained if the focal activity is frequent (about 2 IEDs/min). The study was primarily designed to verify whether the interictal slow waves originating from an EEG interictal focus were sufficient to increase cerebral blood flow in a spatially related brain area. To do so, using EEG-fMRI, we investigated BOLD responses to IEDs characterized by focal interictal slow-wave activity in patients with partial epilepsy.

We also wanted to understand whether, in patients with lesional epilepsy, fMRI-BOLD activation areas were correlated with lesions previously identified with standard MRI. We then investigated whether EEG-fMRI could document the spatial relationship between the interictal zone and the ictal onset zone in patients with interictal focal slow-wave discharges arising from a known epileptogenic lesion (i.e., the lesional area).

To obtain a homogeneous study sample, 8 patients with focal epilepsy were selected from among patients hospitalized in our epilepsy ward whose routine EEG recordings showed frequent focal IEDs manifesting as 5-6 Hz focal EEG activity (slow waves, slow spike waves, high-amplitude slow waves), over a few lateralized electrodes. Three of the 8 patients selected



Results of data analysis in 2D reconstruction



Results of data analysis in 3D reconstruction

Figure 2. Interictal focal slow wave activity correlated BOLD activation in patient affected by cavernoma: results of data analysis both in 2D and in 3D reconstruction

for study had a structural lesion on MRI: 2 patients with hippocampal atrophy secondary to mesial temporal sclerosis (MTS) and 1 patient with a cavernous angioma. Among the remaining 5 patients, 1 patient had cryptogenic epilepsy and 4 patients had nonlesional (idiopathic) epilepsy. Routine EEG showed slow-wave activity in 1 patient with MTS (P4), the patient with cryptogenic epilepsy (P2) and the one with idiopathic epilepsy (P7); slow spike waves were observed in the patient with a cavernoma (P3) and the 2 patients with idiopathic epilepsy (P5 and P8); high-amplitude slow-waves ($> 130 \mu\text{V}$) were noted in 1 patient with idiopathic epilepsy (P6) and the second patient with MTS (P1) (Table 1).

Patients	Type of Epilepsy	Standard MRI findings	IED morphology	Irritative focus
1	Lesional	MTS	HASW	T3-T5
2	Cryptogenic	Negative	SW	T3-T5
3	Lesional	Cavernoma	SPSW	T5
4	Lesional	MTS	SW	T4-T6
5	Idiopathic	Negative	SPSW	O1
6	Idiopathic	Negative	HASW	T4-T6
7	Idiopathic	Negative	SW	F7
8	Idiopathic	Negative	HASPSW	T4-T6

MTS denotes mesial temporal sclerosis; SW slow waves; HASW high-amplitude slow waves; SPSW spiked slow waves; HASPSW high-amplitude spiked slow waves.

Table 1. Patients enrolled in the first study (Manganotti, 2008).

The good results we obtained (BOLD activations correlated to IEDs in 8/8 patients) allowed us to extend the study to 8 other patients (for a total of 16 patients), all with the same characteristics: focal epilepsy in which routine EEG recordings showed frequent focal IEDs manifesting as 5-6 Hz focal EEG activity (slow waves, slow spike waves, high-amplitude slow waves) over a few lateralized electrodes. The results did not change. MRI revealed a structural lesion in 4 patients: MTS in 2, tuberose sclerosis (TS) in 1; and hypothalamic hamartoma (HH) in 1. Three patients had cryptogenic and one nonlesional (idiopathic) epilepsy.

Standard EEG showed: focal sharp-wave activity in 1 patient (P15) with idiopathic epilepsy; high-amplitude slow-wave activity (or high-amplitude sharp waves) in 1 with TS (P12) and in 1 with HH (P14); spiked sharp waves in 1 with MTS (P10) and in 2 patients with cryptogenic epilepsy (P13 and P16); and high-amplitude spiked waves in 1 with MTS (P9) and in 1 with cryptogenic epilepsy (P11) (Table 2).

Patient	Type of epilepsy	Standard MRI findings	IED morphology	Irritative focus
9	Lesional	MTS	HASPSW	T8
10	Lesional	MTS	SPSW	F7-T3
11	Cryptogenic	Negative	HASPSW	F7-T3
12	Lesional	TS	HASW	P4
13	Cryptogenic	Negative	SPSW	T6
14	Lesional	HH	HASW	T4-T6
15	Idiopathic	Negative	SW	T3-T5
16	Cryptogenic	Negative	SPSW	F8-T4

Table 2. Characteristics of the 8 additional patients. MTS denotes mesial temporal sclerosis; TS tuberose sclerosis; HH: hypothalamic hamartoma.

6.2. Materials and methods

6.2.1. EEG recordings and analysis

The EEG was acquired using a MR compatible EEG amplifier (SD MRI 32, Micromed, Treviso, Italy) and a cap providing 32 Ag/AgCl electrodes positioned according to a 10/20 system (impedance was kept below 10 k Ω). To remove pulse and movement artifacts during scanning two of these electrodes were used to record the electrocardiogram (ECG) and electromyogram (EMG). The EMG electrode was placed on the right abductor pollicis brevis (APB) muscle and the other (ECG) on the precordial area.

The reference was placed anterior to Fz, and the ground posterior to Fz as in other studies (Gonçaves et al. 2006; Avesani et al. 2008/a; Formaggio et al., 2008; Manganotti et al. 2008) using the same system. To ensure subjects' safety, the wires were carefully arranged to avoid loops and physical contact with the subject. To minimize the variability in the EEG artifacts due to the MR sequence and avoid wire movement caused by mechanical vibration the wires rested on foam pads.

EEG data were acquired at the rate of 1024 Hz using the software package SystemPlus (Micromed, Treviso, Italy). To avoid saturation, the EEG amplifier had a resolution of 22 bits with a range of ± 25.6 mV. An anti-aliasing hardware band-pass filter was applied with a bandwidth between 0.15 and 269.5 Hz. Details of the EEG recording method are given in Bènar (Bènar et al, 2003). The EEG artifact induced by the gradient magnetic field was digitally removed off-line by an adaptive filter (Micromed). EEG artifacts associated with pulsatile blood flow were digitally removed off-line using a simple averaging procedure (Allen, 1998-2000). Subsequently a single electroencephalographer visually reviewed the filtered EEGs, and marked the time of onset and duration of each IED.

6.2.2. fMRI acquisition and analysis

Images were acquired on a 1.5 T MR scanner (Symphony, Siemens, Erlangen, Germany) equipped with EPI capability and a standard transmit/receive (TR) head coil. At the start of

each study, a T1-weighted anatomical MRI was acquired (192 slices; FOV = 256X256; scanning matrix 512X512; slice thickness 1 mm; sagittal slice orientation; echo time (TE) = 3ms; repetition time (TR) = 1990 ms).

All patients then underwent a 24-min fMRI recording session, after giving informed consent. BOLD fMRI data were acquired, using a standard gradient-echo (EPI) sequence, on the axial orientation, in 1 run of 8 minutes with the patient in the resting state, as described by the Kobayashi team (Kobayashi,2006) (voxel dimension 3x3x3 mm; 36 slices; matrix 64x64; TE = 50 ms, TR = 3.7 s; and slice thickness = 3 mm). At the onset of each fMRI acquisition, the scanner provided a trigger signal that was recorded by the EEG system and used as a volume marker.

For image processing and statistical analysis of the fMRI time series data we used BrainVoyager QX 1.9 software (*Brain Innovation, Maastricht, Netherlands*) running in windows VISTA environment. Pre-processing of the functional MRI included three-dimensional motion correction, slice scan time correction (linear interpolation), linear trend removal by temporal high-pass filtering (3 cycles in time course) and transformation into the Talairach coordinate space. Neither spatial nor temporal smoothing was used.

In each subject, activated voxels were identified with a single-subject general linear model (GLM) approach for time series data (Friston, 1995). To account for the hemodynamic delay, the boxcar waveform representing the rest and task conditions was convolved with an empirical hemodynamic response function (Friston, 1998).

A t statistic was used to determine significance on a voxel-by-voxel basis and correlation values were transformed into a normal distribution (Z statistic). The results were displayed on parametric statistical maps in which the pixel Z value is expressed on a colorimetric scale. We identified the single region of condition-associated BOLD signal changes with a statistical threshold based on the amplitude ($p < 0.05$) and extent of the regions of activation. The location of voxels with maximal signal increase was expressed in terms of x, y, and z in the Talairach space, and activation volumes were expressed in terms of number of activated voxels. Positive BOLD-fMRI responses were defined as activations. Significant responses were defined as almost five contiguous voxels with $p < 0.05$ over at least two contiguous slices (Krakow 1999 and 2001; Salek-Haddadi 2006) in 2D-reconstruction. The anatomic localization of BOLD responses was determined by co-registration of the anatomic data and statistical t maps.

We analyzed the extent and maximum fMRI response for each study, considering all areas with significant activations. We also determined the locations of maximum activation based on the maximum peak response (maximum t value).

6.3. Results

In all patients, EEG showed unilateral focal activity during the EEG-fMRI session. IEDs recorded inside the scanner had a localization, amplitude and morphology similar to those seen in the previous routine EEG recordings. EEG recordings showed focal high-amplitude slow waves in 4 patients (P1, P6, P12 and P14), and slow-wave discharges over the temporal electrodes in the other 3 patients (P2, P4 and P15). In 1 patient (P7) slow-wave activity was detected in the extratemporal (F7) region. In the patient with a cavernoma (P3), in 1 with MTS

(P10), and in 2 patients with cryptogenic epilepsy (P13 and P16), focal EEG activity was characterized by focal slow-spiked wave activity, reaching maximal amplitude over the left temporal electrodes (T5). In 1 patient (P5) slow-spiked waves were detected in the extratemporal region (left occipital region). The EEG tracings also showed high-amplitude spiked slow-wave activity in 3 patients (P8, P9 and P11): in the right temporal region in 2 (P8 and P9) and in the left fronto-temporal region in 1 patient (P11).

The mean frequency was 2.4 IEDs per minute (SD 0.17) for the first 8 patients and 2.495 for the second 8 patients, thus confirming sample homogeneity.

In all 8 patients from the first study and in 7/8 from the second study, fMRI analysis showed, in 2-D reconstruction, significant focal BOLD activation in a single activated area related to the EEG irritative focus (Tables 3 and 4). This activation was considered significant (Krakow, 1999) because it was identified in two contiguous MRI slices.

Patient	IEDs/24 min	IEDs/min	BOLD activation in 2D reconstruction	No. of slices
1	61	2.54	Left mesial temporal lobe	2
2	55	2.29	Left mesial temporal lobe	2
3	54	2.25	Left superior temporal lobe – neocortical region	3
4	58	2.41	Right mesial temporal lobe	2
5	64	2.66	Left occipital lobe-calcarin cortex	2
6	51	2.13	Right superior temporal lobe	2
7	58	2.41	Left frontal lobe	2
8	62	2.58	Right superior temporal lobe	2

Table 3. Number of IEDs revealed on EEG during recording and BOLD activation in 2D reconstruction of fMRI, with number of contiguous activated slices.

Patient	IEDs/24 min	IEDs/min	BOLD activation in 2D reconstruction	No. of slices
9	57	2.38	Left mesial temporal lobe	3
10	57	2.38	Left mesial temporal lobe	3
11	59	2.45	Left supplementary motor cortex	5
12	62	2.59	Right parietal lobe	3
13	64	2.66	Right mesial temporal lobe	2
14	65	2.70	Right mesial temporal lobe	2
15	53	2.20	====	0
16	63	2.60	Left mesial temporal lobe	2

Table 4. Number of IEDs revealed on EEG during recording and BOLD activation in 2D reconstruction of fMRI, with number of contiguous activated slices, in the second study of 8 patients.

This result was confirmed with analysis of 3D reconstruction of fMRI: in all 8 patients from the first study (Manganotti, 2008) and in 7/8 from the second study, fMRI BOLD activation corresponded to the irritative focus on standard EEG recordings (Tables 5 and 6).

Patient	No of voxels	Corresponding area in 3D reconstruction
1	177	Left cerebrum, limbic lobe, parahippocampal gyrus, Brodmann area 34
2	522	Left cerebrum, limbic lobe, parahippocampal gyrus, Brodmann area 30
3	540	Left cerebrum, temporal lobe, inferior temporal gyrus, Brodmann area 20
4	175	Right cerebrum, limbic lobe, parahippocampal gyrus, Brodmann area 28
5	1227	Left cerebrum occipital lobe, lingual gyrus, Brodmann area 18
6	364	Right cerebrum, temporal lobe, transverse temporal gyrus, Brodmann area 42
7	442	Left cerebrum, frontal lobe, precentral gyrus, Brodmann area 6
8	422	Right cerebrum, temporal lobe, middle temporal gyrus, Brodmann area 21

Table 5. Number of activated voxels, and localization, according to the Talairach system, of activated regions in 3D reconstruction, of the 8 patients from the first study (Manganotti, 2008).

Patient	No. of voxels	Activation in 3D reconstruction
9	368	1) Right cerebrum, temporal lobe, superior temporal gyrus Brodmann area 38 2) Right cerebrum, frontal lobe, mesial frontal region Brodman area 10
10	350	Left cerebrum, temporal lobe, fusiform gyrus Brodmann area 20
11	322	Left cerebrum, frontal lobe, supplementary motor cortex Brodmann area 6
12	52	Right cerebrum, parietal lobe, precuneus Brodmann area 7
13	256	Right cerebrum, temporal lobe, superior temporal gyrus Brodmann area 38
14	200	Right cerebrum, anterior cingulate, limbic lobe Brodmann area 32
15	0	=====
16	150	Right cerebrum, parahippocampal gyrus, limbic lobe Brodmann area 34

Table 6. Number of activated voxels, and localization, according to the Talairach system, of activated regions in 3D reconstruction, of the 8 patients from the second study.

6.3.1. Temporal lobe activation

Focal BOLD signal changes in 11 patients reached statistical significance in the temporal regions. In 10 patients (4 of which with MTS [P1, P4, P9, and P10]; 1 with HH [P14]; 3 with cryptogenic epilepsy [P2, P13, and P16]; in 2 of the 4 with idiopathic epilepsy [P6 and P8]), the significant BOLD changes were located in the mesial temporal lobe and in the neocortical regions (laterally and posteriorly to the resection margins) in the 1 patient with a cavernoma (P3).

An interesting case of surgically treated mesial temporal sclerosis involved P9. Of Moroccan origin, he has suffered from focal seizures since the age of 6 years, with loss of consciousness and oral and motor automatisms of the legs (pedaling) and arms, preceded by an epigastric aura, lasting 1 minute and resistant to therapy. On MRI, right mesial temporal sclerosis (MTS) was detected (fig.3). Standard EEG demonstrated an interictal focus in the right temporal region. The seizures first occurred rarely but then increased in frequency with time, eventually manifesting in “clusters” of 10-15 seizures every 1 to 2 months. Auras occurred every 2 weeks. Video-EEG demonstrated the same abnormal activity in the right temporal region, with an ictal event manifesting with the same characteristics. The hypothesis was that the seizures arose in an epileptogenic area related to the known MTS and then spread anteriorly to the right mesial frontal region (cause of motor manifestation). EEG-fMRI recording session identified an interictal slow wave activity in right temporal region (T4-T6), with a following diffusion both to contralateral region and to right frontal region (fig. 4). Two significant activations were detected (fig. 5-6): one in the right mesial temporal region (Brodmann area 38) and one in the right mesial frontal region (Brodmann area 10). Also in this case, BOLD activations were concordant with focal IEDs and with clinical syndrome. On subsequent analysis with invasive techniques (SEEG), the origin of seizure in an epileptogenic zone correlated with MTS was confirmed, with spread to the right mesial frontal region. The study also confirmed the colocalization between EEG and fMRI data. He was surgically treated and is now seizure free.

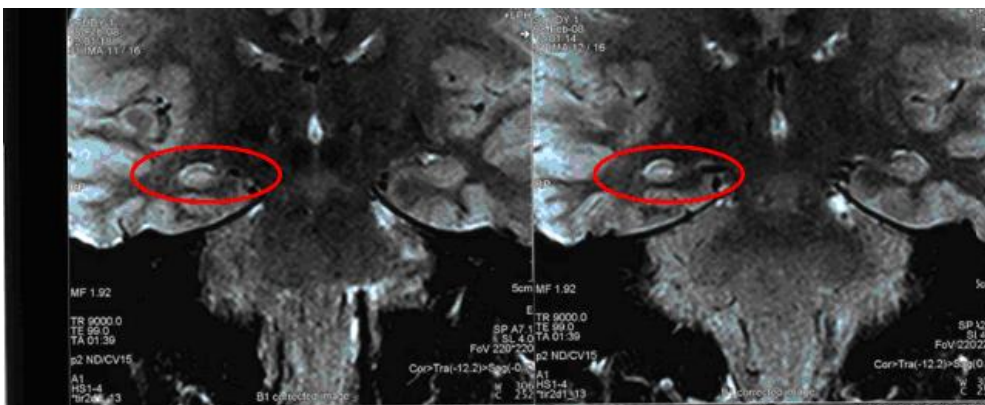
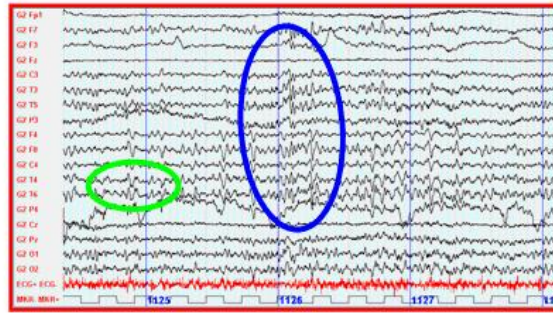


Figure 3. Right mesial temporal sclerosis (MTS) in Patient n. 9



EEG recorded during scanning session (monopolar montage)

 Irritative focus


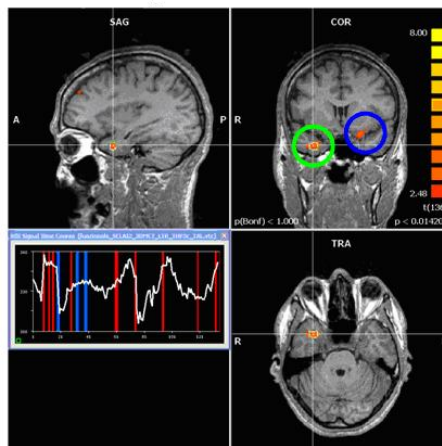

 Contralateral diffusion

Figure 4. Patient n. 9. Focal IEDs in right temporal region, with following diffusion both to contralateral region and to right frontal region



 Activation related (omolateral) to focal IEDs


 Contralateral activation (related to contralateral diffusion of irritative focus)

Figure 5. Patient n. 9. Focal IEDs correlated BOLD activations in mesial right temporal region, with following diffusion to contralateral region

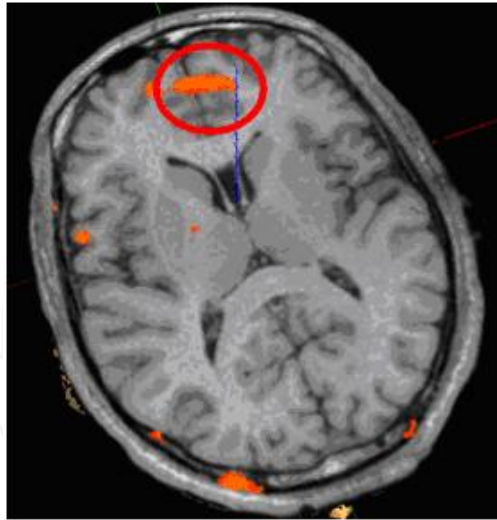


Figure 6. Patient n. 9. Focal IEDs correlated BOLD activation in right mesial frontal region

Another case involved a young man (P14) affected with gelastic seizures due to a hypothalamic hamartoma and manifesting since he was 2 years old. They were well defined: dissociated deviation of the eyes (the left eye toward the right and the right eye upwards) or associated deviation of both eyes upwards, followed by right head deviation, absent facial expression, and asymmetric smile. Often, an aura (tingling in the left temporal region) would precede the seizures, with concurrent rubor. The patient attempted to speak but was impeded by fixed smiling. The episode frequency was very high (up to 5 seizures/day). Over time, the syndrome worsened, with falls and subsequent injuries. SEEG confirmed an epileptogenic zone inside the hamartoma, with spread to the right mesial temporal region during the seizures. EEG-fMRI detected a significant BOLD activation in the limbic lobe (anterior cingulate), substantiating the anatomic-clinical correlation suggested by seizures and EEG.

This case parallels recently published findings on the networks involved in seizure generation in hypothalamic hamartoma (Kokkinos, 2012). EEG-fMRI was performed in 2 adult patients with hypothalamic hamartoma, the one with predominantly gelastic seizures and the other with complex partial but no typical gelastic seizures. Ictal and interictal analysis of the patient with gelastic seizures revealed involvement of the hypothalamic hamartoma, the cingulate gyrus, the precuneus and prefrontal cortex. The interictal analysis of the patient with complex partial seizures showed BOLD signal changes over the temporal lobes, the base of the frontal lobe, the precuneus and prefrontal cortex but not the hypothalamic hamartoma. It was presumed that the differences in the neural networks implicated may have accounted for the differences in the clinical manifestation of seizures owing to the tumor.

Other interesting cases are cryptogenic (P2, P13) and idiopathic forms (P6, P8, P15), all characterized by atypical absences and vagal symptomatology. In patient n. 2, focal IEDs (fig.

7) were recorded in left temporal region and focal IEDs correlated BOLD activation (fig. 8) was detected in mesial left temporal region, in limbic lobe. In patient n. 6 focal IEDs were recorded in right temporal region, with a characteristic phase reversal in T4 (fig. 9), and focal IEDs correlated BOLD activation was detected in Brodman area 42 (fig. 10). In patient n. 8, focal IEDs were recorded in right temporal region (fig. 11) and focal IEDs correlated BOLD activation was detected in Brodman area 21 (fig. 12).

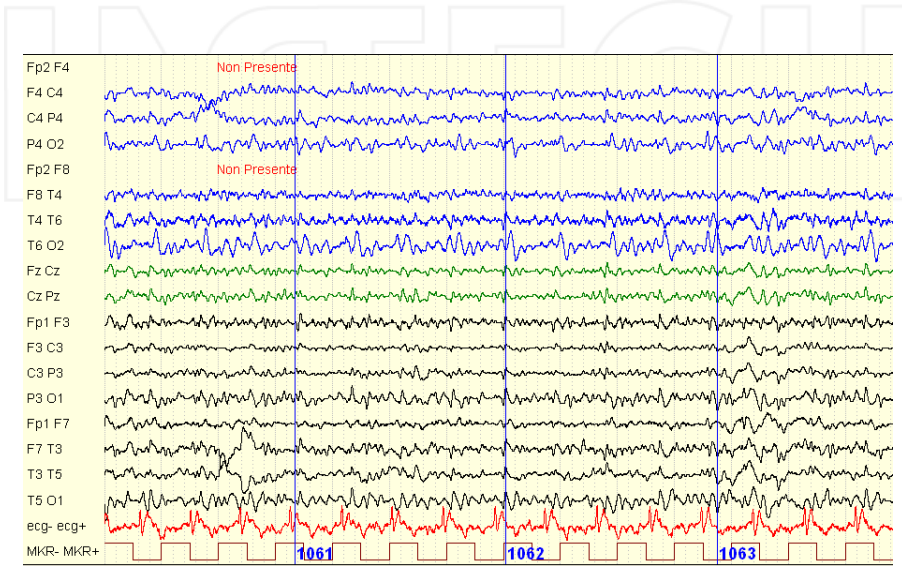


Figure 7. Patient n. 2 (cryptogenic epilepsy). Focal IEDs in left temporal region during scanning session

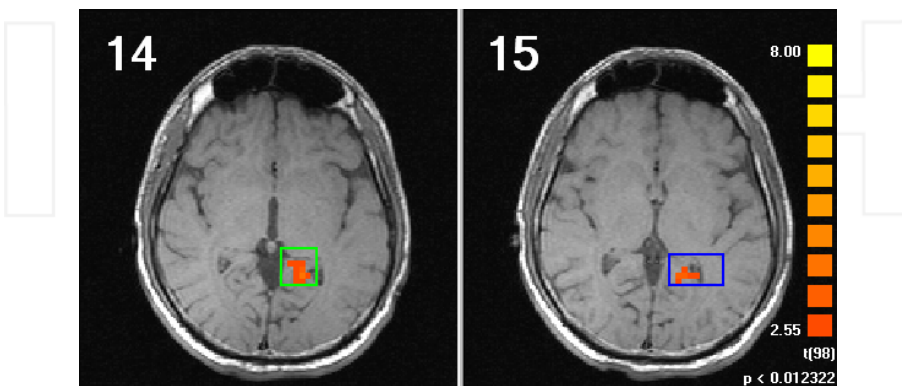


Figure 8. Patient n. 2. Focal IEDs correlated BOLD activations in left mesial temporal lobe

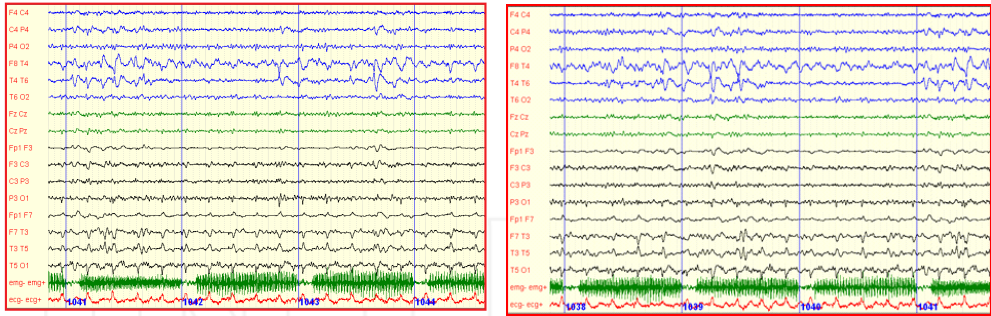


Figure 9. Patient n. 6. Focal IEDs in right temporal lobe with phase reversal in T4

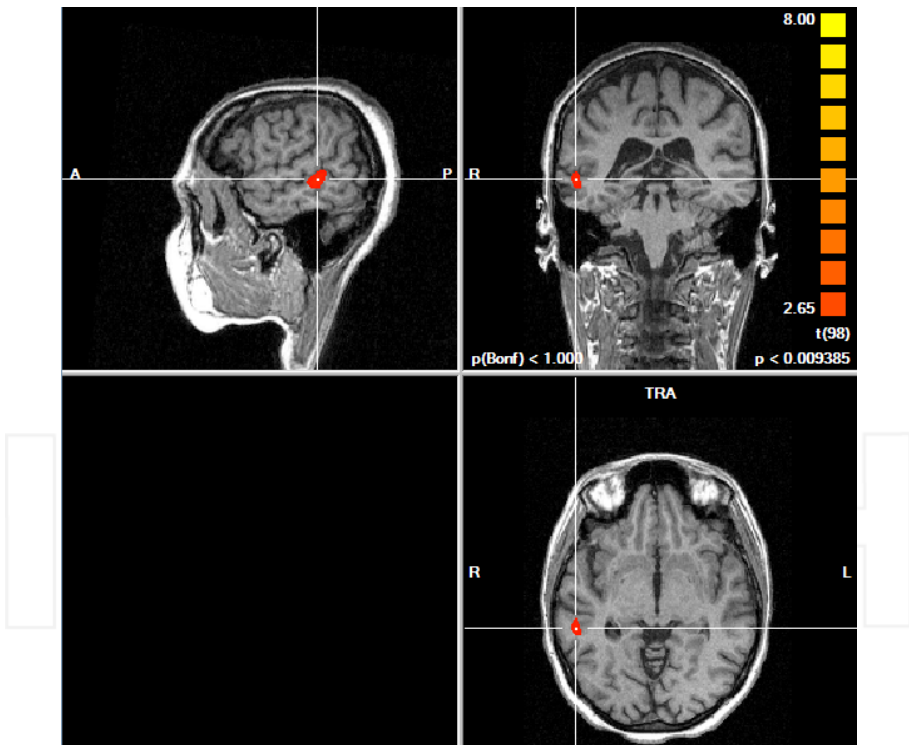


Figure 10. Patient n. 6. Focal IEDs correlated activation in transverse temporal gyrus, Brodmann area 42

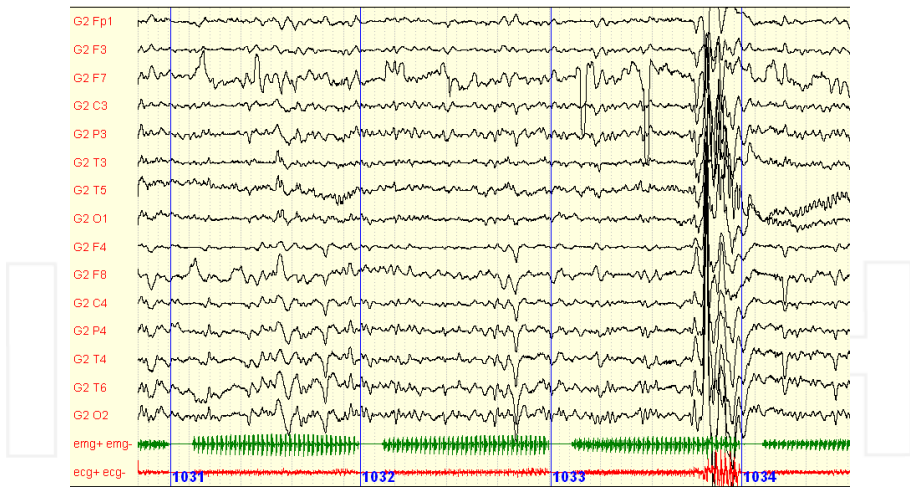


Figure 11. Patient n. 8. Focal IEDs in right temporal region

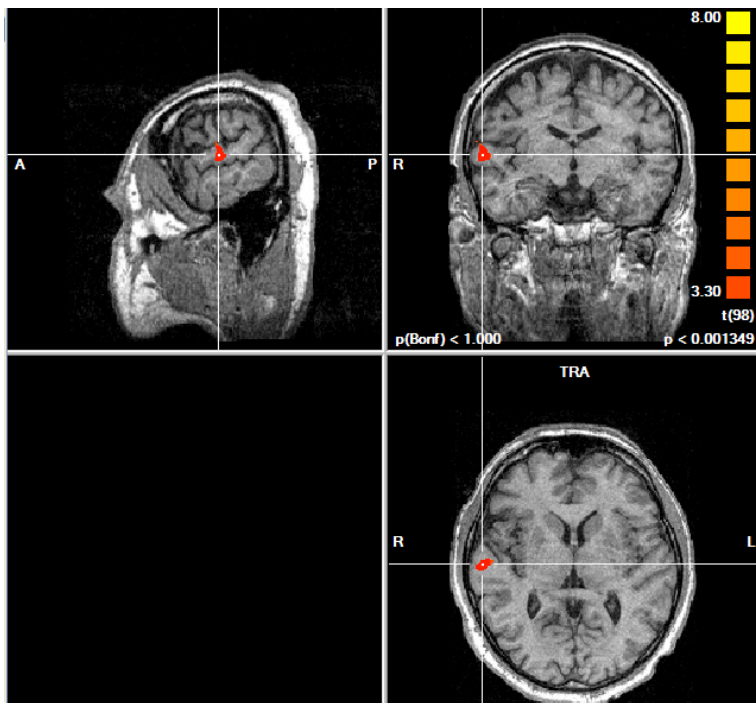


Figure 12. Patient n.8. Focal IEDs correlated BOLD activation in middle temporal gyrus, Brodmann area 21

6.3.2. Extratemporal activation

In our series, fMRI showed extratemporal activation in 4 patients: the left occipital lobe (P5); the left frontal lobe (P7); the left supplementary motor cortex (P11); and the right parietal lobe (P12). In all four cases there was a correlation between BOLD activation and IEDs and with clinical syndromes as well. This correlation is relevant to the discussion about the technique's sensitivity in revealing activation in extratemporal regions.

A rare case (P5) involved non ketotic hyperglycemia (NKH)-induced seizures occurring in the left occipital lobe studied by EEG-fMRI (Del Felice, 2009). These seizures usually occur in the frontal regions and cause motor ictal syndromes, whereas occipital seizures have been described in very rare situations. Cases of NKH presenting as hemichorea or hemianopia have also been reported. Seven such patients (Seo, 2003; Raghavendra, 2007) were studied by standard MRI transient T₂-weighted and fluid-attenuated inversion recovery (FLAIR). Subcortical hypointensity with or without abnormalities in the occipital overlying cortex or striatal nuclei was documented in occipital seizures associated with NKH. A single case investigated by Tc-99m HMPAO SPECT (Wang, 2005) showed occipital hyperperfusion during seizure recurrence and hypoperfusion during the interictal state.

Our patient (P5) was a 50-year-old woman admitted to hospital after repeated emergency room visits because of visual disturbances and left-sided headache. On clinical examination, she was obese and had a right-sided homonymous hemianopia. Her medical history was unremarkable, except for hypertension and a 15-kg weight gain during the past 12 months. She had no history of migraine, epilepsy or neurological disorders. Two days before admission she reported a short-lasting episode of visual disturbance (distortion). A few hours later, she noted diplopia when looking to the right, with image distortion in the right visual field and intermittent right-sided hemianopia, lasting several minutes, elicited by looking to the right or by fixation. The episodes were accompanied by a left-sided throbbing headache but no other autonomic symptoms (i.e., nausea or vomiting). No language disturbance was reported. She was presented to the emergency room.

On neurological examination, a right-sided homonymous hemianopia was noted. A standard computed tomography (CT) scan of the brain and an ophthalmologic exam were negative. She was discharged with a diagnosis of migraine with aura and started on antiplatelet therapy, with the recommendation to undergo out-patient visual field analysis.

Two days later, she was admitted to our ward owing to the persistence of symptoms, including a transient conjugated deviation of the eyes and the head to the right. On that occasion, which lasted less than 1 minute, the patient did not lose consciousness and referred seeing red flashing lights in her right visual field. Standard EEG performed immediately thereafter showed multiple clinical-EEG seizures during a prolonged recording, with spiked slow waves originating from the left posterior region, and with bilateral diffusion (fig. 13). Laboratory data on admission revealed hyperglycemia (14.5 mm/L to 261 mg/dL) with a serum osmolality of 333 mmol/kg, and glycosylated hemoglobin of 10.5%. Urine analysis was negative for ketone bodies but was strongly positive for glycosuria (>1 g/dL) and microalbuminuria (up to 6 mg/24 h). A brain MRI scan with and without gadolinium, an MR angiography, and a 3T brain

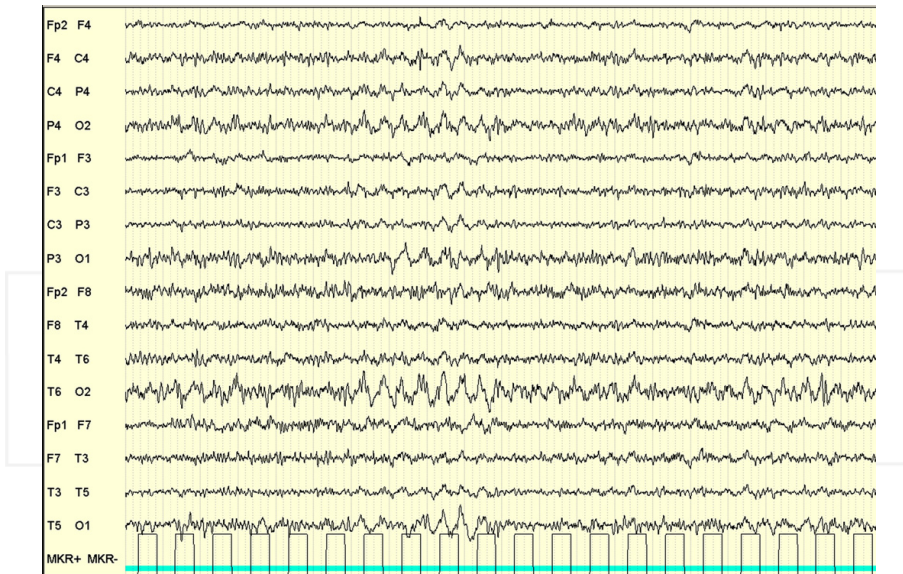


Figure 13. Patient n. 5. Standard EEG tracing during clinical seizures. Spiked slow waves on posterior regions (O1 and O2).

MRI were normal. Tc-99m hexamethylpropylene amine oxime (HMPAO) single-photon-emission computed tomography (SPECT), during which no clinical seizures were reported, showed non-significant hypocaptation over the posterior regions bilaterally.

On continuous EEG-fMRI a few days later, no clinical or EEG manifestations of ictal events occurred, but interictal spiked slow wave discharges (IEDs) with localization, amplitude and morphology similar to those previously recorded on routine EEG (fig. 13) were noted. A slow-spiked wave on the left occipital (O1) channel was detected. The mean frequency was 2.4 IEDs per minute. Functional MRI analysis showed significant focal BOLD activation in a single area related to the EEG paroxysmal activity. In a 3D reconstruction using the Talairach system (fig. 14), focal significant BOLD activation based on the EEG-related protocol was identified in Brodmann area 18 (grey matter of the left cerebrum occipital lobe and lingual gyrus). During her hospital stay, she was started on carbamazepine (200 mg/daily, up to 800 mg t. d.), with only partial benefit in frequency and intensity of symptoms. Since her glycemia was still uncontrolled (250 mg/dL), she was started on insulin therapy. Over the following 2 weeks, seizures and hyperglycemia both progressively decreased. On the basis of a possible diagnosis of NKH-induced seizures, carbamazepine was tapered, without the reappearance of symptoms. Serial EEG showed a decrease in epileptic activity (sharp waves) with persistent bilateral slowing. A few weeks later, insulin therapy was replaced with oral antidiabetics. One year later, the patient was seizure free, with a normal EEG. Following the loss of 18 kg, the oral antidiabetics were tapered, with good control of serum glucose and HbA1 values.

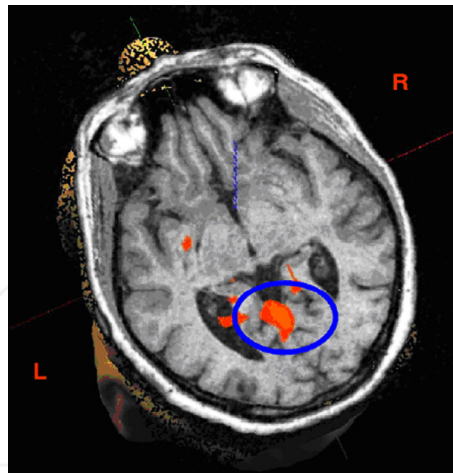


Figure 14. Patient n. 5. 3D fMRI-BOLD activation in Brodmann area 18.

A BOLD occipital activation in patients referring visual symptoms has been reported, confirming the involvement of visual functional areas in the occipital lobes: Brodmann areas 19 and 37 in reported cases of fixation sensitivity occipital spiking (Iannetti et al., 2002; Avesani, 2008/b) or the left occipital lobe in cases of cryptogenic and symptomatic (cortical malformation) occipital epilepsy (Salek-Haddadi et al., 2006). In our patient, an analogous BOLD activation was elicited by the NKH. Hyperglycemia may induce paroxysmal activity in brain areas more susceptible to metabolic changes – the occipital lobe in this case - with an analogous pattern of activation of self-sustained focal discharges. Neuroimaging, in this case fMRI-EEG co-registration, pointed to a change in blood volume in the involved posterior areas.

In the patient (P7) in whom fMRI revealed BOLD activation in the left frontal region (Brodmann area 6), standard EEG showed a left fronto-temporal irritative focus characterized by frequent slow-spiked waves. A recent polygraphic study (recorded during stage I and II non-rapid-eye-movement [NREM] sleep) showed polymorphic slow waves (theta-delta) in the left frontal regions, with phase inversion at F7 and without spread. These findings suggested that the patient was a good candidate for an EEG-fMRI study. During the EEG-fMRI sessions, we confirmed the fMRI activation area within the precentral gyrus.

Patient no. 11, a young woman, illustrates an interesting case of frontal lobe epilepsy characterized by focal seizures, with speech arrest and right arm clonus followed by generalization (Borelli, 2010), where, as reported elsewhere (So, 1998; Westmoreland, 1998), scalp EEG is often ambiguous because it is poorly sensitive to deep generators on the mesial surface of the frontal lobe. Also in this instance, EEG-fMRI effectively identified the interictal focus.

According to a detailed account by relatives, the events took the form of sudden episodes of speech arrest lasting from a few seconds up to several minutes, without any warning sensation. The patient reported she was able to move, understand and write properly during the ictal

phase (sometimes writing a note to her husband that she was unable to speak). No clonic movements or orofacial automatisms were experienced at this early stage. Usually, an event did not progress any further and the patient was able to fully recollect the episode. Sometimes an episode was followed by clonic jerking over the right side of the face and arms with occasional, generalized tonic-clonic seizures. The seizure frequency was weekly despite polytherapy. The 3T MRI was normal. She reported no febrile seizures nor having sustained significant head injuries. Pregnancy, delivery and developmental milestones were unremarkable, as was the remainder of her medical history. Trials with various antiepileptic drugs (first with diltiazem, then carbamazepine, and then phenobarbital) were unsuccessful. She was admitted to an intensive care unit for a status epilepticus and begun on valproate and lamotrigine.

Interictal scalp EEG showed frequent generalized high-amplitude (2 to 3 Hz) spiked slow-wave discharges. There was an inconstant, mild amplitude prevalence over the left hemisphere electrodes (F7-T3).

During a conventional scalp EEG recording, she complained of a brief episode of speech arrest associated with an EEG pattern characterized by diffuse spike and wave discharges (fig. 15). This event was witnessed by a neurologist from our ward who was aware of the patient's clinical history. He noted that the patient had a brief inability to speak (a few seconds) during which she waved her hands to attract his attention. There were no clonic movements, and after regaining speech, she accurately described the event. Three-hour video-EEG monitoring during a day of seizure clustering recorded no usual events. On the basis of these elements, a diagnosis of generalized epilepsy was also made in another hospital.

The clinical syndrome suggested involvement of the left supplementary motor area (SMA) with spread to the primary motor area. EEG -fMRI recording session confirmed the same pattern EEG identified by standard EEG (fig. 16) and following analysis showed prominent BOLD activation over the left SMA during the high-amplitude spiked slow-wave discharges compared to the rest state (Fig. 17). According to the Duncan criteria, such an activation pattern is reproducible since it was present in two contiguous slices (Duncan, 1999). The statistical significance of the activation was $p < 0.0028$ even after FDR correction. More activations were found in the contralateral SMA and homolateral motor strip as well. No significant deactivation areas or thalamic involvement (activation or deactivation) were found. The patient was referred to a level II epilepsy surgery center for presurgical work-up, including long-term video-EEG monitoring, but she refused further testing.

The speech arrest noted in this patient is an epileptic feature usually related to involvement of the supplementary motor cortex over either the dominant or the non-dominant hemisphere. A bilateral spike and wave discharge pattern (secondary bilateral synchrony) is often detected in frontal-lobe epilepsy, particularly if the generator is deep, for instance, over the mesial surface of the frontal lobe (So, 1998; Westmoreland, 1998). In the presurgical work-up for epilepsy surgery, such a scalp EEG pattern certainly raises questions about the origin of the focal epilepsy especially when conventional MRI is negative. In the latter case, more investigations are usually obtained to guide depth electrode placement for invasive EEG. Ictal SPECT and interictal PET are commonly used for this purpose, but they are expensive, difficult to interpret, and usually provide regional rather than local data. In addition, if the ictal event is

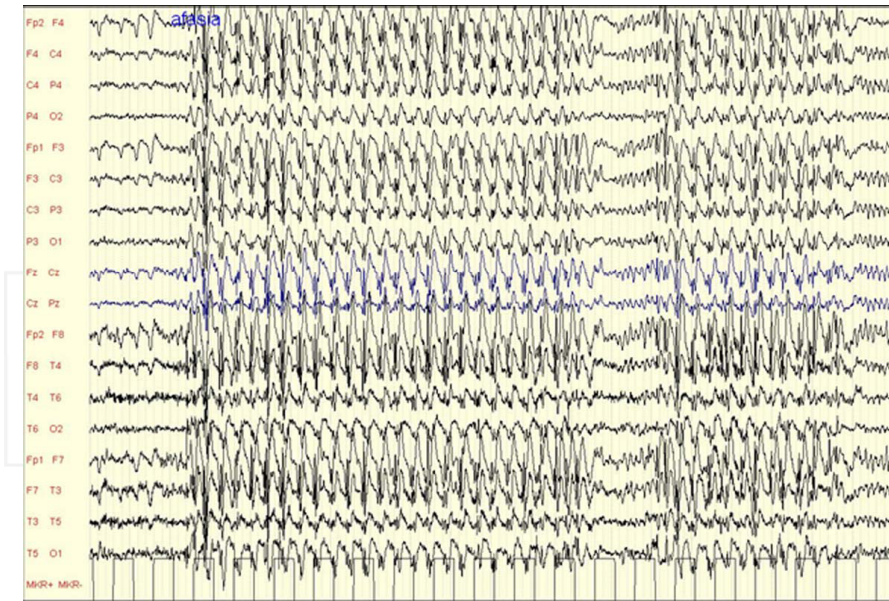


Figure 15. Patient n. 11. Ictal EEG during a brief speech arrest episode ("Afasia" marks the beginning of the speech impairment).

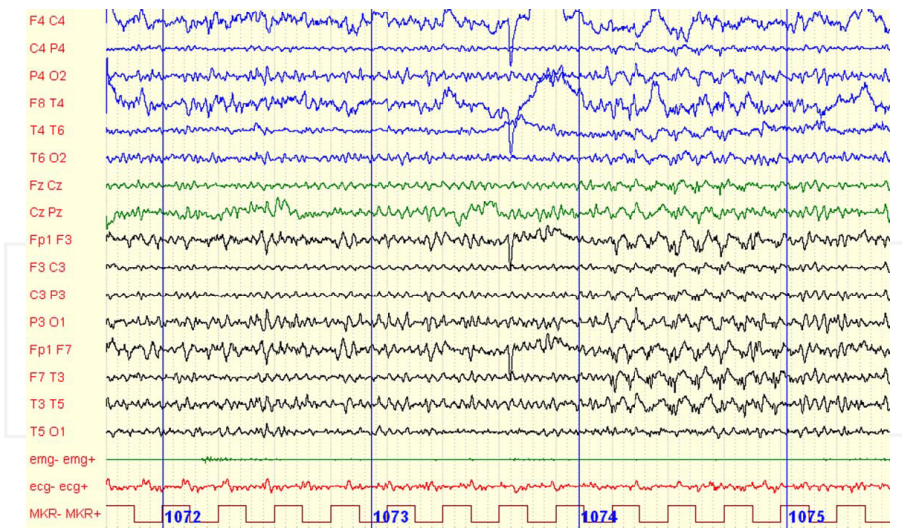


Figure 16. Patient n.11. EEG recorded during the fMRI acquisition showing generalized high amplitude spiking slow wave discharges, prevalent on left fronto-temporal regions.

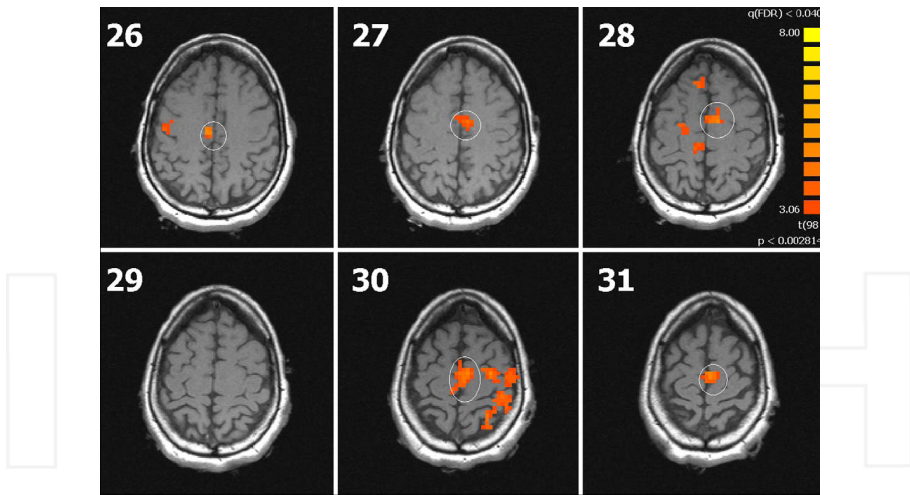


Figure 17. Patient n. 11. The EEG-fMRI shows a clear-cut activation of the left (radiological convention) Supplementary Motor Area (SMA) and on the contralateral SMA on a lesser degree. Spread over the left motor strip is also evident.

brief, SPECT may yield false negatives due to incorrect timing of the tracer injection (Salmenpera, 2005; Devous, 1998). The use of radioactive substances also raises safety issues.

A relatively new tool to obtain localizing data on the basis of EEG changes, EEG-fMRI is safe for the patient and relatively inexpensive (Al Asmi, 2003; Di Bonaventura, 2006). As our knowledge about the technique increases, it is gaining acceptance in the study of focal nonlesional epilepsy and presurgical work-up, as reported by Moeller et al. and Zijlmans et al. (Devous, 1998; Moeller, 2009). Nonetheless, few studies to date have applied EEG-fMRI in patients with secondary bilateral synchrony, except for one by Aghakhani (Aghakhani, 2006) involving 11 patients with such an EEG pattern, with a variable activation-deactivation pattern including thalamic involvement in 6 out of 11 (55%). The clinical seizure pattern and the MRI findings were variable.

In our patient, EEG-fMRI revealed the origin of the epileptiform discharges, including the spread over the homolateral motor strip, which was highly consistent with the patient's clinical features (speech arrest followed by clonic jerks over right half of the face and right arm), whereas 3T MRI and conventional interictal scalp EEG were useless in this regard. Some involvement of the contralateral SMA was also detected but its significance is less clear: it may have been the result of a transcallosal spread from the left SMA or simply an imperfect spatial resolution of the technique. In contrast with Aghakhani (Aghakhani, 2006) in our case no thalamic changes were seen.

Unfortunately, our localizing hypothesis could not be proved by invasive EEG and postsurgical outcome since the patient refused surgical treatment. Nonetheless, this patient suggests that, in the presurgical work up for epilepsy, EEG-fMRI may be considered a useful tool to

generate a localizing hypothesis to be tested with invasive recording also in patients with focal epilepsy and bilateral slow spiked-wave discharges on EEG (secondary bilateral synchrony) and negative MRI. The recording of ictal EEG demonstrates that the slow waves we triggered in our study were irritative and not lesional.

7. Conclusions

The main finding in our EEG-fMRI study of patients with partial epilepsy is that the focal interictal slow-wave activity was invariably associated with increased focal fMRI-BOLD activation responses in a spatially related brain area. Our study extends current knowledge on epileptic foci localization and confirms previous reports suggesting that EEG-fMRI BOLD activation associated with modeled slow activity might have a role in localizing the epileptogenic region, even in the absence of clear interictal spikes (Laufs, 2006; Avesani, 2008/a).

All the patients with partial epilepsy we enrolled in this study had frequent interictal focal slow-wave activity on standard EEG. In all continuous EEG-fMRI recording sessions, after fMRI artifact removal, we obtained good quality EEG that allowed us to detect spontaneous IEDs and analyze the related fMRI BOLD activation. The EEG recording left the quality of the fMRI data almost undistorted, and the focal activity seen in the concurrent EEG was associated, in 15 of 16 patients enrolled, with a focal increase in the MRI signal in all patients. In their focal distribution, these BOLD activations resembled the focal IEDs seen on routine scalp EEG and EEG recorded during EEG-fMRI sessions.

An interesting finding came from the patients with lesional epilepsy. These patients, whose standard MRI documented a lesion and whose standard EEG identified an irritative focus, are ideal candidates for verifying a possible spatial relationship between the epileptogenic and the irritative focus (Ebersole, 1991; Benbadis, 1996).

In the patient who had undergone surgery to remove a cavernoma (P3), the EEG-fMRI study, by localizing the irritative focus and linking it to fMRI as an "active state", showed a significant BOLD activation signal closely related to the poro-encephalic cavity (a residual of previous treatment). Although this focal BOLD activation presumably arose from a blood vessel (residual cavernoma), it was undoubtedly obtained by a protocol study linking an active fMRI state to IEDs on EEG. To clarify the relationship, we decided to progressively test the specificity to a very high level ($p < 0.0001$), as demonstrated in the iconography. Even with these high specificity values, the BOLD activation in that site persisted.

Another new finding is the BOLD activation we detected on fMRI in the patients with MTS. In contrast to others who studied a series of patients with MTS (5 studied with continuous co-registration) (Al Asmi, 2003) and found no significant activation, we detected significant BOLD activation in 4 patients (P1, P4, P9 and P10). These results suggest a possible role of simultaneous EEG-fMRI in disclosing focal activation in the mesial temporal cortex. This cortical area is notoriously difficult to study with standard methods because the deep localization of the irritative area often makes spikes smoother and therefore harder to recognize on recordings

from standard EEG scalp electrodes than in SEEG. Hence, IEDs presenting as slow-wave discharges could be useful in determining significant BOLD activation in a corresponding area, as previously suggested by Laufs et al. (Laufs, 2006).

Useful information that may help us to understand BOLD responses in various forms of epilepsy came also from studying activation in extratemporal IEDs. In the patients with extratemporal discharges (P5, P7, P11, and P12), we noted a good correlation between the clinical polygraphic data and BOLD activation during fMRI. No significant difference was found between activation in the frontal or the occipital lobe. In both regions, BOLD activation increased after focal IEDs. One patient (P11) demonstrated the usefulness of EEG-fMRI, especially when scalp EEG is ambiguous because it is poorly sensitive to detect deep generators on the mesial surface of the frontal lobe, and confirmed that the slow waves were irritative and not lesional.

The reason for such good results (15/16 activations -- significant concordance between EEG and fMRI data) is open to question. The most plausible reason is that during enrolment, to obtain the largest possible percentage of activations, patients were explicitly selected whose standard EEGs showed a high IED firing rate confirmed on EEG during the scanning session. The mean frequency of IEDs in the 15 patients was about 2/min, considerably higher than the 1 IED per minute Duncan considered as the minimum to obtain a focal BOLD activation (Krakow, 1999). Collectively, these findings confirm the importance of IED firing rates in EEG-fMRI.

Perhaps the most interesting finding in this study was that morphology seemed less important than IED firing rates in triggering EEG-fMRI-BOLD activation: 8 of the 16 patients had pure slow waves on standard EEG (4 with high amplitude and 4 with a normal voltage) and 7 had slow spike-wave discharges (4 with high amplitude and 3 with normal voltage); 1 patient (P10) had a focus of normal amplitude, sometimes pure, sometimes with spiked morphology. There were no differences in BOLD activation between the two groups.

Although these slow spike-wave discharges might have originated from a spike focus smoothed by filtering (unlikely because EEG detected the same IEDs before the patients entered the magnet room), there was no difference in the statistical significance of BOLD activation between the two groups. Specifically, slow spike-wave IEDs were no more efficient than slow-wave IEDs in eliciting significant BOLD activation. Hence, it was agreed as previously suggested (Laufs, 2006/a; Avesani, 2008/a) that slow-wave IEDs, like spikes, could elicit a significant increase in cerebral blood flow in a spatially related brain area.

The study also suggests that voltage might have a minor role in determining BOLD activation: in this small study sample there were no differences in BOLD activations between IEDs with high-amplitude (9 patients) and those with normal amplitude slow waves (7 patients).

The significant concordance between EEG and fMRI data, and the absence of multiple activation areas in particular, depended on the high specificity threshold the study design envisaged. In designing this study, only the single activation with the strongest specificity was maintained so that we could verify whether this activation, and this activation alone, coincided with the epileptic focus previously documented by standard EEG and used as a paradigm for the activation-state during the fMRI analysis.

Given the criticism raised against the use of EEG-fMRI instead of other techniques such as EEG-source analysis in the presurgical work-up (Elshoff, 2012), a possible objection to the conclusions we draw could derive from our decision to include only a well-defined sample of patients, all characterized by a focus with a high firing rate, without evidence of the same result in other patients with low firing rate foci (being the most frequent among patients affected by focal drug-resistant epilepsy of surgical interest. We reply that this study was the first approach to investigating interictal slow-wave foci. This will be addressed in a future study in order to validate the technique in patients with slow-wave interictal activity with a low firing rate focus.

At the moment, the complete EEG-fMRI concordance achieved in this study suggests that slow-wave IEDs, even without spikes, may be useful in activating fMRI BOLD responses during the presurgical, noninvasive evaluation of patients with partial drug-resistant seizures.

Acknowledgements

The authors wish to thank:

- Prof. Bernardo Dalla Bernardina, Dp of Life and Reproduction Sciences, University of Verona
- Dr. Giuseppe Moretto and Dr. Tiziano Zanoni, Dp of Neurological Sciences, Civil Hospital of Verona, Dp of Neurological Sciences, Civil Hospital of Verona
- Prof. Nicolò Rizzuto, Dp of Neurological, Neuropsychological, Morphological and Movement Sciences, University of Verona
- Dr. Paolo Manganotti, Dr. Luigi Giuseppe Bongiovanni, Dr. Paolo Borelli, Dr. Alessandra Del Felice, dott. Emanuela Formaggio, dott. Silvia Francesca Storti, Dp of Neurological, Neuropsychological, Morphological and Movement Sciences, University of Verona, Dp of Neurological, Neuropsychological, Morphological and Movement Sciences, University of Verona for their collaboration
- Prof. Roberto Pozzi Mucelli, Dr.ssa Anna Gasparini and Dr. Roberto Cerini, Dp of Radiology University of Verona

Author details

Mirko Avesani¹, Silvia Giacomuzzi² and Antonio Fiaschi¹

¹ University of Verona, Department of Neurological, Neuropsychological, Morphological and Movement Sciences, Italy

² University of Verona, Department of Life and Reproduction Sciences, Italy

References

- [1] Aghakhani et al. fMRI activation during spike wave discharges in idiopathic generalized epilepsy. *Brain*, 2004; 127: 1127-1144
- [2] Aghakhani et al. The role of periventricular nodular heterotopia in epileptogenesis. *Brain*, 2005; 128: 641-651
- [3] Aghakhani et al. Cortical and thalamic fMRI responses in partial epilepsy with focal and bilateral synchronous spikes. *Clin Neurophysiol* 2006;117:177-91.
- [4] Archer et al. fMRI "deactivation" of the posterior cingulate during generalized spike and wave. *Neuroimage*. 2003;20:1915-1922.
- [5] Al-Asmi et al. fMRI activation in continuous and spike-triggered EEG-fMRI studies of epileptic spikes. *Epilepsia*, 2003; 44: 1328-1339.
- [6] Allen et al. Identification of EEG events in the MR scanner: the problem of pulse artifact and a method for its subtraction. *Neuroimage*, 1998; 8: 229-239.
- [7] Allen et al. A method for removing imaging artefact from continuous EEG recorded during functional MRI. *Neuroimage*, 2000; 12:230-239.
- [8] Archer et al. fMRI "deactivation" of the posterior cingulate during generalized spike and wave. *Neuroimage*. 2003;20:1915-1922.
- [9] Archer et al. Spike-triggered fMRI in reading epilepsy: involvement of left frontal cortex working memory areas. *Neurology*, 2003; 60: 415-421
- [10] Avesani et al. Continuous EEG-fMRI in pre surgical evaluation of a patient affected by symptomatic seizures: BOLD activation linked to interictal epileptiform discharges caused by cavernoma. *The Neuroradiology Journal*, 2008/a; 21: 183-191.
- [11] Avesani et al. fMRI in epilepsy with spike and wave activity evoked by eye closure: different BOLD activation in a patient with idiopathic partial epilepsy with occipital spikes and a control group. *Neuroradiol. J.*, 2008/b; 21:159-165.
- [12] Bagshaw et al. EEG-fMRI of focal epileptic spikes: analysis with multiple haemodynamic functions and comparison with gadolinium-enhanced MR angiograms. *Human Brain Mapping*, 2004; 22: 179-192
- [13] Bagshaw et al. Correspondence between EEG-fMRI and EEG dipole localization of interictal discharges in focal epilepsy. *Neuroimage*, 2006; 30: 417-425
- [14] Benar et al. Quality of EEG in simultaneous EEG-fMRI for epilepsy. *Clin Neurophysiol*, 2003; 114: 569-580.
- [15] Benar et al. EEG-fMRI of epileptic spikes. Concordance with EEG source localization and intracranial EEG. *Neuroimage*, 2006; 30: 1161-1170

- [16] Berns. Functional neuroimaging. *Life Sci.* 1999; 65: 2531-2540.
- [17] Bernasconi et al. Proton magnetic resonance spectroscopic imaging suggests progressive neuronal damage in human temporal lobe epilepsy. *Prog. Brain Res*, 2002; 135: 297-304
- [18] Binder et al. Determination of language dominance using functional MRI: a comparison with Wada test. *Neurology*, 1996; 46: 978-984
- [19] Boly et al. Intrinsic brain activity in altered states of consciousness: how conscious is the default mode of brain function? *Ann N Y Acad Sci.* 2008;1129:119–129.
- [20] Boor et al. EEG-related functional MRI in benign childhood epilepsy with centrotemporal spikes. *Epilepsia*, 2003; 44: 688-692
- [21] Borelli et al. EEG-fMRI as an useful tool to detect epileptic foci associated with secondary
- [22] bilateral synchrony. *Seizure*, 2010; 19:605-608.
- [23] Cavanna. The precuneus and consciousness. *CNS Spectr.* 2007;12:545–552.
- [24] Cavanna et al. The precuneus: a review of its functional anatomy and behavioural correlates. *Brain.* 2006;129:564–583.
- [25] David et al. Identifying neural drivers with functional MRI: an electrophysiological validation. *PLoS Biol.* 2008;23:2683–2697.
- [26] Del Felice et al. EEG-fMRI coregistration in non ketotic hyperglycemic occipital seizures. *Epilepsy Research*, 2009;85(2-3):321-324
- [27] De Tiège et al. Impact of interictal epileptic activity on normal brain function in epileptic encephalopathy: an EEG-fMRI study. *Epilepsy Behav.* 2007;11:460–465.
- [28] Devous et al. SPECT brain imaging in epilepsy: a meta-analysis. *J Nucl Med* 1998;39:285–93.
- [29] Devous et al. Single-photon emission computed tomography in neurotherapeutic. *NeuroRx* 2005, 2: 237-249
- [30] Di Bonaventura. EEG/fMRI study of ictal and interictal epileptic activity: methodological issues and future perspectives in clinical practice. *Epilepsia*, 2006; 47, Suppl. 5: 52-58.
- [31] Duncan et al. Imaging and epilepsy. *Brain* 1997; 120: 339-377
- [32] Dupon et al. Bilateral hemispheric alteration of memory processes in right medial temporal lobe epilepsy. *J Neurol Neurosurg Psych*, 2002; 73: 478-485
- [33] Elshoff et al. The value of EEG-fMRI and EEG source analysis in the presurgical setup of children with refractory focal epilepsy. *Epilepsia*, 2012; 53: 1597-1606.

- [34] Engel et al. Comparative localization of epileptic foci in partial epilepsy by PCT and EEG. *Ann Neurol* 1982; 12: 529-537.
- [35] Engel et al. Local cerebral metabolism during partial seizures. *Neurology*, 1983; 33: 400-413
- [36] Faymonville et al. Functional neuroanatomy of the hypnotic state. *J Physiol Paris*. 2006;99:463-469.
- [37] Frackowiak RSJ, Friston KJ, Frith CD, Dolan RJ, Mazziotta JC, editors. San Diego: Academic Press; 1997. *Human brain function*.
- [38] Friston et al. Statistical parametric maps in functional imaging: a general linear approach. *Hum Brain Mapp*, 1995; 2: 173-181.
- [39] Friston et al. Event-related fMRI: characterizing differential responses. *Neuroimage*, 1998; 7: 30-40
- [40] Fransson et al. The precuneus/posterior cingulate cortex plays a pivotal role in the default mode network: Evidence from a partial correlation network analysis. *Neuroimage*. 2008;42:1178-1184.
- [41] Gonçalves,et al. Correlating the alpha rhythm to BOLD using simultaneous EEG-fMRI: inter-subject variability. *Neuroimage*, 2006; 30: 203-213;
- [42] Gotman et al. Combining EEG and fMRI in epilepsy: methodological challenges and clinical results. *I Clin Neurophysiol*, 2004; 21: 229-240
- [43] Gotman et al. Generalized epileptic discharges show thalamocortical activation and the suspension of the default state of the brain. *PNAS*, 2005; 142: 15236-15240
- [44] Gotman et al. Epileptic networks studied with EEG-fMRI. *Epilepsia*, 2008; 49 Suppl 3:42-51.
- [45] Gusnard et al. Medial prefrontal cortex and self-referential mental activity: relation to a default mode of brain function. *Proc Natl Acad Sci USA*. 2001;98:4259-4264.
- [46] Gusnard et al. Searching for a baseline: functional imaging and the resting human brain. *Nat Rev Neurosci*. 2001;2:685-694.
- [47] Hamandi et al. EEG-fMRI of Generalized Spike-Wave Activity. *Neuroimage*. 2006;31:1700-1710.
- [48] Hamandi et al. BOLD and perfusion changes during epileptic generalised spike wave activity. *Neuroimage*. 2008;39:608-618.
- [49] Hammers et al. Abnormalities of grey and white matter [11C] flumazenil binding in temporal lobe epilepsy with normal MRI. *Brain* 2002; 125: 2257-2271
- [50] Henry et al. Positron emission tomography. In: J. Engel, Jr. (Ed.), *Surgical Treatment of Epilepsies*, 2nd edn, Raven Press, New York, 1993; pp. 211-232

- [51] Hill et al. Haemodynamic and metabolic aspects of photosensitive epilepsy revealed by functional magnetic resonance imaging and magnetic resonance spectroscopy. *Epilepsia*. 1999;40:912–920.
- [52] Holmes et al. Are “generalized” seizures truly generalized? Evidence of localized mesial frontal and frontopolar discharges in absence. *Epilepsia*. 2004;45:1568–1579.
- [53] Huggs et al. Normalization of contralateral metabolic function following temporal lobectomy demonstrated by 1H magnetic resonance spectroscopic imaging. *Ann Neurol* 1996; 40: 236-239
- [54] Iannetti et al. fMRI/EEG in paroxysmal activity elicited by elimination of central vision and fixation. *Neurology*, 2002; 58: 976–979.
- [55] Ives et al. Monitoring the patient’s EEG during echo planar MRI. *EEG and Clin Neurophysiol*, 1993; 87: 417-420
- [56] Kobayashi et al. Intrinsic epileptogenicity in polymicrogyric cortex suggested by EEG-fMRI BOLD responses. *Neurology*, 2005; 64: 1263-1266
- [57] Kobayashi et al. Grey matter heterotopia: what EEG-fMRI can tell us about epileptogenicity of neuronal migration disorder. *Brain*, 2006; 129: 366-374
- [58] Kobayashi et al. Widespread and intense BOLD changes during brief focal electrographic seizures. *Neurology*, 2006; 66: 1049-1055
- [59] Kobayashi et al. Negative BOLD responses to epileptic spikes. *Human Brain Mapping*, 2006; 27: 488-497
- [60] Kobayashi et al. Temporal and extratemporal BOLD responses to temporal lobe interictal spikes. *Epilepsia*, 2006; 47: 343-354
- [61] Kokkinos et al. “Epileptogenic networks in two patients with hypothalamic hamartoma.” *Brain Topogr*. 2012;25(3):327-31.
- [62] Krakow et al. EEG-fMRI of interictal epileptiform activity in patients with partial seizures. *Brain*, 1999; 122: 1679-1688
- [63] Krakow et al. Spatio-temporal imaging of focal interictal epileptiform activity using EEG-triggered functional MRI. *Epileptic Disord*, 2001; 3: 67-74
- [64] Kuzniecky et al. Cortical dysplasia in temporal lobe epilepsy: magnetic resonance imaging correlations. *Ann. Neurol*, 1991; 29: 293-298
- [65] Krausz et al. Brain SPECT imaging in temporal lobe epilepsy. *Neuroradiol* 1991; 33: 274-276.
- [66] Labate et al. Typical childhood absence seizures are associated with thalamic activation. *Epileptic Disord*. 2005;7:373–377.

- [67] Laufs et al. EEG-fMRI mapping of asymmetrical delta activity in a patient with refractory epilepsy is concordant with the epileptogenic region determined by intracranial EEG. *Magnetic Resonance Imaging*, 2006/a; 24: 367-371
- [68] Laufs et al. linking generalized spike-and wave discharges and resting state brain activity by using EEG-fMRI in a patient with absence seizures. *Epilepsia*, 2006; 47: 444-448
- [69] Laufs et al. Linking Generalized Spike-and-Wave Discharges and Resting State Brain Activity by Using EEG-fMRI in a Patient with Absence Seizures. *Epilepsia*. 2006;47:444-448.
- [70] Laufs et al. Electroencephalography/functional MRI in human epilepsy: what it currently can and cannot do. *Curr Opin Neurol*. 2007;20:417-423.
- [71] Laureys et al. Brain function in coma, vegetative state, and related disorders. *Lancet Neurol*. 2004;3:537-546.
- [72] Lazeyras et al. Functional MRI with simultaneous EEG recording: feasibility and application to motor and visual activation. *J Magn Reson Imaging*, 2001; 13: 943-948
- [73] Lee et al. Single Photon emission computed tomography (SPECT) brain imaging using N,N,NI-trimethyl-N-(2 hydroxy-3-methyl-5-123-iodobenzyl)-1,3-propanediamine 2 HCl (HIPDM): intractable complex partial seizures. *Neurology* 1986; 36:1471-1477
- [74] Leiderman et al. The dynamic of metabolic change following seizures ad measured by positron emission tomography with fludeoxyglucose F 18. *Arch Neurol*, 1994; 51: 932-936
- [75] Lemieux et al. Event-related fMRI with simultaneous and continuous EEG: description of the method and initial case report. *Neuroimage*, 2001; 1: 780-787
- [76] Liu et al. EEG-fMRI study of the interictal epileptic activity in patients with partial epilepsy. *J Neurol Sci*, 2008; 268: 117-123
- [77] Logothetis et al. Neurophysiological investigation of the basis of the fMRI signal. *Nature*, 2001; 412: 150-157
- [78] Manganotti et al. Continuous EEG-fMRI in patients with partial epilepsy and focal interictal slow-wave discharges on EEG. *Magn Res Imaging*, 2008; 26: 1089-1100.
- [79] Marks et al. Localization of extra-temporal epileptic foci during single photon emission computed tomography. *Ann Neurol* 1992; 31:250-255
- [80] Meeren et al. Cortical focus drives widespread corticothalamic networks during spontaneous absence seizures in rats. *J Neurosci*. 2002;22:1480-1495.
- [81] Meeren et al. Evolving concepts on the pathophysiology of absence seizures: the cortical focus theory. *Arch Neurol*. 2005;62:371-376.

- [82] Menon et al. Imaging function in the working brain with fMRI. *Curr Op Neurobiol*, 2001; 11:630-636.
- [83] Moeller et al. EEG-fMRI: adding to standard evaluations of patients with nonlesional frontal lobe epilepsy. *Neurology* 2009;73:2023–30.
- [84] Newton et al. SPECT in the localisation of extra-temporal and temporal seizure foci. *J Neurol Neurosurg Psychiatry*, 1995; 59: 26-30
- [85] Ogawa et al. Brain Magnetic Resonance Imaging with contrast dependent on blood oxygenation. *Proc Natl Acad Sci*, 1990; 87: 9868-9872
- [86] Petroff et al. GABA and glutamate in the human brain. *Neuroscientist*, 2002; 8: 562-573
- [87] Polack et al. Deep Layer Somatosensory Cortical Neurons Initiate Spike and Wave Discharges in a Genetic Model of Absence Seizures. *J Neurosci*. 2007; 27:6590–6599.
- [88] Prichard et al. Functional study of the brain by NMR. *J Cereb Blood Metab*, 1994; 14: 365-372
- [89] Puce et al. Functional Magnetic Resonance Imaging of sensory and motor cortex: comparison with electrophysiological localisations. *J Neurosurg*, 1995; 83: 262-270
- [90] Ruben et al. Neuroimaging of epilepsy: therapeutic implications. *Neurorx*, 2005; 2: 384-393
- [91] Salek-Haddadi. Functional magnetic resonance imaging of human absence seizures. *Ann Neurol*, 2003; 53: 663-667
- [92] Salek-Haddadi et al. Hemodynamic correlates of epileptiform discharges: an EEG-fMRI study of 63 patients with focal epilepsy. *Brain Research*, 2006; 1088: 148-166
- [93] Salmenpera TM, Duncan JS. Imaging in epilepsy *J. Neurol Neurosurg Psychiatry* 2005;76:2–10.
- [94] So. Mesial frontal epilepsy. *Epilepsia*, 1998; 39(Suppl 4):S49–61.
- [95] Steriade et al. Spike-Wave Complexes and Fast Components of Cortically Generated Seizures. I. Role of Neocortex and Thalamus. *J Neurophysiol*. 1998;80:1439–1455.
- [96] Tai et al. Applications of positron emission tomography (PET) in Neurology. *J. Neurol Neurosurg Psych*, 2004; 75: 669-676.
- [97] Thornton et al. EEG correlated functional MRI and postoperative outcome in focal epilepsy. *J Neurol Neurosurg Psychiatry*, 2010; 81:922-927.
- [98] Tucker et al. Discharges in ventromedial frontal cortex during absence spells. *Epilepsy Behav*. 2007;11:546–557.
- [99] Vaudano. Causal hierarchy within the thalamo-cortical network in spike and wave discharges. *PLoS One*, 2009; 4(8):e6475

[100] Westmoreland. The EEG findings in extratemporal seizures. *Epilepsia*, 1998; 39(Suppl 4):S1-8.

INTECH

INTECH

