

Italian position paper (SIPMO-SICMF) on medication-related osteonecrosis of the jaw (MRONJ)

Alberto Bedogni^{1,2}  | Rodolfo Mauceri^{3,4}  | Vittorio Fusco⁵ | Francesco Bertoldo⁶ | Giordana Bettini^{1,2} | Olga Di Fede³ | Antonio Lo Casto⁷ | Claudio Marchetti⁸ | Vera Panzarella³  | Giorgia Saia² | Paolo Vescovi⁹ | Giuseppina Campisi^{3,4} 

¹Regional Center for Prevention, Diagnosis and Treatment of Medication and Radiation-Related Bone Diseases of the Head and Neck, University of Padua, Padua (PD), Italy

²Department of Neuroscience, University of Padova, Padua (PD), Italy

³Department of Surgical, Oncological and Oral Sciences (Di.Chir.On.S.), University of Palermo, Palermo (PA), Italy

⁴Unit of Oral Medicine and Dentistry for frail patients, Department of Rehabilitation, fragility, and continuity of care, Regional Center for Research and Care of MRONJ, University Hospital Palermo, Palermo (PA), Italy

⁵Oncology Unit, Azienda Ospedaliera di Alessandria SS, Antonio e Biagio e Cesare Arrigo, Alessandria (AL), Italy

⁶Department of Medicine, University of Verona, Verona (VR), Italy

⁷Department of Biomedicine, Neuroscience and Advanced Diagnostic, University of Palermo, Palermo (PA), Italy

⁸Department of Biomedical and Neuromotor Sciences, University of Bologna, Bologna (BO), Italy

⁹Department of Medicine and Surgery, Oral Medicine and Laser Surgery Unit, University Center of Dentistry, University of Parma, Parma (PR), Italy

Correspondence

Giuseppina Campisi, Department of Surgical, Oncological, and Oral Sciences, University of Palermo, Via L. Giuffrè 5, 90127 Palermo (PA), Italy.

Email: giuseppina.campisi@unipa.it, giuseppina.campisi@policlinico.pa.it and campisi@odonto.unipa.it

Abstract

Objective: This paper aims to describe the 2023 update position paper on MRONJ developed by the Italian Societies of Oral Pathology and Medicine (SIPMO) and of Maxillofacial Surgery (SICMF).

Methods: This is the second update following the 2013 and 2020 Italian position papers by the Expert panel, which is a representation of the two scientific societies (SIPMO and SICMF).

The paper is based on an extensive analysis of the available literature from January 2003 to February 2020, and the subsequent review of literature conducted between March 2020 and December 2022 to include all new relevant published papers to confirm or modify the previous set of recommendations.

Results: This position paper highlights the main issues of MRONJ on risk estimates, disease definition, diagnostic pathway, individual risk assessment, and the fundamental role of imaging in the diagnosis, classification, and management of MRONJ.

Conclusion: The Expert Panel confirmed the MRONJ definition, the diagnostic work-up, the clinical-radiological staging system and the prophylactic drug holiday, as recognized by SIPMO-SICMF; while, it presented novel indications regarding the categories at risk of MRONJ, the prevention strategies, and the treatment strategies associated with the therapeutic drug holiday.

KEYWORDS

bisphosphonate, bone density conservation agents, Denosumab, MRONJ, ONJ, osteonecrosis of the jaw

Alberto Bedogni, Vittorio Fusco and Giuseppina Campisi equally contributed to the manuscript.

This is an open access article under the terms of the [Creative Commons Attribution-NonCommercial-NoDerivs](https://creativecommons.org/licenses/by-nc-nd/4.0/) License, which permits use and distribution in any medium, provided the original work is properly cited, the use is non-commercial and no modifications or adaptations are made.

© 2024 The Authors. *Oral Diseases* published by Wiley Periodicals LLC.

Funding information

Agenzia Italiana del Farmaco, Ministero della Salute

1 | INTRODUCTION

Osteonecrosis of the jaw (ONJ) was initially reported only in association with bisphosphonate (BP) treatment (Marx, 2003). Clinical reports rapidly increased after the initial description of ONJ in metastatic bone cancer and multiple myeloma patients receiving BPs to include osteoporosis patients treated with oral BPs, inspiring the use of the term “Bisphosphonate related osteonecrosis of the Jaws” (BRONJ).

More recently patients receiving denosumab (DMB) and several biological agents (including but not limited to agents with antiangiogenic property) showed ONJ development (Otto et al., 2018). Starting from 2014, ONJ related to different medications has been grouped under the term Medication-Related ONJ (MRONJ) (Ruggiero et al., 2014).

The initial difficulties of clinicians who were involved in the diagnosis and treatment of a largely unknown disease are now being compensated by the growing body of knowledge on diagnosis, prevention and management (Bedogni, Fusco, et al., 2012; Colella et al., 2009; Fedele et al., 2010; Junquera & Gallego, 2008; Patel et al., 2012; Schiodt et al., 2014; Yarom et al., 2010).

Here, the authors present the 2023 position paper on MRONJ of the Italian Society of Oral Pathology & Medicine (SIPMO) and the Italian Society of Maxillo-Facial Surgery (SICMF).

The purpose of this position paper is to provide new insights on the following aspects of MRONJ: epidemiology, disease definition, diagnostic pathway (including the role of imaging), staging, risk assessment, preventive strategies and treatment algorithms. Also, this position paper has the aim to offer concise information for healthcare professionals who prescribe medications that increase the individual risk of MRONJ, and for oral healthcare providers.

2 | METHODOLOGY

The SIPMO-SICMF Expert Panel was established in 2010 under the auspices of the SIPMO and the SICMF to appraise the available literature and draft the Italian Recommendations on the diagnosis, prevention, and treatment of ONJ associated with BPs, which were released in Italian language in 2013 (Bedogni et al., 2013) and formally adopted by the Italian Ministry of Health the following year (Ministero Della Salute, 2014). The board panel comprised of a multidisciplinary group of clinicians and researchers with a special interest on ONJ. The Italian Recommendations were further revised to include all the relevant information on the new drugs associated with ONJ and the new categories of patients at increased risk and released in Italy in 2020 (Campisi, Bedogni, & Fusco, 2020). The 2020 update of the Italian Recommendations was endorsed by the following Scientific Societies: Italian Association of Medical Oncology

(AIOM), Italian Society for Osteoporosis, Mineral Metabolism and Bone Diseases (SIOMMMS), Italian Society of Medical and Interventional Radiology (SIRM), Italian Board of Medical Oncology Hospital Directors (CIPOMO), Board of University Professors of Oral Disciplines (CDUO), Italian Society of Osteoncology (ISO). The Recommendations were also endorsed by the National Dental Council Register of Italy and the Interuniversity National Consortium for Bio-Oncology.

This 2023 updated version of the Italian Recommendations was approved by all panellists and purposely written for publication in the English literature, to ensure broad dissemination.

For more details on the research methodology, refer to Supplements (Appendix S1).

2.1 | Definition

The up-to-date SIPMO-SICMF Expert Panel definition of Medication-Related Osteonecrosis of the Jaw (MRONJ), refers to MRONJ as “an adverse drug reaction described as the progressive destruction and death of bone that affects the mandible and maxilla of patients exposed to the treatment with medications known to increase the risk of disease, in the absence of a previous radiation treatment”.

The initial attempt to define osteonecrosis of the jaws following exposure to BPs (BRONJ) was prompted by the American Association of Oral and Maxillofacial Surgery (AAOMS) in 2007 and 2009. The case definition of BRONJ was based on the presence of “exposed, necrotic bone in the maxillofacial region without resolution in 8–12 weeks in persons treated with a bisphosphonate who have not received radiation therapy to the jaws” (Advisory Task Force on Bisphosphonate-Related Osteonecrosis of the Jaws, 2007; Ruggiero et al., 2009).

American Association of Oral and Maxillofacial Surgery case definition of BRONJ was visibly incomplete and raised some criticisms as it was mainly based on the clinical evidence of exposed necrotic bone, leaving patients with signs of osteonecrosis other than bone exposure undiagnosed (i.e. non-exposed ONJ variant) (Bedogni, Fusco, et al., 2012; Colella et al., 2009; Fedele et al., 2010; Junquera & Gallego, 2008; Patel et al., 2012; Schiodt et al., 2014; Yarom et al., 2010).

AAOMS case definition was finally updated in 2014 to include “*probing bone fistula*” in the clinical presentation of the disease. The acronym also changed to MRONJ to embrace new antiresorptive medications and antiangiogenic drugs that have been linked to the development of ONJ. The AAOMS definition has not been changed since then (Ruggiero et al., 2014, 2022).

The SIPMO-SICMF Expert Panel initially recognized the limitations of the 2007 and 2009 AAOMS BRONJ definition and since



2012 proposed a comprehensive definition of BRONJ that was further updated in 2018 to include ONJ-related medications other than BPs (Bedogni et al., 2018; Bedogni, Fusco, et al., 2012).

Patients may be considered to have MRONJ if all the following characteristics are present: (Bedogni, Fusco, et al., 2012; Campisi, Mauceri, et al., 2020)

1. Current or previous treatment with bone-modifying agents (BMAs) and/or antiangiogenic agents (AAs).
2. Clinical and radiological findings of progressive bone destruction.
3. No history of radiation therapy to the jaws or the presence of primary oral malignancy or metastatic disease to the jaws.

Differential diagnosis should also disclose the presence of primary oral malignancy or metastatic disease (Arduino et al., 2015; Bedogni et al., 2007). Osteoradionecrosis should be suspected in patients with a history of radiation therapy to the jaws (Zadik et al., 2021).

The SIPMO-SICMF Expert Panel is concerned that the AAOMS case definition of MRONJ, which is mainly based on non-specific clinical aspects of the disease, may prove unreliable and suggests that MRONJ diagnosis should be reached through a differential diagnosis against different disorders with different aetiologies, presenting with similar clinical and radiological manifestations.

This position has been recently confirmed by the European Task Force on MRONJ, as patients may present with medical and oral conditions not to be confused with MRONJ (Schiodt et al., 2019).

2.2 | Epidemiology

Risk estimates of MRONJ are largely incomplete, biased and difficult to compare. Measures like incidence, prevalence, occurrence and frequency are often misinterpreted and generated data of limited value due to the inconsistency of available studies, short-term observation and the lack of cumulative long-term incidence.

Use of the 2007 AAOMS definition of MRONJ and to a minor extent that of 2014 to adjudicate confirmed MRONJ cases in large clinical trials on BMAs from the last 15 years could have contributed to underestimate the risk of developing osteonecrosis and keep the epidemiologic estimates low (Fedele et al., 2015; Fusco et al., 2011; Fusco, Mauceri, et al., 2022; Otto, Marx, et al., 2015; Schiodt et al., 2014).

Medication-Related Osteonecrosis of the Jaw risk profiles have gradually changed in the last two decades since the introduction of new associated medications to the market and the approval of supplementary indications for drugs already in use. Consequently, new categories of patients are being recognized at increased MRONJ risk.

At present, the SIPMO-SICMF Expert Panel recognizes four main categories of patients at increased MRONJ risk that are listed below:

1. *Cancer patients with Bone Metastases or Multiple Myeloma (BM/MM)*, commonly receiving monthly high doses of BMAs

(HD-BMAs) in combination or not with other drugs (e.g. chemotherapy, endocrine hormonal therapy, immunotherapy, AAs and other biological agents), or, rarely, receiving AAs alone. These patients present with several comorbid conditions, and show heterogeneous but relatively limited expected survival, although improved in recent years due to innovative therapies in some patient subpopulations (Fusco, Campisi, & Bedogni, 2022; Srivastava et al., 2021);

2. *Patients with osteoporosis (OP) and other non-malignant diseases* receiving low doses of BMAs (LD-BMAs). These patients are often elderly and with several comorbid conditions, but are likely to have longer expected survival than BM/MM patients (Kawahara et al., 2021);
3. *Cancer patients without bone metastases* receiving LD-BMAs to reduce the risk of non-metastatic bone fractures due to Cancer Treatment-Induced Bone Loss (CTIBL) in breast and prostate cancer patients, and/or to improve prognosis ("adjuvant" treatment of breast cancer patients) (Diana et al., 2021; Eisen et al., 2022);
4. *Patients with Giant Cell Tumour of Bone (GCTB)*; there are few but interesting data about GCTB patients treated for years with a monthly injection of DMB (HD-DMB), who display an increased risk of MRONJ (Palmerini et al., 2017).

In addition, several case reports and case series described in recent years the development of MRONJ in patients receiving AAs (anticancer drugs with antiangiogenic properties, including bevacizumab, aflibercept, inhibitors of tyrosine kinase and mammalian target of rapamycin inhibitors) or other biological drugs (agents for cancer or autoimmune diseases), with no history of BMA treatment. Yet, data are still inconsistent to quantify the risk of MRONJ for patients receiving only AAs (e.g. metastatic cancer patients receiving AAs alone without HD-BMAs; patients with rheumatic disorders receiving biological agents without LD-BMAs, etc.) (Fusco et al., 2016; King et al., 2019; Nicolatou-Galitis, Kouri, et al., 2019; Ruggiero et al., 2022; Suryani et al., 2022).

For more details, see Supplement, Appendix S2.

The SIPMO-SICMF Expert Panel agrees that BM/MM patients taking HD-BMAs are exposed to the highest risk of MRONJ, with incidence/prevalence ranging between 1% and >20%. Recent systematic and narrative reviews show a higher risk of MRONJ after zoledronic acid in comparison with other BPs (e.g. pamidronate, ibandronate) and a higher risk for DMB in comparison with zoledronic acid. MRONJ risk is thought to increase with time. In the case of BM/MM patients, Kaplan-Meier risk estimation curves show that MRONJ risk increases with the years of treatment (Fusco, Campisi, & Bedogni, 2022; Hata et al., 2022; Ikesue, Doi, et al., 2021; Ikesue, Mouri, et al., 2021; Loyson et al., 2018; Nakai et al., 2021; Rossi et al., 2021; Ueda et al., 2021). Whether the length of BMA treatment (i.e. duration and frequency of drug exposure) prevails over the observation time (i.e. patient survival) it is not fully understood. In any case, long treatment duration and prolonged survival rates raised the cumulative incidence up to 30% at 8-year observation in some metastatic cancer patient subgroups (Hata et al., 2022).

Clinical signs and symptoms

Abscess	Mucosal inflammation
Bone exposure	Non-healing post-extraction socket
Cutaneous fistula	Numbness of the lips ^a
Fluid discharge from the nose	Purulent discharge
Halitosis	Soft-tissue swelling
Intraoral fistula	Spontaneous loss of bone fragments
Jaw pain of bone origin	Sudden dental/implant mobility
Mandible fracture (fragment mobility)	Toothache
Mandibular deformation	Trismus

^aCaused by irritation of the inferior alveolar nerve and/or infraorbital nerve.

On the contrary, the risk of MRONJ in OP patients receiving LD-BMAs is generally below 1%, with the exception of some subgroups at higher risk (e.g. patients with autoimmune or rheumatologic diseases). Real-life observation of the majority of MRONJ cases in OP patients after some years of LD-BMA treatment reflects the long-term results of the FREEDOM Extension study (<1%) (Watts et al., 2019).

The possible role of romosozumab in inducing MRONJ in OP patients is uncertain, as MRONJ was observed mostly in patients that also received bisphosphonates or DMB (see Supplement, Appendix S2).

Medication-Related Osteonecrosis of the Jaw incidence ranges between 0% and 5% in breast and prostate cancer patients treated with BMAs in the "CTIBL prevention" and "adjuvant" settings, but data are scarce and somewhat questionable (see Supplement, Appendix S2) (Brufsky et al., 2013; Coleman et al., 2013; Gnant et al., 2019; Smith et al., 2012).

Medication-Related Osteonecrosis of the Jaw incidence varies among GCBT patients receiving DMB, ranging between 1% and 13% (Jiang et al., 2022; Raimondi et al., 2020).

Additional studies are needed to confirm the risk estimates of MRONJ among CTIBL and GCBT patients.

Most relevant MRONJ quantitative estimates of patients at risk of MRONJ are detailed in Supplement (see Appendix S2).

The SIPMO-SICMF Expert Panel recognizes the existence of new populations of patients at risk of developing MRONJ, since the range of indications for the use of BMAs continues to expand and new agents are introduced in therapeutic armamentarium.

2.3 | MRONJ diagnosis

As previously mentioned, MRONJ has no unique definition, and controversies exist concerning the diagnostic process to be adopted (e.g. exposed vs. non-exposed variant, the role of imaging).

Ideally, both the definition and the diagnostic process of a given disease are intimately linked. Thus, a rigorous disease definition (i.e. case definition) can only lead to a definitive diagnosis when it is composed of signs and symptoms that are disease-specific (e.g. pattern recognition model). This is not the case with MRONJ or, which is known to present with several

TABLE 1 Clinical signs and symptoms suspected for MRONJ (modified from Campisi, Bedogni et al., 2020).

non-specific clinical signs and symptoms, although some are more frequent than others (i.e. bone exposure and probing bone fistulas), as for other oral diseases like Sjogren's syndrome (Al Hamad et al., 2019).

When a case definition is unlikely to be exhaustive, which is the case of AAOMS MRONJ definition, a less restrictive definition should be adopted and a logical diagnostic workflow designed including clinical and instrumental examinations to identify all potential features of the disease and thus reducing the risk of misdiagnosis (e.g. hypothetical-deductive or analytical model) (Cawson et al., 2013; Rugarli, 2017).

Accordingly, the SIPMO-SICMF Expert Panel developed a diagnostic work-up of MRONJ that is based on the clinical and imaging features of the disease (Bedogni, Fusco, et al., 2012). The SIPMO-SICMF workflow is detailed in the next section.

2.3.1 | Clinical features of MRONJ

MRONJ is a multifaceted disease of the bone that can present with different clinical signs and symptoms (Table 1).

Despite the exposure of necrotic bone being the most common clinical feature of MRONJ, there are several other clinical signs and symptoms associated with MRONJ, including but not limited to probing bone fistula through the mucosa (Campisi, Bedogni, & Fusco, 2020; Ruggiero et al., 2014).

Among symptoms, the most frequently reported is pain, although it is absent at MRONJ onset in many patients (Bagan, Jimenez, et al., 2017; Ruggiero et al., 2022; Şahin et al., 2019; Schiodt et al., 2019). Numbness of the lips (e.g. paraesthesia of the lower lip, numb chin syndrome or Vincent's symptom) is also frequently reported by patients, but it is usually associated with advanced MRONJ (Miksad et al., 2011; Otto et al., 2009; Voss et al., 2018).

A peculiarity of MRONJ is that clinical signs and symptoms are not disease-specific, as they can be found in many other conditions, which makes the adoption of a purely clinical MRONJ case definition impractical in routine clinical care (Devlin et al., 2018).

Patients at risk for MRONJ can present with other common clinical conditions, including but not limited to plaque-related gingivitis/periodontitis, dental and periapical disease, benign fibro-osseous lesion of the jawbones, alveolar osteitis, chronic sclerosing



osteomyelitis and infectious osteomyelitis (Schiodt et al., 2019). Overall, these conditions need to be excluded to make a MRONJ diagnosis. Likewise, a differential diagnosis should also disclose primary oral malignancy and metastatic disease to the jaw (Arduino et al., 2015; Gander et al., 2014; Tocaciu et al., 2017).

Since MRONJ is a disease that mostly affects the jawbone architecture, imaging has long been considered a necessary part of the diagnostic process by the SIPMO-SICMF Expert Panel (Bedogni, Fusco, et al., 2012).

2.3.2 | Imaging features of MRONJ

Similar to clinical MRONJ features, radiological signs are not specific and cannot be used alone to diagnose MRONJ (Kim et al., 2020).

TABLE 2 Radiological signs suspected for MRONJ (modified from Campisi, Bedogni et al, 2020).

Radiological signs of MRONJ	Plain radiographs	CT-based radiological investigations
Cortical erosion	X	✓
Diffuse bone marrow sclerosis ^a	✓	✓
Focal bone marrow sclerosis ^a	X	✓
Opacified maxillary sinus	✓	✓
Osteolytic changes	X	✓
Osteolysis extending to the maxillary sinus	X	✓
Osteosclerosis of adjacent bones (zygoma and hard palate)	X	✓
Pathologic fracture	✓	✓
Periodontal space widening	✓	✓
Periosteal reaction	✓	✓
Persistent post-extraction socket	✓	✓
Sequester formation	✓	✓
Sinus tract ^b	X	✓
Thickening of the alveolar ridge	✓	✓
Thickening of the lamina dura	✓	✓
Thickening of the inferior alveolar nerve canal	✓	✓
Trabecular thickening	X	✓

Note: ✓, detectable. X, undetectable or detectable only in advanced MRONJ cases.

^aSclerosis: trabecular bone disorganization and poor corticomedullary differentiation.

^bOroantral, oronasal or orocutaneous communication due to bone destruction.

Several imaging features have been commonly associated with MRONJ, including but not limited to focal or diffuse bone marrow sclerosis, osteolytic changes, periodontal space widening, thickening of the inferior alveolar nerve canal, and sequester formation (Table 2).

Less clear is how to distinguish between early and late MRONJ signs. In fact, the ability to detect early bone changes in MRONJ is largely influenced by the imaging modality used (Wongratwanich et al., 2021).

No consensus has yet been reached regarding the imaging technique of choice to diagnose and screen MRONJ. Nevertheless, plain radiographs and computed tomography (CT) imaging have been adopted in many centres for their ability to image the underlying bone condition and display the radiological features of MRONJ in almost every patient (Baba et al., 2018; Bianchi et al., 2007; Bisdas et al., 2008; Hutchinson et al., 2010). Their wide availability, routine use among dental practitioners for the differential diagnosis of common dental conditions, ease of interpretation, limited contraindication and cost further support the use of plain radiograph and CT (Leite et al., 2014).

Dental x-rays and panoramic radiographs are the radiographic standard of care in routine dental practice and can help the dental practitioner to evaluate and definitively diagnose many oral diseases and conditions, with minimal radiation exposure (Leite et al., 2014; Malina-Altzinger et al., 2019; Ogura et al., 2021). Panoramic radiograph offers a fundamental understanding of the lesions and reveals bone changes suggestive of MRONJ (Cardoso et al., 2017; Moreno-Rabié et al., 2022), but it is much less accurate than 3D imaging (i.e. CT), especially in early disease onset (Guggenberger et al., 2014; Guo et al., 2016).

Magnetic Resonance Imaging (MRI) and other investigations, including bone scintigraphy or Single Photon Emission Computed Tomography (SPECT-CT), may be useful adjuncts in selected complex cases (Bisdas et al., 2008; García-Ferrer et al., 2008; Huber et al., 2020; Watanabe et al., 2019).

The SIPMO-SICMF Expert Panel considers dental x-rays and panoramic radiographs useful first-line screening tools to differentiate among dental conditions that could mimic MRONJ in patients receiving BMAs and/or AAs. Nevertheless, the inclusion of second-line CT-based imaging modalities, such as Cone-Beam (CBCT) and multidetector computed tomography (MDCT), is essential to disclose early signs of MRONJ, anticipate diagnosis and correctly define stage and treatment options.

2.3.3 | Bone biopsy

Although the histology of bone can easily disclose necrotic bone from viable bone also in MRONJ patients, a bone biopsy is generally considered an unnecessary procedure (Campisi, Mauceri, et al., 2020). Location of the proper site for bone biopsy can be challenging in non-exposed MRONJ variants and it would require mucosal incisions to expose the underlying bone, amplifying the risk of bone exposure.

The use of bone biopsy in the diagnostic work-up of MRONJ may only be indicated to disclose the suspect of malignancy (Arduino

et al., 2015; Bedogni et al., 2007; Carlson et al., 2013; Mauceri et al., 2021; Terenzi et al., 2018; Tocaciu et al., 2017).

The SIPMO-SICMF Expert Panel favours a non-invasive diagnostic approach, in which bone biopsy should be provided only in the presence of suspected primary oral malignancy or metastatic bone disease in patients receiving medications at increased MRONJ risk.

2.3.4 | MRONJ case adjudication pathway

Overall, the SIPMO-SICMF Expert Panel recommends the combined use of clinical and radiologic signs to diagnose MRONJ, which likely increases the chance of a correct diagnosis by excluding common oral conditions that could be confused with MRONJ.

In this view, a “suspected MRONJ case” is defined by the presence of at least one clinical sign/symptom in a patient receiving BMAs and/or AAs. Instead, a “confirmed MRONJ case” is defined by the concomitant presence of at least one clinical sign/symptom suggestive of MRONJ and radiological signs of jawbone involvement in a patient receiving BMAs and/or AAs (see Table 2).

2.4 | Diagnostic workup

The SIPMO-SICMF Expert Panel endorses the adoption of a three-step diagnostic work-up of MRONJ as follows (Figure 1):

- **Step 1. Identification of a MRONJ suspected case.** Clinical suspicion should be raised whenever a patient receiving medications associated with MRONJ presents with signs and symptoms in the oral cavity like those described in MRONJ. Analysis of the patient's medical and dental history informs the existence of systemic and local risk factors that could be linked to the disease.
- **Step 2. Differential diagnosis of a MRONJ suspected case.** Oral examination can disclose several oral conditions, but supplemental radiological investigations are required to make the correct diagnosis. 2D imaging modalities (dental x-ray and panoramic radiograph) are useful tools to exclude the main dental and jaw bone conditions presenting clinical and radiological signs and/or symptoms overlapping with the initial phases of MRONJ.
- **Step 3. MRONJ case confirmation.** Every suspected MRONJ case that goes beyond the second step should be considered highly indicative of MRONJ. Second-line CT-based imaging (MDCT/CBCT) not only helps to confirm the diagnosis but it is also essential to accurately stage MRONJ and assign treatments accordingly.

Once the diagnosis of MRONJ is confirmed, reporting each case to the National Pharmacovigilance databases is recommended.

2.5 | Staging

Ideally, a sound staging system measures disease severity and identifies clusters of patients who require similar treatment and have similar

expected outcomes. Objective measures of disease severity and extension should be used to assess disease progression (Markson et al., 1991).

On purpose, the SIPMO-SICMF Expert Panel developed a three-stage clinical-radiological classification system of MRONJ centred on the presence of bone marrow sclerosis at CT-based imaging (Table 3) in adjunct to the patient's clinical findings (Bedogni, Fusco, et al., 2012).

Bone marrow sclerosis is the most frequent radiological sign of MRONJ, and it is also detected in the early phases of the disease (Kim et al., 2020). The SIPMO-SICMF staging system recognizes the presence of a focal disease stage (Stage 1), when bone marrow sclerosis is limited to the alveolar jawbone (Figure 2); a diffuse disease stage (Stage 2), when bone marrow sclerosis encompasses the basal bone (Figure 3); and a complicated stage (Stage 3), which comprises of diffuse bone marrow sclerosis along with clinical and radiological signs of advanced disease (Figure 4).

The presence of pain and purulent discharge does not translate into a worsened disease stage as they can manifest repeatedly through the course of the disease. For this reason, the SIPMO-SICMF staging system includes (a) asymptomatic and (b) symptomatic forms within the same disease stage. This prevents the so-called “ping-pong phenomenon”, which describes the cyclic transition (stage downgrading/upgrading) of MRONJ patients from one stage to another as a result of the antibiotics given to treat recurrent infection with associated pain (Bedogni, Fusco, et al., 2012).

Historically, AAOMS introduced in 2007 a classification system of BRONJ based exclusively on the clinical presentation of the disease (presence of exposed necrotic bone, pain, infection and clinical signs suggestive of complicated disease) to assign patients to different stages of disease severity (Stages 1–3) and treat it accordingly. While in current widespread use, the AAOMS staging system raised several criticisms since its initial publication, as many cases of MRONJ without exposed bone were being excluded from the diagnosis and treatment (Advisory Task Force on Bisphosphonate-Related Osteonecrosis of the Jaws, 2007).

Despite two consecutive updates in 2009 (introduction of “Stage 0”) and 2014 (inclusion of patients with probing bone fistula in the running definition and classification system), AAOMS staging of MRONJ remained basically centred on the clinical presentation of the disease (Ruggiero et al., 2009, 2014).

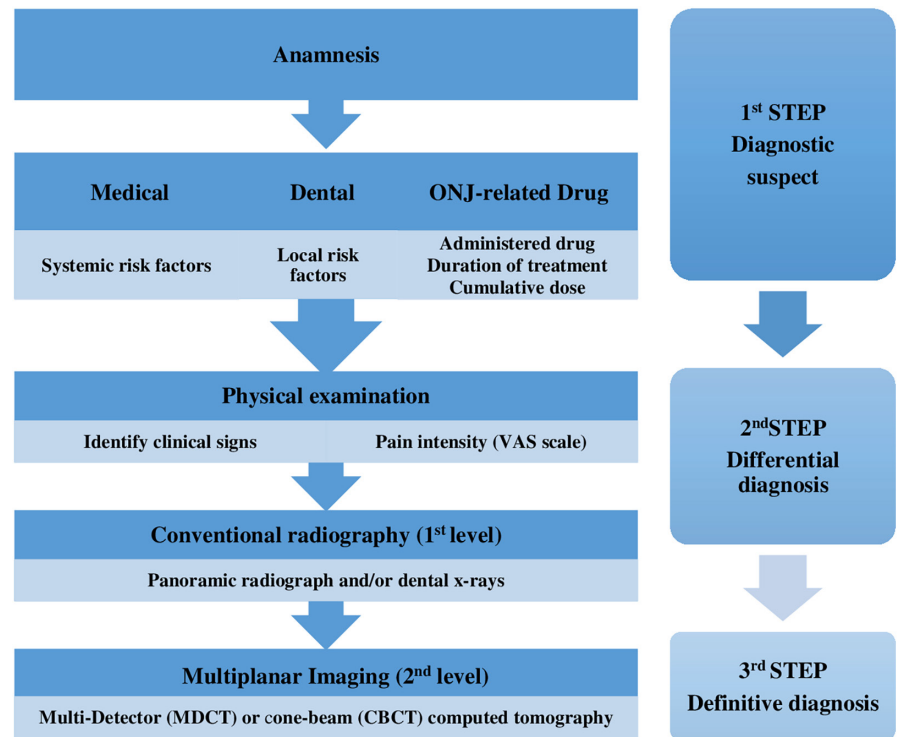
The SIPMO-SICMF Expert Panel early recognized that the most significant weaknesses of the AAOMS staging system were the omission of radiological criteria to diagnose and classify the disease, and the underestimation of the real extent of bone involvement with the use of clinical signs and symptoms only (Bedogni, Fusco, et al., 2012).

Despite many authors having recommended the urgent need to include imaging criteria in the diagnosis and staging of MRONJ (Baba et al., 2018; Bedogni et al., 2014; Patel et al., 2012; Schioldt et al., 2014, 2019), the AAOMS Expert Panel maintained the current classification system with no apparent modifications in the latest 2022 update, where they formally rejected the idea of including radiological features, as these latter “may overestimate the true disease frequency by including false positives in the numerator” (Ruggiero et al., 2022).

The SIPMO-SICMF staging system has two major strengths when compared with the AAOMS classification: (i) it enables clustering of



FIGURE 1 Diagnostic Work-up of MRONJ (modified from Campisi, Bedogni et al, 2020).



patients with similar disease extent in the same stage and proper delivery of stage-related therapies with increasing intensity (Bettini et al., 2021); (ii) it considers clinical signs of recurrent bone infection and associated pain independent variables that cannot trigger any stage transition, as they do not correlate with the extent of bone involvement (Guo et al., 2016).

The SIPMO-SICMF staging system of MRONJ has remained unchanged since its introduction in 2012 and it has been increasingly used in Italy for the last 10 years (Albanese et al., 2020; Antonelli et al., 2021; Bacci et al., 2021; Bettini et al., 2021; Di Fede et al., 2016; Franchi et al., 2021; Marcianò, Ieni, et al., 2021; Marcianò, Ingrassiotta, et al., 2021; Mauceri et al., 2018; Migliario et al., 2017; Pignatelli et al., 2021).

The SIPMO-SICMF Expert Panel encourages the adoption of the proposed staging system on a large scale to assess MRONJ extent and to deliver stage-related treatments.

2.6 | Risk factors of MRONJ

Medication-Related Osteonecrosis of the Jaw is a multifactorial disease for which aetiology is not fully understood. While knowledge of risk factors associated with MRONJ continues to expand, the evolution of cancer therapies is likely to generate new patient populations at increased MRONJ risk. Several medical and dental comorbidities have been associated with an increased risk of MRONJ, while studies on more recent medications are still limited (King et al., 2019; McGowan et al., 2018; Nicolatou-Galitis, Kouri, et al., 2019; Suryani et al., 2022; Wick et al., 2022).

Medication-Related Osteonecrosis of the Jaw risk factors can be divided into three main groups: medication-related, systemic and local (Table 4) (Campisi et al., 2014; Ruggiero et al., 2014).

2.6.1 | Medication-related risk factors

There are two main classes of medications linked to MRONJ development:

1. Bone-modifying agents (BMAs): bisphosphonates (BPs) and denosumab (DMB);
2. Antiangiogenic agents (AAs): anti-VEGF (e.g. bevacizumab), TKIs (e.g. sunitinib) and mTORs (e.g. everolimus).

Other agents have been sporadically associated with MRONJ development but they still await confirmation from clinical studies (see Supplements, Appendix S2) (King et al., 2019; Suryani et al., 2022).

The following aspects are relevant to assess the medication-related risk: *agent type and dosing schedule, duration of treatment and cumulative dose*.

Bone-modifying agents therapy reduces osteoclastic activity, with a consequent decrease in bone resorption and inhibition of bone turnover. BMAs proved effective in preventing skeletal-related events in metastatic cancer patients and the risk of fragility fractures due to osteoporosis (Coleman et al., 2020; LeBoff et al., 2022).

Bisphosphonates (BPs), and nitrogen-containing BPs (NBPs) in particular, have a high affinity for bone and persist at the skeletal level for a long period of time (Fung et al., 2017).

MRONJ clinical-radiological staging system

Stage 1	<p>FOCAL MRONJ: The presence of at least 1 clinical sign/symptom and increased bone density limited to the alveolar process at CT, w/ or w/o additional radiological signs.</p> <p>Clinical signs and symptoms: Abscess, bone exposure, halitosis, intraoral fistula, jaw pain of bone origin, mucosal inflammation, non-healing post-extraction socket, soft-tissue swelling, spontaneous loss of bone fragments, sudden dental/implant mobility, purulent discharge, toothache and trismus.</p> <p>CT signs: Trabecular thickening and/or focal bone marrow sclerosis, w/ or w/o cortical erosion, osteolytic changes, thickening of the alveolar ridge, thickening of the lamina dura, persistent post-extraction socket, periodontal space widening, thickening of the inferior alveolar nerve canal, sequester formation.</p> <p>Stage 1a: Asymptomatic (without pain) Stage 1b: Symptomatic (the presence of pain and/or purulent discharge)</p>
Stage 2	<p>DIFFUSE MRONJ: <i>The presence of at least 1 clinical sign/symptom and increased bone density extending to the basal bone at CT, w/ or w/o additional radiological signs.</i></p> <p>Clinical signs and symptoms: same as Stage 1, plus mandibular deformation and numbness of the lips.</p> <p>CT signs: diffuse bone marrow sclerosis, w/ or w/o cortical erosion, osteolytic changes, thickening of the alveolar ridge, thickening of the lamina dura, persistent post-extraction socket, periodontal space widening, thickening of the inferior alveolar nerve canal, sequester formation, periosteal reaction and opacified maxillary sinus.</p> <p>Stage 2a: asymptomatic (without pain) Stage 2b: symptomatic (presence of pain and/or purulent discharge)</p>
Stage 3	<p>COMPLICATED MRONJ: <i>The presence of at least 1 clinical sign/symptom and increased bone density extended to the basal bone at CT, plus one or more of the following:</i></p> <p>Clinical signs and symptoms: cutaneous fistula, mandible fracture, fluid discharge from the nose.</p> <p>CT signs: osteosclerosis of adjacent bones (zygoma and hard palate), pathologic fracture, osteolysis extending to the maxillary sinus, sinus tract (oroantral, oronasal fistula, orocutaneous).</p> <p>Stage 3a: asymptomatic (without pain) Stage 3b: symptomatic (presence of pain and/or purulent discharge)</p>

TABLE 3 Clinical and radiological MRONJ staging system (modified from Campisi, Bedogni et al, 2020).

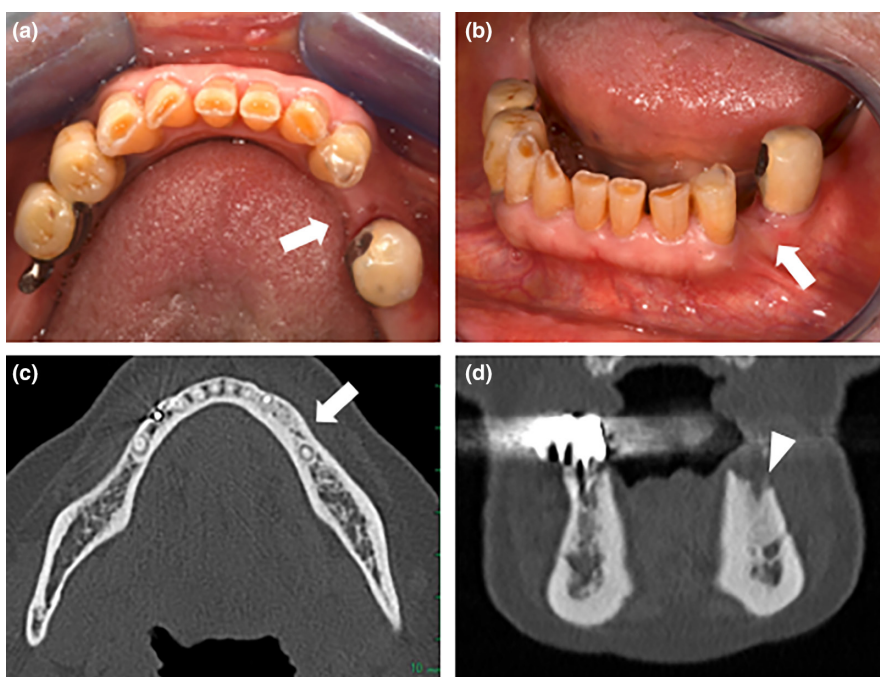


FIGURE 2 Stage 1, Focal MRONJ. Panel a: clinical view showing non-exposed MRONJ in the left posterior mandible (white arrow). Panel b: anterior view of the same lesion displays probing bone mucosal fistula (white arrow). Panel c and d: axial and coronal CT reconstructions show bone marrow sclerosis that is limited to the alveolar jawbone (white arrow and white arrow-head respectively).

FIGURE 3 Stage 2 (Diffuse MRONJ): Panel a: clinical view showing hyperaemic and swollen gingiva of the alveolar socket filled with granulation tissue (white arrow). Panel b: close-up view of the lesion (white arrow-head). Panel c and d: axial and coronal CT reconstructions show bone marrow sclerosis that reaches the basal bone; bone sequestration and periosteal reaction (white arrow and white arrow-head respectively).

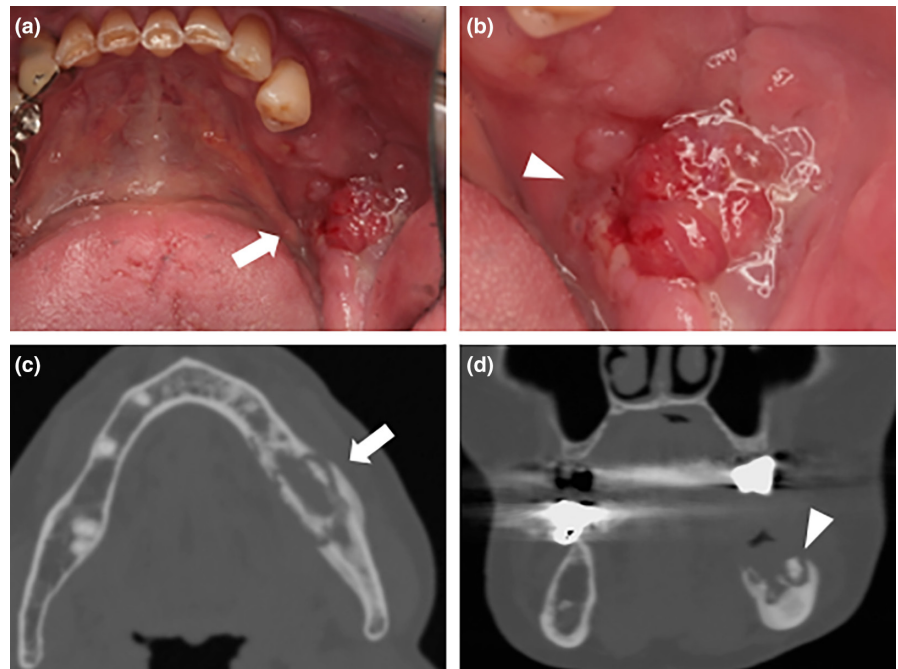
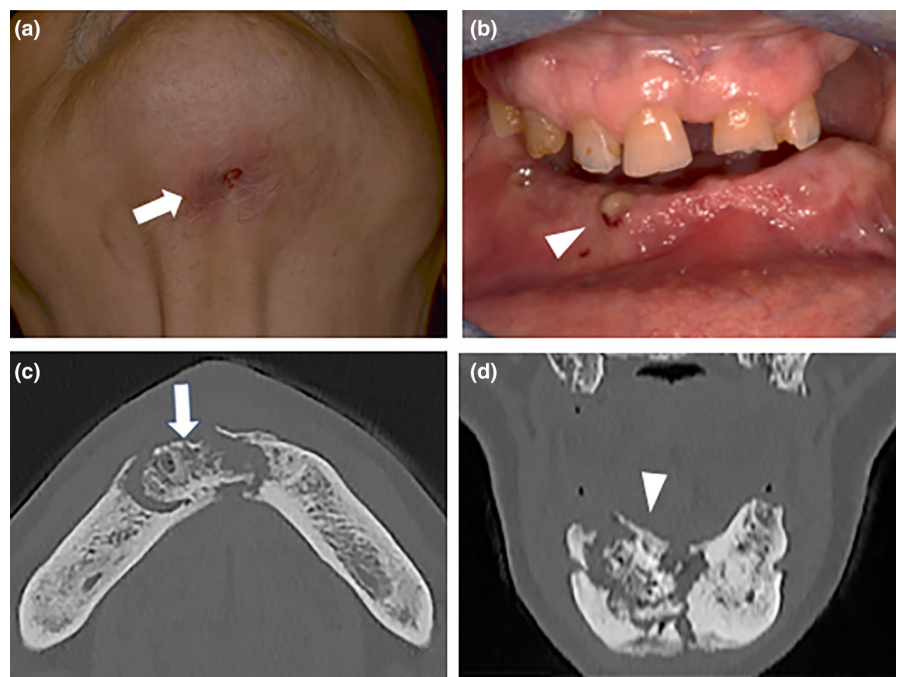


FIGURE 4 Stage 3, Complicated MRONJ. Panel a: clinical view showing a submental cutaneous fistula (white arrow). Panel b: intra-oral view showing single mucosal sinus track with purulent discharge at the level of the inferior gingiva (white arrow). Panel c and d: CT axial and coronal reconstructions display diffuse bone sclerosis encompassing the basal bone, sequester formation and pathologic mandibular fracture (white arrow and white arrow-head respectively).



In contrast, DMB does not accumulate in the bone and suppresses bone turnover through the inhibition of the receptor activator of the nuclear factor- κ B ligand complex (Fung et al., 2017; Mücke, Krestan, et al., 2016). DMB has a mean half-life of approximately 30 days and its effect on bone resorption gradually declines within 6 months after the last dose (Campisi et al., 2021; de Oliveira et al., 2016; Narayanan, 2013; O'Halloran et al., 2014; Otto et al., 2013).

AAs act against pro-angiogenic factors, with a modification of the mechanisms regulating bone repair and a reduction in bone remodelling (Saran et al., 2014). MRONJ development is rare in

patients treated with AAs while the risk of MRONJ likely increases when these drugs are coupled with BMAs (Srivastava et al., 2021). Also, AAs possess a short half-life (e.g. 20 days for bevacizumab, 40–60 hours for sunitinib) as compared with BMAs, and they seem to be characterized by a lower accumulative effect in the bone (Fusco et al., 2016; Maj et al., 2016).

The dosage and schedule of BMAs are major risk factors, with the oncological dosing of intravenous BPs (e.g. zoledronate 4 mg/month) and subcutaneous DMB (120 mg/month) being responsible for the highest risk of MRONJ as compared with low-dose oral/parenteral BPs and subcutaneous DMB (60 mg/6 month) given to

Drug-related	Agent type	<ul style="list-style-type: none"> • Bisphosphonates (BPs) • Denosumab (DMB) • Antiangiogenic drugs (AA)
	Dosage and schedule	
	Duration of treatment	
	Cumulative dose	
	Concomitant therapies	<ul style="list-style-type: none"> • Chemotherapy and anticancer hormone therapy • Corticosteroids • Immunotherapy • Medications inducing osteoporosis • Thalidomide
Systemic	Underlying disease	<ul style="list-style-type: none"> • Malignant disease • Osteoporosis
	Comorbidities	<ul style="list-style-type: none"> • Chronic kidney disease • Diabetes mellitus • Hypocalcaemia/ Hyperparathyroidism and Osteomalacia/Vitamin D deficiency • Lifestyle habits (e.g. smoking) • Rheumatoid arthritis • Others
Local	Dental, periodontal, periapical and peri-implant infection	
	Dental implant surgery	
	Dentoalveolar surgery	
	Ill-fitting dentures (removable prostheses)	
	Anatomical variations	<ul style="list-style-type: none"> • Palatal and mandibular tori • Pronounced mylohyoid ridge
	Tooth extraction	

TABLE 4 Risk factors of MRONJ reported in the literature.

OP and non-metastatic cancer patients (Di Fede et al., 2016; Kuo et al., 2021; Liao et al., 2019; Watanabe, 2020).

The *duration of treatment* is also a relevant aspect to be considered. Most clinical studies on BM/MM patients receiving I.V.BPs report a median time to MRONJ development of 1.5–2 years, despite the great variability of the published data, and some cases of MRONJ occurred after many years of continuous treatment (Hata et al., 2022). In contrast, most cases of MRONJ in OP on BPs oral therapy usually occur after 2–3 years of treatment, with an average of 4.6 years (Fung et al., 2017).

While several studies report a similar time-to-onset of MRONJ for BM/MM patients receiving high-dose BPs and DMB, recent findings suggest that DMB-associated ONJ occurs earlier than BRONJ in cancer patients (Ikesue, Doi, et al., 2021; Loyson et al., 2018). In addition, the switch from BPs (i.e. zoledronic acid) to DMB significantly increases the risk of MRONJ development in BM/MM patients (see Supplement, Appendix S2) (Ikesue, Doi, et al., 2021; Loyson et al., 2018).

In BM/MM patients treated with monthly doses of BPs, the *cumulative dose* reflects the dosage and dosing intervals, the duration of treatment, and the affinity of any given agent for the target tissue. As the cumulative dose of BPs increases (above all with monthly administrations of zoledronic acid), the cumulative

incidence of MRONJ occurrence rises (Hata et al., 2022; Jadu et al., 2007).

At present, long-term estimates of MRONJ are scanty in BM/MM patients receiving monthly DMB injections (Fusco, Rossi, et al., 2022; Hata et al., 2022). Similarly, little data exist on the effect of cumulative dose of BMAs on the risk of MRONJ development in OP patients (Park et al., 2021).

Concomitant medical treatments, chemotherapy, anticancer hormone therapy and corticosteroids in particular, are reported as potential additional risk factors for MRONJ (Schiodt et al., 2018).

Since the introduction of a yearly I.V. infusion of Zoledronic acid and a six-monthly subcutaneous injection of DMB to prevent fragility fractures in OP patients, it has become clearer that the route of administration of BMAs plays a minor role in promoting MRONJ onset as compared with the other medication-related risk factors described. In fact, the frequency of MRONJ among OP patients remains much lower than for patients receiving high-dose BMAs (Everts-Graber et al., 2022; Fusco, Mauceri, et al., 2022).

Overall, the SIPMO-SICMF expert panel hypothesizes that the route of administration of BMAs may not to represent a major risk factor for MRONJ development, in the absence of strong scientific evidence.

Other known drug-related risk factors are described in Table 4.



2.6.2 | Systemic risk factors

Several malignant and systemic diseases have been closely associated with an increased MRONJ risk. BM/MM patients have the greatest susceptibility to MRONJ. Multiple myeloma and metastatic breast and prostate cancer are responsible for the large majority of MRONJ cases reported, followed by metastatic renal cell cancer. Many other cancer types were reported to be at increased risk of MRONJ development, which merits close attention in future clinical studies (King et al., 2019; McGowan et al., 2019). Also, GCTB has been recently associated with an increased risk of MRONJ (Jiang et al., 2022; Palmerini et al., 2017; Raimondi et al., 2020).

Osteoporosis is the most commonly reported non-malignant systemic disease associated with MRONJ onset; other conditions are rheumatoid arthritis, Sjogren syndrome and other autoimmune diseases (Di Fede et al., 2016; Fujieda et al., 2020; Kuo et al., 2021; Liao et al., 2019; Watanabe, 2020).

Systemic conditions for which BMAs and AAs are indicated can be a risk factor per se, although frequently associated comorbidities (e.g. diabetes mellitus, hypertension, etc) could contribute to the individual risk. This is particularly true for the elderly population and for cancer patients (King et al., 2019; McGowan et al., 2019).

Hypocalcaemia and hyperparathyroidism, osteomalacia and vitamin D deficiency have been linked to MRONJ development in the past years (Ardine et al., 2006; Bedogni, Saia, et al., 2012; Heim et al., 2017; Hokugo et al., 2010), but recent data oppose this hypothesis (Bedogni et al., 2019).

Other systemic risk factors have been reported to increase the risk of MRONJ, most of which still await validation (see Table 4).

The SIPMO-SICMF expert panel recommends clinicians record all medication-related and systemic risk factors of patients at increased MRONJ risk at first consultation, and keep their records updated for the entire period of surveillance.

2.6.3 | Local risk factors

Dental, periodontal and jaw bone conditions, which directly or indirectly compromise optimal oral health, increase the risk of MRONJ in a patient receiving BMAs and/or AAs (Table 4).

Tooth extraction has been traditionally considered the major local risk factor of MRONJ. The link between dental extraction and MRONJ development was referred to as the surgical trauma caused to the alveolar bone with a reduced bone turnover (Beth-Tasdogan et al., 2022; Gaudin et al., 2015; Khan et al., 2015; King et al., 2019; Kyrgidis et al., 2008; McGowan et al., 2019; Otto et al., 2012; Otto, Tröltzsch, et al., 2015; Schiodt et al., 2019).

Worthy of note, dental infections (apical/periodontal) are a common cause of dental extraction and have been reported to be associated per se with an increased risk of MRONJ development (Guarnieri et al., 2021; Lorenzo-Pouso et al., 2020; Tomasi et al., 2008).

Several experimental and clinical studies have shown the presence of early clinical, radiological and histological signs

suggestive of MRONJ in the alveolar socket of compromised teeth before or at the time the extraction takes place, suggesting that dental, periapical and periodontal infection may play an even more relevant role than the surgically induced bone trauma (Aghaloo et al., 2011; de França, 2017; Hadaya et al., 2019; Hasegawa et al., 2017; Jeong et al., 2017; Nicolatou-Galitis et al., 2015, 2020; Otto et al., 2021; Saia et al., 2010; Schiodt et al., 2019; Song et al., 2016).

Chronic dental, periapical and periodontal infections are generally associated with inflammatory responses that can alter osteoclast numbers and function through several pathways (e.g. direct stimulation of bone resorption, and stimulation of the release of inflammatory mediators). Overall, sites with increased bone turnover, such as extraction sites or areas of periodontal and periapical inflammation, are exposed to higher BMA intake which could explain the susceptibility of such areas to MRONJ onset (Aghaloo et al., 2011; Allen et al., 2011; Koerdt et al., 2014; Nicolatou-Galitis et al., 2015, 2020; Otto et al., 2021). Moreover, the presence of inflammatory cells in the alveolar bone seems to affect the physiological process of wound healing after the extraction of teeth with periapical or not treated periodontal diseases, in the presence of BMAs (Gkouveris et al., 2019; Landesberg et al., 2008; Soundia et al., 2018).

Similarly, it has been suggested that infection around dental implants may represent a notable risk factor for MRONJ development (Escobedo et al., 2020; Giovannacci et al., 2016; Kwon et al., 2014; Tempesta et al., 2021; Troeltzsch et al., 2016).

Although cases of implant surgery-triggered MRONJ have been reported soon after placement of dental fixtures in patients receiving HD-BMA therapy, the development of infectious-inflammatory processes around dental implants (e.g. peri-implantitis) is more likely to trigger MRONJ in patients who had been implanted well before the start of BMAs (Escobedo et al., 2020). The absence of a barrier effect at the bone-implant interface and the development of occlusal microcracks under masticatory load conditions may partly explain the occurrence of delayed MRONJ around dental implants (Kwon et al., 2014). That said, also OP patients receiving low-dose BPs are potentially exposed to the risk of delayed MRONJ development around dental implants after some years of therapy, but incidence/frequency is seemingly very low (Giovannacci et al., 2016; Kwon et al., 2014; Nisi et al., 2020).

Pressure sores from ill-fitting prostheses represent another established local risk factor for MRONJ.

Inadequate dentures that compress oral mucosa against bony prominences cause mucosal injury with subsequent bone exposure (Hasegawa et al., 2012; Levin et al., 2007).

Several cases of "spontaneous MRONJ" have been frequently described in the past to distinguish them from surgically triggered MRONJ (Khominsky & Lim, 2018; Vescovi et al., 2011). With the growing body of knowledge that most of those cases were triggered by dental and periodontal infections, reports of spontaneous MRONJ cases have become marginal. At present, a "spontaneous case" defines a patient

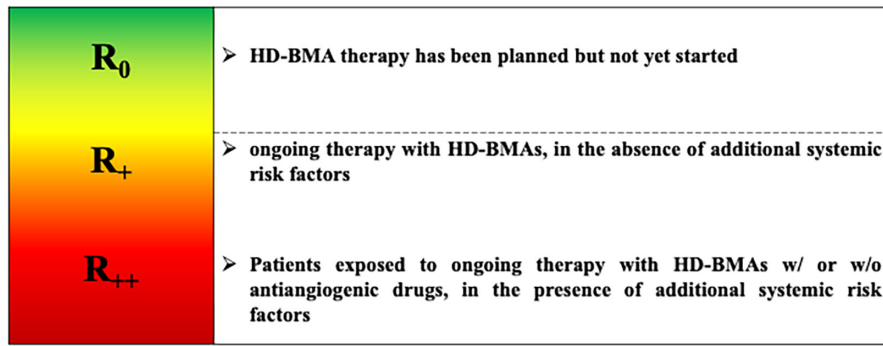


FIGURE 5 MRONJ risk gradient in patients receiving High-Dose (HD) BMAs (modified from Campisi, Bedogni et al, 2020). N.B. Local triggers are not used to define the risk gradient for each patient's category. Instead, they can precipitate MRONJ development when left unresolved. Patients at increased risk of skeletal-related events (SREs) who are shifted from HD-BPs to HD-DMB treatment represent a separate group where the cumulative dosage of the BP leads to the individual risk of MRONJ occurrence.

receiving medications associated with MRONJ, who presents with signs and symptoms of MRONJ in the absence of local risk factors. Genetic factors may play a role in these patients (Yang et al., 2019).

Other known local risk factors are described in Table 4.

In conclusion, the SIPMO-SICMF Expert Panel reaffirms that dental, periapical, periodontal and peri-implant infections are the main local risk factors for MRONJ, and it is concerned that many MRONJ patients in the past could have been misclassified as post-extraction cases, generating the idea that tooth extraction should be avoided in patients receiving BMA therapy.

Other groups of experts have come to the same (our) conclusion and support the idea that extraction of teeth with unfavourable prognosis has a clear role in MRONJ prevention, when properly and timely executed (Schiodt et al., 2019; Yarom et al., 2019).

2.7 | Individual risk assessment

Beyond the different levels of risk recognized for the outlined categories of patients receiving BMAs and/or AAs (see Section 2.2), individual risk assessment depends on the risk factors to which a single patient is exposed (Table 4).

Despite the lack of any reliable formula that can infer the individual risk of MRONJ occurrence at present, the SIPMO-SICMF Expert Panel believes that it is possible to grade the individual risk of MRONJ from time to time.

Although MRONJ cannot develop without exposure of patients to medications associated with MRONJ onset, medication-related risk factors, above detailed, are decisive to figuring out the individual risk assessment, in combination with systemic risk factors to which a single patient is exposed. Although local risk factors do not directly link to any risk category, they can trigger MRONJ development at any time if left untreated.

For the sake of better understanding, the SIPMO-SICMF Expert Panel agreed to showcase individual MRONJ risk separately for patients receiving HD-BMA and LD-BMA therapy.

2.7.1 | Patients at increased risk of MRONJ receiving high-dose BMAs

The SIPMO-SICMF Expert Panel considers that patients can be subgrouped based on the relative risk of MRONJ (R) (Figure 5) as follows:

1. HD-BMAs R_0 : antiresorptive therapy has been planned but not yet commenced.
2. HD-BMAs R_+ : ongoing antiresorptive therapy, in the absence of additional systemic risk factors. R_+ patients display an increased risk of MRONJ occurrence. MRONJ risk upraises in the presence of unresolved oral triggers.
3. HD-BMAs R_{++} : ongoing antiresorptive therapy, in the presence of additional systemic risk factors. MRONJ risk further upraises in the presence of unresolved oral triggers. These patients, including those also receiving antiangiogenic agents, display the highest MRONJ risk and should be carefully monitored. Based on the available literature, such risk is maintained a long time after drug discontinuation in the case of patients receiving BPs.

Within the limitation of the available evidence, the SIPMO-SICMF Expert Panel favours the inclusion of patients with Giant Cell Tumour of Bone (GCTB) on DMB therapy in the same at-risk category of patients receiving HD-BMAs, in light of the designated dosage and monthly schedule of BMA and the comparable frequency of MRONJ onset observed in these patients so far.

2.7.2 | Patients at increased risk of MRONJ receiving low-dose BMAs

Patients receiving low-dose BMA therapy can be stratified into two subgroups, based on the relative risk of MRONJ (R) (Figure 6):

1. LD-BMAs R_0 : patients who are about to start BMAs and patients who have been on BMA therapy for less than 3 years (current



or previous users), in the absence of additional systemic risk factors. R_0 patients display a MRONJ risk comparable to the general population (Campisi, Mauceri, et al., 2020; Di Fede et al., 2018).

- LD-BMAs R_x : patients who received BMAs for more than 3 years, and patients who received BMAs therapy for less than 3 years in the presence of additional systemic risk factors. R_x patients display an increased MRONJ risk that rises in the presence of unresolved oral triggers. This risk remains very low as compared with patients who are receiving HD-BMAs, although it cannot be quantified.

Worthy of note, non-metastatic breast and prostate cancer patients on hormonal therapy, who are being actively treated with low doses of BMAs for managing CTIBL or preventing cancer recurrence (adjuvant setting), should be included in the LD-BMA group risk stratification, in light of the small dosage and the prolonged dosing intervals (Diana et al., 2021).

2.8 | MRONJ prevention

To date, oral health preventive measures remain the most effective strategy to prevent MRONJ prior to, during and after the initiation of treatment with medications associated with an increased risk of MRONJ (Dimopoulos et al., 2009; Mücke, Deppe, et al., 2016; Owosho et al., 2018; Ripamonti et al., 2009).

The aim of primary prevention of MRONJ is to identify and remove all oral conditions that are known to trigger MRONJ and restore sound oral health. Primary prevention starts prior to and continues throughout the duration of therapy with ONJ-related medications; in the case of patients who receive BP therapy, oral surveillance and appropriate dental care should be prolonged after drug cessation, due to its known long-standing inhibition of jawbone remodelling (Campisi, Mauceri, et al., 2020; Schiodt et al., 2019). Unfortunately, the duration of oral surveillance after BP withdrawal is still unknown.

Additional targets of primary prevention are:

- Patient counselling, through which patients are informed about their individual risk of MRONJ and the indispensable adherence to timetabled oral check-ups. Counselling should also make patients aware of the possible clinical manifestations of MRONJ, thereby facilitating their timely recognition (i.e. early diagnosis) and rapid access to treatment;
- Enhanced communication between medical and oral health care providers to establish a beneficial interdisciplinary approach to at-risk patients (e.g. the timing of dental interventions, need for temporary drug withdrawal and drug restart).

When the goals of primary prevention are not targeted, poor adherence to antiresorptive treatments is likely since these medications are perceived as potentially dangerous by patients. This is particularly true for OP patients, whose poor adherence to osteoporosis treatment is a worldwide recognized concern, with a serious impact on deaths and hospitalization (e.g. repeated fractures) (Camacho et al., 2020; Inderjeeth et al., 2014).

One possible explanation for the poor OP patient's adherence to LD-BMA treatment is their fear of potential long-term side effects, including MRONJ occurrence. Awareness of medication-related risks and—most of all—knowledge of the risk reduction strategies proved effective to minimize the risk of MRONJ and might improve OP patients' adherence to antiresorptive treatment.

2.9 | Prevention strategies

MRONJ risk-reduction strategies have been developed in the past years and include the following dental treatments, which should be applied routinely to maximize the oral health of at-risk patients:

- Non-invasive dental procedures to maintain or restore oral health;
- Invasive surgical procedures, such as dental extraction of non-restorable and compromised teeth, to eliminate potential triggering factors.

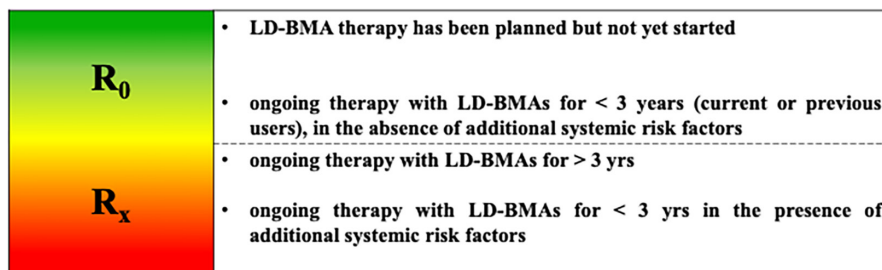


FIGURE 6 MRONJ risk gradient in patients receiving Low-Dose (LD) BMAs (modified from Campisi, Bedogni et al, 2020). N.B. Local triggers are not used to define the risk gradient for each patient's category. Instead, they can precipitate MRONJ development when left unresolved. Patients at increased risk of fragility fractures who are shifted from LD-BPs to LD-DMB treatment represent a separate group where the cumulative dosage of the BP leads to the individual risk of MRONJ occurrence.

Furthermore, it is considered crucial to practice a proper personal oral hygiene in order to reduce gingival inflammation and the possible development of periodontitis.

MRONJ risk-reduction strategies depend on the individual risks of patients, change over time and vary between different patient populations.

a. *Patients scheduled to start treatment with ONJ-related medications (HD-BMAs R_0 and LD-BMAs R_0 categories).*

Pre-treatment evaluation must be performed by an oral health care provider; it should include a comprehensive clinical and radiographic dental examination, the assessment of dental, periodontal and peri-implant status, quality of restorations and the inspection of dentures looking for areas of mucosal trauma. Timely management of potential triggers should be accomplished and initiation of antiresorptive therapy delayed until dental and periodontal health is optimized if systemic conditions permit. In the case of dental, periapical, periodontal or peri-implant infections that require invasive treatment at the bone interface, the patient should be strictly monitored and BMA treatment postponed until soft-tissue healing is achieved (Mauceri et al., 2022).

In the absence of conclusive data, the SIPMO-SICMF Expert Panel agrees with other International Recommendations on the importance of pre-treatment oral evaluation and supports the idea that patients about to start HD-BMA therapy with and without AAs or LD-BMA therapy require a separate approach, based on their distinctive MRONJ risk.

Patients about to start HD-BMAs with or without AAs should always undergo thorough dental and periodontal examination and management of potential infectious foci before initiation of BMAs, due to the growing risk of MRONJ onset. Hypercalcemia of malignancy represents an exception that requires immediate start of BMA treatment. In these patients, initial oral evaluation should be performed as soon as the hypercalcaemic state has been resolved.

Alternatively, a pre-treatment oral evaluation is not mandatory for patients about to start LD-BMA therapy, because they display low to null MRONJ risk as compared with the general population in the first few years of treatment (Campisi, Mauceri, et al., 2020).

The SIPMO-SICMF Expert Panel recommends pre-treatment oral evaluation for patients about to start HD-BMAs. Also, it considers counselling of patients who are scheduled to receive LD-BMAs at least as important as restoring and maintaining their oral health and recommends activating prevention measures within six months from the start of BMA therapy.

b. *Patients on active treatment with ONJ-related medications (HD-BMAs R_+ , R_{++} and LD-BMAs R_x categories).*

Although periodic oral surveillance is accomplished by oral healthcare providers, it is also the responsibility of the treating physicians to contribute to the patient's adherence to the scheduled

recall visits, to minimize the risk of MRONJ occurrence and ensure the patient's persistence on antiresorptive medications.

Recall visits should be scheduled to maintain the oral health of patients for the entire duration of treatment with BMA, with or without AAs, and also periodically later after the end of the treatment. Patients who had received BP treatment should be maintained on strict oral health surveillance for a long time after drug discontinuation. Timely management of potential triggers should be guaranteed to patients (Campisi, Mauceri, et al., 2020; Mauceri et al., 2022).

Furthermore, the prevention measures should be planned also in patients after the end of the treatment with ONJ-related medications and in patients that already suffered from MRONJ.

The SIPMO-SICMF Expert Panel recommends maintaining oral surveillance for the entire duration of DMB treatment and much longer in case of BP therapy, with periodic recall visits on a 4-month basis for HD-BMAs R_+ , R_{++} categories and every 6 months for LD-BMAs R_x category.

2.9.1 | Dental management

Dental treatment includes *essential or emergent procedures* aimed at removing infectious triggers (e.g. pulpitis, pericoronitis, osteitis, dental or periodontal abscess, peri-implantitis, dental trauma, extensive caries or defective restorations that cause pain or tissue damage, adjustments in dentures that cause damage to oral structures) and *non-essential or elective procedures*, which include but are not limited to cosmetic procedures, orthodontic therapy, replacement of amalgam restorations for aesthetic reasons, elective periodontal care, intentional root canal treatment, prosthodontics and elective oral surgery. A major proportion of the dental treatments provided to the general population are elective in nature.

The SIPMO-SICMF Expert Panel classifies dental treatments into the following categories based on a risk/benefit ratio for patients; a traffic light colour code is used for the sake of simplicity (Table 5):

1. *Indicated treatments* (green light): all essential procedures required to treat emergent oral conditions and those elective non-surgical procedures that have not been associated with an increased MRONJ risk;
2. *Feasible treatments* (yellow light): those elective procedures with uncertain MRONJ risk under specific conditions;
3. *Contraindicated treatments* (red light): those elective surgical procedures that are linked to a clearly unfavourable risk/benefit ratio.

In brief, all non-surgical procedures that are essential for the resolution of infectious processes (e.g. restorative dentistry, endodontics and periodontal therapy) are clearly indicated in all patients receiving BMA therapy with or without AAs, independent from their individual MRONJ risk and they should be delivered as soon as possible. The successful restoration/preservation of salvageable teeth is



likely to reduce the need for surgical therapies and the risk of overt MRONJ (Di Fede et al., 2018).

Teeth with poor prognosis or that have failed to resolve with restorative treatment should not be declined dental extraction (Nicolatou-Galitis et al., 2020; Otto, Tröltzsch, et al., 2015; Saia et al., 2010; Schiodt et al., 2019).

Overall, since chronic infection is the main local risk factor for MRONJ, tooth extraction has a clear preventative role of MRONJ, when properly and timely executed (Schiodt et al., 2019).

While HD-BMAs R_0 and LD-BMAs R_0 patients may be safely subjected to routine dental extraction, HD-BMAs R_+/R_{++} and LD-BMAs R_x patients should undergo dental extraction using specific surgical protocols that include mucoperiosteal flap elevation, atraumatic tooth extraction, alveolectomy and smoothing of bone edges and tension-free soft tissue closure (Campisi, Mauceri, et al., 2020; Di Fede et al., 2018; Heufelder et al., 2014; Ristow et al., 2021). Biopsy of the alveolar bone to assess bone viability may be considered in patients at increased MRONJ risk at the time of dental extraction (Nicolatou-Galitis, Schiodt, et al., 2019; Saia et al., 2010). In the case of dental extraction, perioperative administration of systemic antibiotics is often prescribed to lower MRONJ risk in HD-BMAs R_+/R_{++} and LD-BMAs R_x patients. A recent systematic review aimed at assessing the effectiveness of antibiotic therapy in preventing MRONJ in patients receiving BMA and/or AA therapies, when in need of teeth extraction. The authors found that perioperative antibiotic regimens reported in the literature are mainly empirical and lack validation. Peroral penicillin-based antibiotic therapy, either alone or accompanied by a β -lactamase inhibitor or metronidazole was found the most used perioperative protocol (Cabras et al., 2021).

The SIPMO-SICMF Expert Panel recommends the timely extraction of non-restorable teeth and the adoption of specific risk reduction strategies depending on the individual MRONJ risk profile.

Dental implant placement is generally contraindicated in patients scheduled for or already receiving HD-BMA therapy (Campisi, Bedogni, & Fusco, 2020; Japanese Allied Committee On Osteonecrosis Of The Jaw et al., 2017; Yarom et al., 2019).

Alternatively, implant placement is feasible in patients scheduled for or already receiving LD-BMA therapy, irrespective of the agent type and route of administration. Yet, these patients should be informed about the low albeit non-quantifiable risk of MRONJ onset (Escobedo et al., 2020; Giovannacci et al., 2016; Kwon et al., 2014).

Implant-related MRONJ has been recently classified into early (implant surgery-triggered) or late (implant presence-triggered), with the latter occurring most frequently and at sites where implants were placed prior to the initiation of BMAs (Giovannacci et al., 2016; Stavropoulos et al., 2018).

The SIPMO-SICMF Expert Panel recommends avoiding implant placement in patients scheduled for or already receiving HD-BMA therapy, while it considers dental implant surgery a feasible procedure in patients undergoing LD-BMA therapy. In any case, the SIPMO-SICMF Expert Panel recommends evaluating each case individually, performing a complete risk assessment and warning patients scheduled for or already receiving LD-BMA therapy on the potential threat of late MRONJ onset as well as describing all alternative strategies for the restoration of oral functions. Informed consent should be obtained on the possible long-term risks and benefits of the procedure.

2.9.2 | Diagnostic laboratory tests

Literature has provided insufficient data to support the use of biomarkers to predict MRONJ risk in patients on antiresorptive medication who need oral surgical procedures (Dal Prá et al., 2017; Don-Wauchope & Cole, 2009; Peisker et al., 2017; Traboulsi-Garet

TABLE 5 Dental management of patients who receive BMAs and are at increased MRONJ risk (modified from Campisi, Bedogni et al, 2020).

	Dental treatments	HD-BMAs R_+ and R_{++} patients	LD-BMAs R_x patients
Non-surgical procedures	Restorative dentistry	Indicated	Indicated
	Endodontic treatment	Indicated	Indicated
	Orthodontic treatment	Feasible	Feasible
	Periodontal therapy	Indicated	Indicated
	Prosthetic rehabilitation	Feasible	Feasible
Surgical procedures ^a	Dentoalveolar surgery	Indicated	Indicated
	Tooth extraction	Indicated	Indicated
	Pre-implant bone surgery	Contraindicated	Feasible
	Dental implant surgery	Contraindicated	Feasible ^b
	Periodontal surgery	Indicated	Indicated
	Endodontic surgery	Indicated	Indicated

^aTight soft-tissue closure must be ensured. Except for LD-DMB R_x patients who do not necessitate drug suspension before surgery, BMAs should be resumed once wound healing has been achieved (4–6 weeks).

^bIt is advisable to inform the patient about the long-term risk of implant-triggered MRONJ.

Green shade are indicated treatments. Yellow shade are feasible treatments; while in red shade there are contraindicated treatments.

Molecule type	Last dose before surgery	Resume treatment
Medication withdrawal in HD-BMAs R_+ and R_{++} patients		
Bisphosphonates	1 week	Once wound healing has been achieved
Denosumab (Xgeva®)	3 weeks	(4–6 weeks after surgery)
Bevacizumab	5–8 weeks	
Sunitinib	1 week	
Everolimus	1 week	
Medication withdrawal in LD-BMAs R_x patients		
Bisphosphonates	1 week	Once wound healing has been achieved
		(4–6 weeks after surgery)
Denosumab (Prolia®)	No need for suspension ^a	

^aElective surgical treatments including tooth extraction can be preferably performed without restrictions 5 months after the last dose of Prolia®, taking advantage of the reactivated bone turnover and of the recovered healing capacity of bone. This “window of opportunity” lasts about 2 months. A planned 1-month delay of the scheduled dose of DMB may be enough to foster soft-tissue healing, without added risk of fragility fractures. Instead, non-deferrable extraction of compromised teeth should be performed from the 3rd week after the last dose of Prolia® adopting specific risk reduction protocols, which include tight soft-tissue closure.

et al., 2022). Currently, no biomarker with MRONJ specificity and sensitivity exists. Biomarkers should be interpreted in relation to the patients' clinical, radiological and systemic conditions (Moraschini et al., 2019).

The SIPMO-SICMF Expert Panel agrees that the use of biomarkers to predict MRONJ onset could be misleading and does not favour their clinical use until proven otherwise.

2.10 | Prophylactic drug holiday

Planned interruption of BPs, in the absence of MRONJ, before oral surgical procedures (prophylactic drug holiday) including tooth extraction has been emphasized in the past 20 years to prevent impaired wound healing in OP and BM/MM patients at risk of MRONJ.

Length of drug holiday varies in the literature from a few weeks to several months depending on the published protocols (Hasegawa et al., 2019; Khan et al., 2015; Ruggiero et al., 2014).

That said, data on BP drug holidays never proved robust enough in clinical and animal studies to support its routine use as a preventive measure of MRONJ and that drug holiday is not based on data but considering the mechanism of action and kinetics of the drug (Hasegawa et al., 2021; Jung et al., 2019; Kang et al., 2020; Ottesen et al., 2020).

The SIPMO-SICMF Expert panel agrees on the lack of evidence supporting the scientific validity of prophylactic BP discontinuation (prophylactic drug holiday) prior to oral surgical procedures including tooth extraction.

Instead, the SIPMO-SICMF Expert panel considers a targeted (short-term) interruption of BPs mainly in HD-BP R_+ , HD-BP R_{++} and LD-BP R_x patients a reasonable strategy with limited side effects to prevent the possible alveolar bone accumulation of BP following oral surgical procedures, related to bone remodelling process and

minimize toxicity to the oral mucosa (Table 6) (Hadaya et al., 2021; Inoue et al., 2021; Kobayashi et al., 2010; Ravosa et al., 2011).

Short-term interruption of BPs should start one week before surgery and last until soft-tissue healing has been achieved (4–6 weeks) (Campisi, Mauceri, et al., 2020).

In any case, discontinuation of BPs must be authorized by the treating physician/prescriber, who should outweigh the risks associated with discontinuation of therapy.

Differently from BPs, DMB has a short half-life, and its effect on bone resorption gradually declines within six months after the last dose (de Oliveira et al., 2016). The reversible mechanism of DMB on bone mineral density (BMD) supports the theoretical concern about a possible increased risk of fracture upon stopping DMB (Prolia®) in OP patients (i.e. rebound phenomenon), which usually happens 8–16 months from the last denosumab injection (Anastasilakis et al., 2017; McClung et al., 2017). Indeed, while denosumab therapy increases BMD and reduces fracture risk, the disruption of bone architecture caused by osteoporosis is not reversed with treatment. In this view, withdrawal of Prolia® is largely discouraged in OP patients for the increased risk of rebound-associated vertebral fractures (RAVFs), and switching to another osteoporosis therapy is recommended (Tsourdi et al., 2021).

In the context of preventing skeletal-related events (SREs), DMB (Xgeva®) is initiated at diagnosis of bone metastases and continued indefinitely in many cases (Plancharde et al., 2018).

DMB prophylactic drug holiday has been suggested to prevent delayed bone healing and reduce the risk of MRONJ onset in HD-DMB R_+ and HD-DMB R_{++} , but the results are controversial (Hasegawa et al., 2021; Ottesen et al., 2020).

Within the limits of the available knowledge, the SIPMO-SICMF Expert Panel considers DMB prophylactic drug use before oral surgical procedures hazardous and recommends a different approach to be used in patients at increased MRONJ risk, based on the dosing

TABLE 6 Timing of perioperative withdrawal of different ONJ-related medications (modified from Campisi, Bedogni et al., 2020).



schedule of DMB (Xgeva® 120mg Q4W vs. 60mg Prolia® 60mg twice-yearly). In detail, indicated surgical treatments including tooth extraction (Table 5) should be performed in HD-DMB R₊ and HD-DMB R₊₊ patients at least 3 weeks after the last dose of Xgeva®, and the following injection postponed until soft-tissue healing is achieved (4–6 weeks). Specific MRONJ risk reduction protocols must be combined to further reduce the risk of MRONJ onset (see paragraph on dental management).

On the other side, oral surgical procedures including non-urgent tooth extraction (Table 5) can be performed without restrictions in LD-DMB R_x patients 5 months after the last dose of Prolia®, taking advantage of the reactivated bone turnover and of the recovered healing capacity of bone. This “window of opportunity” lasts about 2 months. A targeted 1-month delay of the scheduled dose of Prolia® may be enough to foster soft-tissue healing, without the added risk of RAVFs (Lyu et al., 2020).

Non-deferrable extraction of compromised teeth should be performed at least 3 weeks after the last dose of Prolia®, and specific MRONJ risk reduction protocols combined to further minimize the risk of MRONJ onset (see paragraph on dental management).

Since the approval of AAs for the treatment of a wide range of cancer types, sporadic cases of MRONJ have been reported, especially when they are coupled with BMAs (Srivastava et al., 2021) AAs possess a short half-life as compared with BMAs. These targeted medications not only exert an antiangiogenic effect on tumour cells but also on healthy tissues, thus reducing the ability of soft tissue to repair and complicate postoperative wound healing (Eming & Krieg, 2006).

The SIPMO-SICMF Expert panel agrees that AAs must be discontinued before any surgical operation, including oral and maxillofacial surgery, and the duration of withdrawal depends on their distinct half-life (Campisi, Bedogni, & Fusco, 2020; Nicolatou-Galitis, Kouri, et al., 2019; Scappaticci et al., 2005). The SIPMO-SICMF Expert Panel affirms that in any case, temporary withdrawal of AAs must be authorized by the treating physician/prescriber, who should outweigh the risks associated with discontinuation of the therapy.

The timing of the perioperative withdrawal of different ONJ-related medications based on their distinct half-life is described in Table 6.

2.11 | Treatment

The management of MRONJ is highly debated. Different treatment protocols for MRONJ have been proposed in the literature that are mainly based on case series and retrospective cohorts. To date, there is no robust evidence to support any specific treatment (Beth-Tasdogan et al., 2022; Moraschini et al., 2021). Similarly, temporary withdrawal of BMAs and AAs following MRONJ diagnosis has been suggested in the past years without conclusive validation (Jacobson et al., 2022; Khan et al., 2015; Lee et al., 2013; Tsourdi et al., 2021).

Standard non-surgical (or medical) therapy, which mainly consists of antiseptic mouth rinses, systemic antimicrobial agents, analgesics and smoothing of exposed and sharp bony edges to prevent ulcerated lesions of the oral mucosa, has been recommended as the mainstay of MRONJ treatment for almost 20 years with the aim of eliminating pain and infection and minimizing disease progress (Ruggiero et al., 2022).

2.11.1 | Antibiotic therapy

The fact that infection accompanies, if not determines, the clinical manifestations of MRONJ in most cases supports the use of antibiotics in managing the related signs and symptoms of MRONJ.

Although several clinical studies have reported the use of antibiotics in the management of overt MRONJ, they were always associated with other medical or surgical interventions and administered with different schedules to heterogeneous patient populations, and in the absence of control groups (Hoefert & Eufinger, 2011; Moretti et al., 2011).

Until now, antibiotic therapy is more empirical than based on evidence, regarding the agents to be used, the route of administration, dosages and the treatment duration.

The most used antibiotics for the treatment of MRONJ in patients taking oral BMAs are penicillin, amoxicillin, amoxicillin/clavulanic acid, metronidazole and/or a combination thereof (Bermúdez-Bejarano et al., 2017).

The SIPMO-SICMF Expert Panel, recognizing the importance of systemic antibiotic therapy in the treatment of MRONJ-related infection and pain, has identified an empirical antimicrobial protocol based on the following principles:

1. Combinations of antibiotics including penicillin (active against Gram-negative and Gram-positive β -lactamase-resistant bacteria) and metronidazole (active against anaerobes, particularly *Bacteroides* spp. and Gram-positive cocci), as the first-line treatment;
2. Duration of therapy ranging from a minimum of 7 days to a maximum of 14 days at full dosage;
3. Oral administration route for non-hospitalized patients; preferential I.V. administration for patients hospitalized due to infectious complications or associated surgical procedures;
4. Alternative agents (e.g. erythromycin, clindamycin or ciprofloxacin) to be used in case of allergies to penicillin/cephalosporins or proven inefficacy of standard treatment.

Additional non-invasive treatments have been proposed as an adjunct to non-surgical and surgical therapy, including hyperbaric oxygen therapy, ozone therapy, low-level laser therapy, teriparatide, pentoxifylline (associated or not with tocopherol), autologous platelet-rich blood derivatives and Bone Morphogenetic Proteins, with varying degree of success in selected patient populations (Cavalcante & Tomasetti, 2020; Del Fabbro et al., 2015; Di Fede et al., 2022; Fortunato et al., 2020;

Freiberger et al., 2012; Morishita et al., 2020; Ripamonti et al., 2012; Vescovi et al., 2014).

Yet, these adjunctive treatments require definitive confirmation before being endorsed in routine clinical practice, due to extra costs and restricted availability (Beth-Tasdogan et al., 2022; Di Fede et al., 2021).

A symptomatic treatment approach as described above was based on the assumption that MRONJ is incurable and MRONJ occurs most frequently in metastatic cancer patients with comorbid conditions and limited life expectancy. Consequently, surgical therapy had been considered for a long time palliative rather than curative and offered only to patients with an advanced disease not responding to medical treatment (Advisory Task Force on Bisphosphonate-Related Osteonecrosis of the Jaws, 2007; El-Rabbany et al., 2017; Ferlito et al., 2012; Khan et al., 2015; Ruggiero et al., 2009, 2014; Saussez et al., 2009; Scoletta et al., 2010; Van den Wyngaert et al., 2009; Wutzl et al., 2008).

These statements have been substantially challenged in recent years when it has been cleared out that MRONJ can be cured if properly and timely managed, and that MRONJ patients can greatly benefit from surgery in terms of improved quality of life, restored oral function and access to potentially life-prolonging therapies, including BMAs (Bedogni et al., 2011; Oteri et al., 2017; Ruggiero et al., 2022).

The aim of MRONJ treatment has recently shifted from palliative to curative, thanks to the reliable results of surgery (Bettini et al., 2021; Carlson, 2014; Ruggiero & Kohn, 2015; Schiodt et al., 2019).

In fact, it is now evident that surgical treatment, in combination with medical therapy, offers more predictable results than non-surgical therapy alone in all disease stages and in the long term (Di Fede et al., 2021; Fliefel et al., 2015; Kim et al., 2017).

The SIPMO-SICMF Expert Panel has long been considering surgery the backbone of MRONJ treatment, while being aware that medical therapy still represents a reasonable treatment option for patients unfit for surgery or who refuse it (Bedogni et al., 2013; Campisi et al., 2014; Campisi, Bedogni, & Fusco, 2020; Campisi, Mauceri, et al., 2020). Decision on surgical versus non-surgical treatment remains patient-specific and should always undergo careful clinical judgment.

2.11.2 | Medication withdrawal in confirmed MRONJ cases (therapeutic drug holiday)

The benefits of antiresorptive therapy far outweigh the risk of MRONJ onset. Nevertheless, when MRONJ is diagnosed, BMAs are often discontinued until disease resolution is achieved in many cases (Hayashida et al., 2020; Morishita et al., 2022).

The term “*Therapeutic Drug Holiday*” is used to define the withdrawal of BMAs and AAs soon after the occurrence of MRONJ, with the aim of promoting/accelerating disease resolution. Conceptually, it highly differs from “*prophylactic drug holiday*” that is aimed at

preventing MRONJ in at-risk patients, before oral surgical procedures take place.

It is controversial as to whether therapeutic drug holiday in combination with medical and/or surgical treatments might promote or accelerate MRONJ disease resolution.

Early clinical recommendations and international consensus statements theorized the withholding of BMAs, especially in the oncological setting (Khan et al., 2015; Lee et al., 2013). More recent publications raised concern about the real benefit and potential harm of temporary BMA discontinuation in cancer and OP patients with suspected or established MRONJ and left the final decision only at the discretion of the treating physician, after discussion with the patient and the oral health provider (Coleman et al., 2020; Jacobson et al., 2022; Tsourdi et al., 2021; Yarom et al., 2019).

Based on the different pharmacodynamics and kinetics of BPs as compared with DMB and AAs, the SIPMO-SICMF Expert Panel decided to address separately the likelihood of temporary medication withdrawal in BP-associated ONJ and non-BP-associated ONJ (DMB and AAs).

Despite the lack of robust data on the effectiveness of drug discontinuation, there is general agreement among maxillofacial surgeons and oral health care providers that long-term withdrawal of BPs does not influence the natural course of MRONJ and does not increase the chance of better treatment outcomes (Hayashida et al., 2020; Morishita et al., 2022; Omori et al., 2022; Otsuru et al., 2022).

In light of the long-lasting inhibitory effect of BPs on bone remodelling and in the absence of exhaustive data, the SIPMO-SICMF Expert Panel considers BP withdrawal a potentially harmful strategy for BRONJ patients and does not recommend its routine application, at least in the first years of BP treatment. Alternatively, perioperative discontinuation of BPs (short-term interruption) starting the week before surgery until complete healing is obtained seems a reasonable strategy with limited side effects to reduce their accumulation in the surgical site, although evidence remains weak.

Temporary withdrawal of BPs should be limited to specific cases, decided by the treating physician in agreement with the oral health provider and the pros and cons discussed with the patient.

Since its approval for the prevention of SREs in metastatic cancer patients and the prevention of fragility fractures in OP patients, DMB has been associated with the occurrence of MRONJ at least the same as the most potent BPs (i.e. monthly zoledronic acid and oral BPs in the two population subgroups). As previously mentioned, DMB does not bind to hydroxyapatite and incorporate into bone; thus, bone turnover recovers rapidly after drug discontinuation.

In light of the supposed “rebound effect” phenomenon and the increased risk of RAVFs in OP patients (see paragraph on prophylactic drug holiday), DMB withdrawal is generally contraindicated in LD-DMB patients (Cummings et al., 2018). On the contrary, the reported risk of RAVFs after DMB discontinuation in metastatic cancer patients appears low as compared with OP patients, with only a few reports in the literature (Dupont et al., 2022). It is, therefore,



likely that DMB treatment might be temporarily interrupted in patients with a favourable prognosis who receive HD-DMB, and resumed in case of disease progression (Coleman et al., 2020; Dupont et al., 2022).

Data on DMB withdrawal are scanty but it seems that discontinuation before surgery may accelerate MRONJ resolution (Hayashida et al., 2020; Omori et al., 2022; Otsuru et al., 2022).

Within the limits of the available knowledge, the SIPMO-SICMF Expert Panel considers a 6-month temporary DMB interruption a potentially suitable strategy to reduce the burden of surgical treatment for BP-naïve metastatic cancer patients with MRONJ. On the contrary, DMB withdrawal is not recommended as an adjunctive non-surgical treatment.

Temporary withdrawal of DMB requires accurate clinical judgment and should always be decided on a per-patient basis by the treating physician in agreement with the oral health provider and the pros and cons discussed with the patient. Close clinical and instrumental monitoring of bone turnover is required for the patient's safety and the prompt resumption of BMAs when needed.

In the case of OP and CTIBL patients with MRONJ receiving LD-DMB therapy, the SIPMO-SICMF Expert Panel hypothesizes that a planned 1-month delay of the scheduled dose of DMB may be sufficient to allow surgical operations of reduced intensity to be done 5 months after last DMB injection, while ensuring the benefit of the reactivated bone turnover on the healing capacity of bone, without the added risk of RAVFs.

As previously stated (see paragraph on Prophylactic drug holiday), AAs should be always interrupted before any surgical operation takes place, and the timing of interruption depends on the half-life of the given drug. AA withdrawal should last until complete soft-tissue healing has been achieved (4–6 weeks).

2.11.3 | Surgical treatment

The SIPMO-SICMF Expert Panel recognizes the existence of several points at issue that could negatively influence the result of surgery, including: *a-* the adoption of a single surgical algorithm to treat all MRONJ patients, regardless of their underlying condition (BM/MM vs. OP), the medication received (BPs vs. DMB vs. AAs) and its dosage (high-dose vs. low-dose); *b-* the adoption of a stage-related treatment algorithm based on clinical signs and symptoms only; *c-* the lack of a common strategy to define the surgical bone margins; *d-* the ambiguity of operational definitions proposed for the different surgical interventions; *e-* the absence of standardized outcomes of surgery and the variability of follow-up.

1. There is a growing body of literature that BM/MM patients receiving high-dose BMAs, besides an increased risk of MRONJ, also display earlier disease onset, faster progression/severity and worse prognosis as compared with OP patients receiving low-dose BMAs (Hayashida et al., 2017).

In addition, while BPs have high skeletal retention and are stored in bone for a long time, DMB does not incorporate into the bone, and its inhibitory effect on bone turnover reverses at the end of the dosing interval (McClung et al., 2006). Likewise, the antiangiogenic activity of biological agents is time-dependent, and the blood supply to the bone and surrounding soft tissues goes back to normal a few days/weeks after drug cessation (Fusco et al., 2016; Nicolatou-Galitis, Kouri, et al., 2019).

Overall, these facts make it very likely that *response to surgery* is *not uniform* in MRONJ patients and varies with the patient clinical condition, the medication received, the dosing schedule and intervals. In other words, a given surgical procedure may be excessive for some patient categories (i.e. overtreatment) or deficient for others (i.e. undertreatment).

The SIPMO-SICMF Expert Panel, unlike other groups of experts, endorsed this hypothesis and in 2013 developed a surgical algorithm where the magnitude of surgical therapy was graded among BM/MM patients receiving high-dose BPs and OP patients receiving low-dose BPs (Bedogni et al., 2013; Campisi et al., 2014). Clinical results seem to confirm the need for reduced surgical treatment intensity in MRONJ patients receiving LD-BMAs (Bettini et al., 2021).

2. AAOMS task force was the first to introduce a staging system based on clinical signs and symptoms to address disease severity, cluster patients and assign treatments accordingly (Advisory Task Force on Bisphosphonate-Related Osteonecrosis of the Jaws, 2007; Ruggiero et al., 2009, 2014).

This is still the most largely recognized classification method, despite its failure to depict the real extent of osteonecrosis (Baba et al., 2018; Bedogni et al., 2014; Kim et al., 2020). Therapies that rely on the use of a staging system based on clinical signs and symptoms may prove unsafe now that AAOMS has opened to the surgical treatment of MRONJ for all AAOMS disease stages (Ruggiero et al., 2022).

The SIPMO-SICMF clinical-radiological staging system was developed in 2012 to provide an accurate description of disease extent as the basis for the appropriate delivery of surgical treatments of increasing intensity (Bedogni et al., 2013; Bedogni, Fusco, et al., 2012). The identification of increased bone density (i.e. osteosclerosis) at CT was established as a marker of disease severity to identify increasing levels of bone involvement, ranging from focal to diffuse disease. Surgery is graded so that patients with “focal disease” (Stage 1) are likely to receive less invasive surgical treatment (i.e. bone curettage and sequestrectomy) as compared with more advanced disease stages (Stage 2 and 3), who deserve more radical interventions (i.e. marginal and segmental resection of bone) (Campisi et al., 2014).

The recently proposed AAOMS surgical algorithm parallels the one originally developed by the SIPMO-SICMF Expert Panel,

TABLE 7 MRONJ Treatment.

(a) Stage-related surgical algorithm of BRONJ^a		
SIPMO-SICMF staging system	High-dose BPs	Low-dose BPs
Stage 1 (focal ONJ)	<i>Dentoalveolar surgery: marginal resection</i>	<i>Dentoalveolar surgery: curettage and bone sequestrectomy; marginal resection for recurrent disease</i>
Stage 2 (diffuse ONJ)	<i>Segmental resection + bone reconstruction when indicated</i>	<i>Dentoalveolar surgery: marginal resection; segmental resection for recurrent disease</i>
Stage 3 (complicated ONJ)	<i>Segmental resection + bone reconstruction when indicated</i>	<i>Segmental resection + bone reconstruction when indicated</i>

- 1-month postoperative BP withdrawal starting 1 week before surgery to reduce accumulation at the surgical site that could hamper the healing process.
- Dento-alveolar surgery can be done under loco-regional anaesthesia.
- Achieve stable mucosal coverage of the operated site irrespective of the surgical technique adopted.
- Adjunctive treatment options: use of piezoelectric or laser-assisted surgery to minimize ischemic damage to the bone.
- Perioperative topical disinfection (chlorhexidine 0.2%) for 7–10 days.
- Peroral antibiotic therapy (7–14 days long) for surgery under loco-regional anaesthesia; I.V. perioperative antibiotic therapy (7–14 days long) for hospitalized patients and surgery under general anaesthesia.
- Perioperative pain control
- Postoperative clinical follow-up at 1, 3, 6 and 12 months. CT scans at 6 and 12 months after surgery.

(b) Stage-related surgical algorithm of DMB-ONJ^b		
SIPMO-SICMF staging system	High-dose DMB	Low-dose DMB
Stage 1 (focal ONJ)	<i>Dentoalveolar surgery: curettage and bone sequestrectomy; marginal resection for recurrent disease</i>	<i>Dentoalveolar surgery: curettage and bone sequestrectomy; marginal resection for recurrent disease</i>
Stage 2 (diffuse ONJ)	<i>Dentoalveolar surgery: curettage and bone sequestrectomy; marginal resection for recurrent disease</i>	<i>Dentoalveolar surgery: curettage and bone sequestrectomy; marginal resection for recurrent disease</i>
stage 3 (complicated ONJ)	<i>Dentoalveolar surgery: marginal resection; segmental resection for recurrent disease</i>	<i>Dentoalveolar surgery: marginal resection; segmental resection for recurrent disease</i>

- *In patients receiving Xgeva®, 6-month temporary DMB interruption is required before surgery.*
- *In patients receiving Prolia®, surgery should be performed 5 months after the last dose, with 1-month postoperative delay of the following dose, until complete healing is achieved.*
- Dento-alveolar surgery can be done with loco-regional anaesthesia.
- Achieve stable mucosal coverage of the operated site irrespective of the surgical technique adopted.
- Adjunctive treatment options: use of piezoelectric or laser-assisted surgery to minimize ischemic damage to the bone.
- Perioperative topical disinfection (chlorhexidine 0.2%) for 7–10 days.
- Peroral antibiotic therapy (7–14 days long) for surgery under loco-regional anaesthesia; I.V. perioperative antibiotic therapy (7–14 days long) for hospitalized patients and surgery under general anaesthesia.
- Perioperative pain control.
- Postoperative clinical follow-up at 1, 3, 6 and 12 months. CT scans at 6 and 12 months after surgery.

(c) SIPMO-SICMF Non-surgical treatment protocol of MRONJ	
SIPMO-SICMF staging system	Medical therapy^c
All disease stages	<ul style="list-style-type: none"> • Oral mouth rinses • Systemic broad-spectrum antibiotics (7–14-day long in case of recurrent pain and suppuration; monthly schedule in refractory cases) • Pain control • Adjunctive treatment options: biostimulation with ozone or low-level laser therapy/laser photobiomodulation <p>Aims: symptomatic (palliation); Exfoliation of the exposed, necrotic bone</p>

^aIt also includes MRONJ patients who have been shifted from NBPs to DMB.^bSuitable for BP-naive patients taking DMB.^cSuitable for systemically compromised patients for whom surgical therapy is contraindicated, or in case of patient's refusal of surgery.



except that they do not detail how to measure the extent of bone disease (i.e. focal vs. diffuse bone involvement).

Being concerned that delivery of surgical treatments of increasing magnitude based on clinical signs and symptoms only will pose MRONJ patients at risk of failure/relapses (undertreatment) or harmful side effects (overtreatment), the SIPMO-SICMF Expert Panel recommends the adoption of its clinical-radiological staging system to assign surgical treatment based on the radiological extent of bone involvement.

3. The amount of bone that needs to be removed surgically is paramount to prevent failures and early MRONJ relapses. Demarcation of necrotic and viable bone margins for surgery is challenging. While several authors agree on the use of preoperative imaging to better visualize the extent of bone disease, many clinicians rely on the intraoperative inspection of bone to define the margins for a "safe" resection (Bedogni et al., 2011; Ruggiero et al., 2022). Both approaches have limitations.

Among the different imaging techniques used, CT and MRI give a detailed description of the bone marrow changes and help define the boundaries of viable and necrotic bone, with respect to the uninvolved bone tissue (Bagan, Leopoldo-Rodado, et al., 2017; Huber et al., 2020).

Multidetector CT (MDCT) and cone beam CT (CBCT) can also pick up the early radiological aspects of MRONJ, as compared with plain radiographs (Devlin et al., 2018; Guo et al., 2016).

Although no distinct imaging phenotype exists for MRONJ and advanced imaging modalities might overestimate the extent of disease as compared with the clinical picture, CT and CBCT could be used to accurately diagnose the extent of MRONJ lesions (Kim et al., 2020).

Establishing healthy bone margins intraoperatively remains a major challenge. Surgeons must observe the bone colour and bleeding to distinguish the necrotic from the viable bone. Bone bleeding has been used for a long as a marker of bone health, but it proved unreliable and operator-biased (Ristow et al., 2016).

Fluorescence-guided bone surgery, with and without tetracycline fluorescence labelling, has been successfully used to increase the intraoperative accuracy of bone surgery (Ristow et al., 2016). The fluorescence technique likely improves the demarcation of viable bone, as compared with clinical inspection alone (Giovannacci et al., 2019; Ristow et al., 2016; Ristow & Pautke, 2014). Since the way for surgical management of MRONJ has been recently cleared, the SIPMO-SICMF Expert Panel is concerned that the absence of a common strategy to define the surgical bone margins of MRONJ will negatively

impact the results of future clinical research on this topic and preclude comparison of different surgical treatment strategies.

Because MRONJ is a bony disease, the SIPMO-SICMF Expert Panel recommends the adoption of CT-based imaging techniques to preoperatively assess MRONJ patients elected for surgery, for two main reasons: 1- the same imaging technique can be used to diagnose, stage and define the extent of the disease; and, 2- identification of the margins of bone surgery before the operation takes place enables the effective exchange of information between physicians and patients concerning the proposed treatment and its consequences.

Also, the SIPMO-SICMF Expert Panel supports the use of MR imaging techniques in combination with CT-based imaging to improve definition of the margins of bone resection in selected cases.

4. Surgical procedures generally used to treat MRONJ patients range from superficial bone debridement to more radical interventions including the whole resection of diseased bone, with or without simultaneous reconstruction.

The lack of standardized terminology to label MRONJ surgical procedures of different magnitude and anatomical location has made it difficult to compare treatment results in the past years. Different surgical procedures have been confused under the same term or as opposed the same surgical procedure has been termed differently (Schiodt et al., 2019).

The SIPMO-SICMF Expert Panel endorses the adoption of a standardized set of surgical interventions to establish the risks and benefits of each operation and allow disease stage-related comparisons of different treatments.

5. Additional limitations of the current approach to MRONJ treatment are the lack of standardized outcomes to assess the impact of surgical procedures on patients, and the high variability of postoperative follow-up (Choi et al., 2020).

Although the curative potential of surgery signifies a paradigm shift in MRONJ treatment compared to the past, little has been done to refine the criteria of treatment success adopted so far. In this view, the widely used definition of painless mucosal healing seems insufficient as it only reflects the condition of the covering mucosal surface (Beth-Tasdogan et al., 2022).

The SIPMO-SICMF Expert Panel suggests the adoption of a more comprehensive definition of healing that encompasses the condition of the underlying bone. This can be achieved by coupling the clinical and radiological criteria of healing (Campisi, Mauceri, et al., 2020) so that treatment can be considered successful, and healing completed in the absence of both clinical and radiological signs of MRONJ (Campisi et al., 2014); in addition, any given

treatment could also be considered successful in the presence of stable radiological signs of MRONJ when the clinical signs and symptoms are absent (i.e. remission).

The transition from a higher to a lower disease stage (i.e. stage improvement) following treatment of MRONJ has been considered a positive outcome in many published studies in the past years (Comas-Calonge et al., 2017; Ruggiero & Kohn, 2015; Tenore et al., 2020; Vescovi et al., 2006). A combination of “stage improvement” and “mucosal healing” used to generate composite treatment outcomes has raised the success rate of interventions in several MRONJ cohorts but did not improve the clinical condition of treated patients, unless in early-stage diseases (Giudice et al., 2020).

The SIPMO-SICMF Expert Panel is concerned that the inclusion of “stage improvement” in the clinical outcome of MRONJ treatments does not reflect a real advantage for patients as they might experience further disease relapse.

How long surgically treated patients should be followed up before being considered cured is another debated aspect. Published clinical studies on MRONJ treatment are largely retrospective, display limited follow-up times and do not report a precise follow-up schedule for operated patients (Aljohani et al., 2019; Carlson & Basile, 2009; Okuyama et al., 2021; Stockmann et al., 2010). Based on the data available, we can only imply that MRONJ recurrences usually occur within 6 months after surgery, with a considerable number of relapses happening up to 1 year, independent from the type of treatment, the primary disease and the medication received (Bedogni et al., 2011; Choi et al., 2020). Therefore, the optimistic results of surgical therapy described in previous studies with limited follow-up may have been partly overestimated.

The SIPMO-SICMF Expert Panel considers successful any MRONJ treatment (medical and/or surgical) that displays clinical-radiological signs of healing or remission at the 1-year follow-up and suggests the use of such a composite clinical outcome to assess the efficacy of surgical treatments in future clinical studies.

2.11.4 | SIPMO-SICMF stage-related surgical algorithm

The SIPMO-SICMF stage-related surgical algorithm was originally developed in 2013 to specifically address increasing levels of surgical intensity based on the extent of BRONJ and the primary disease of affected patients (Campisi et al., 2014). This algorithm has been recently upgraded to include a separate treatment protocol for DMB-ONJ (Campisi, Bedogni, & Fusco, 2020). The SIPMO-SICMF stage-related surgical algorithm describes the combination of medical therapies and surgical techniques to be adopted in BRONJ (Table 7a) and DMB-ONJ (Table 7b); it also describes the non-surgical treatment of MRONJ (Table 7c). For a detailed description of the SIPMO-SICMF stage-related surgical algorithm including jawbone reconstructive options refer to supplement (Appendix S3, Table IIIa,b).

3 | CONCLUSION AND FUTURE RESEARCH

This Position paper recognizes the weakness of the available evidence on MRONJ and the difficult task that both researchers and clinicians are facing to develop common strategies for the prevention and treatment of this multifaceted disease. The SIPMO-SICMF Expert Panel urges moving towards a universally accepted and less strict definition of MRONJ, an individualized MRONJ risk assessment and the recognition of the essential role of imaging in the diagnosis, classification and management of overt MRONJ.

The SIPMO-SICMF Expert Panel recognizes that the statements and recommendations here provided warrant further confirmation and updates, and highlights the need for a global and interdisciplinary scientific approach to MRONJ to overcome region-specific challenges.

Additionally, the SIPMO-SICMF Expert Panel underlines the importance of communicating the individual risk of MRONJ to patients and caregivers, to warrant patients' adherence to medical treatment and oral health programmes in the long term; it also encourages healthcare professionals to constantly update the literature to be guided in clinical decision-making since new medications with a potential threat to patients come to market; and finally it promotes the large-scale dissemination of the present document among the healthcare professionals involved.

AUTHOR CONTRIBUTIONS

Rodolfo Mauceri: Investigation; data curation; writing – original draft; writing – review and editing; visualization. **Alberto Bedogni:** Conceptualization; methodology; writing – original draft; writing – review and editing; investigation; data curation; supervision; visualization; project administration; validation. **Vittorio Fusco:** Conceptualization; investigation; writing – original draft; writing – review and editing; methodology; validation; visualization; project administration; data curation; supervision. **Francesco Bertoldo:** Validation. **Giordana Bettini:** Validation. **Olga Di Fede:** Validation. **Antonio Lo Casto:** Validation. **Claudio Marchetti:** Validation. **Vera Panzarella:** Validation. **Giorgia Saia:** Validation. **Paolo Vescovi:** Validation. **Giuseppina Campisi:** Conceptualization; investigation; funding acquisition; writing – original draft; methodology; validation; writing – review and editing; project administration; data curation; supervision; visualization.

ACKNOWLEDGEMENTS

The authors would like to acknowledge Lorenzo Lo Muzio (former president of the Italian society of Oral Pathology and Medicine–SIPMO) and Paolo Ronchi (former president of the Italian Society of Maxillofacial Surgery–SICMF) for establishing the Expert Panel and Michele Davide Mignogna (current president of the SIPMO) and Luigi Califano (current president of the SICMF) for their ongoing unconditional support to the consensus activities.

FUNDING INFORMATION

The development of this position paper has been partly funded by the Active Pharmacovigilance Project Fund (AIFA project



"ADR in Dentistry in the Digital Age: From Reporting to Specialist Consultation with a Click" – "ADR in Odontoiatria nell'era informatica: dalla segnalazione alla visita specialistica con un click", led by Prof. G. Campisi).

CONFLICT OF INTEREST STATEMENT

The authors declare no competing interests. Within the last 12 months, G.C. and A.B. received honoraria for lecturing by Amgen; and F.B. has been consultant or speaker for Abiogen, Amgen, UCB pharma, Chiesi and SPA.

DATA AVAILABILITY STATEMENT

The data that supports the findings of this study are available in the supplementary material of this article.

ORCID

Alberto Bedogni <https://orcid.org/0000-0003-4742-4508>

Rodolfo Mauceri <https://orcid.org/0000-0002-4008-6502>

Vera Panzarella <https://orcid.org/0000-0001-6339-6020>

Giuseppina Campisi <https://orcid.org/0000-0002-9443-0495>

REFERENCES

- Advisory Task Force on Bisphosphonate-Related Osteonecrosis of the Jaws AA of O and MS. (2007). American Association of Oral and Maxillofacial Surgeons position paper on bisphosphonate-related osteonecrosis of the jaws. *Journal of Oral and Maxillofacial Surgery*, 65, 369–376.
- Aghaloo, T. L., Kang, B., Sung, E. C., Shoff, M., Ronconi, M., Gotcher, J. E., Bezouglaia, O., Dry, S. M., & Tetradis, S. (2011). Periodontal disease and bisphosphonates induce osteonecrosis of the jaws in the rat. *Journal of Bone and Mineral Research*, 26, 1871–1882.
- Al Hamad, A., Lodi, G., Porter, S., Fedele, S., & Mercadante, V. (2019). Interventions for dry mouth and hyposalivation in Sjögren's syndrome: A systematic review and meta-analysis. *Oral Diseases*, 25, 1027–1047.
- Albanese, M., Zotti, F., Capocasale, G., Bonetti, S., Lonardi, F., & Nocini, P. F. (2020). Conservative non-surgical management in medication related osteonecrosis of the jaw: A retrospective study. *Clinical and Experimental Dental Research*, 6, 512–518.
- Aljohani, S., Troeltzsch, M., Hafner, S., Kaeppler, G., Mast, G., & Otto, S. (2019). Surgical treatment of medication-related osteonecrosis of the upper jaw: Case series. *Oral Diseases*, 25, 497–507.
- Allen, M. R., Kubek, D. J., Burr, D. B., Ruggiero, S. L., & Chu, T.-M. G. (2011). Compromised osseous healing of dental extraction sites in zoledronic acid-treated dogs. *Osteoporosis International*, 22, 693–702.
- Anastasilakis, A. D., Polyzos, S. A., Makras, P., Aubry-Rozier, B., Kaouri, S., & Lamy, O. (2017). Clinical features of 24 patients with rebound-associated vertebral fractures after Denosumab discontinuation: Systematic review and additional cases. *Journal of Bone and Mineral Research*, 32, 1291–1296.
- Antonelli, A., Bennardo, F., Barone, S., Caruso, D., Cristofaro, M. G., & Giudice, A. (2021). *Clinical and radiological features of medication-related osteonecrosis of the jaws: Comparison of staging systems*. Qeios.
- Ardine, M., Generali, D., Donadio, M., Bonardi, S., Scoletta, M., Vandone, A. M., Mozzati, M., Bertetto, O., Bottini, A., Dogliotti, L., & Berruti, A. (2006). Could the long-term persistence of low serum calcium levels and high serum parathyroid hormone levels during bisphosphonate treatment predispose metastatic breast cancer patients to undergo osteonecrosis of the jaw? *Annals of Oncology*, 17, 1336–1337.
- Arduino, P. G., Scully, C., Chiusa, L., & Broccoletti, R. (2015). Oral squamous cell carcinoma arising in a patient after hematopoietic stem cell transplantation with bisphosphonate-related osteonecrosis of the jaws. *Case Reports in Dentistry*, 2015, 4–6.
- Baba, A., Goto, T. K., Ojiri, H., et al. (2018). CT imaging features of anti-resorptive agent-related osteonecrosis of the jaw/medication-related osteonecrosis of the jaw. *Dento Maxillo Facial Radiology*, 47, 20170323.
- Bacci, C., Boccuto, M., Cerrato, A., Grigoletto, A., Zanette, G., Angelini, A., & Sbricoli, L. (2021). *Safety and efficacy of sectorial resection with piezoelectric device in ONJ*. Qeios.
- Bagan, L., Jimenez, Y., Leopoldo, M., Murillo-Cortes, J., & Bagan, J. (2017). Exposed necrotic bone in 183 patients with bisphosphonate-related osteonecrosis of the jaw: Associated clinical characteristics. *Medicina Oral, Patología Oral y Cirugía Bucal*, 22, e582–e585.
- Bagan, L., Leopoldo-Rodado, M., Poveda-Roda, R., Murillo-Cortes, J., Diaz-Fernández, J. M., & Bagan, J. (2017). Grade of sclerosis in the contralateral mandibular area in osteonecrosis of the jaws. *International Journal of Oral and Maxillofacial Surgery*, 46, 167–172.
- Bedogni, A., Bettini, G., Bedogni, G., Basso, D., Gatti, D., Valisena, S., Brunello, A., Sorio, M., Berno, T., Giannini, S., Navaglia, F., Plebani, M., Nocini, P. F., Blandamura, S., Saia, G., & Bertoldo, F. (2019). Is vitamin D deficiency a risk factor for osteonecrosis of the jaw in patients with cancer? A matched case-control study. *Journal of Cranio-Maxillofacial Surgery*, 47, 1203–1208.
- Bedogni, A., Campisi, G., & Fusco, V. (2018). *Medication related osteonecrosis of the jaw (MRONJ)*. Qeios.
- Bedogni, A., Campisi, G., Fusco, V., & Agrillo, A. (2013). *Raccomandazioni clinico-terapeutiche sull'osteonecrosi delle ossa mascellari associata a bisfosfonati e sua prevenzione*. Cleup Ed. (C Ed., Ed.).
- Bedogni, A., Fedele, S., Bedogni, G., Scoletta, M., Favia, G., Colella, G., Agrillo, A., Bettini, G., di Fede, O., Oteri, G., Fusco, V., Gabriele, M., Ottolenghi, L., Valsecchi, S., Porter, S., Petruzzini, M., Arduino, P., D'Amato, S., Ungari, C., ... Campisi, G. (2014). Staging of osteonecrosis of the jaw requires computed tomography for accurate definition of the extent of bony disease. *The British Journal of Oral & Maxillofacial Surgery*, 52, 603–608.
- Bedogni, A., Fusco, V., Agrillo, A., & Campisi, G. (2012). Learning from experience. Proposal of a refined definition and staging system for bisphosphonate-related osteonecrosis of the jaw (BRONJ). *Oral Diseases*, 18, 621–623.
- Bedogni, A., Saia, G., Bettini, G., Tronchet, A., Totola, A., Bedogni, G., Ferronato, G., Nocini, P. F., & Blandamura, S. (2011). Long-term outcomes of surgical resection of the jaws in cancer patients with bisphosphonate-related osteonecrosis. *Oral Oncology*, 47, 420–424.
- Bedogni, A., Saia, G., Bettini, G., Tronchet, A., Totola, A., Bedogni, G., Tregnago, P., Valenti, M. T., Bertoldo, F., Ferronato, G., Nocini, P. F., Blandamura, S., & Dalle Carbonare, L. (2012). Osteomalacia: The missing link in the pathogenesis of bisphosphonate-related osteonecrosis of the jaws? *The Oncologist*, 17, 1114–1119.
- Bedogni, A., Saia, G., Ragazzo, M., Bettini, G., Capelli, P., D'Alessandro, E., Nocini, P. F., Russo, L. L., Lo Muzio, L., & Blandamura, S. (2007). Bisphosphonate-associated osteonecrosis can hide jaw metastases. *Bone*, 41, 942–945.
- Bermúdez-Bejarano, E.-B. B., Serrera-Figallo, M.-Á. Á., Gutiérrez-Corrales, A., Romero-Ruiz, M. M., Castillo-de-Oyagüe, R., Gutiérrez-Pérez, J. L., & Torres-Lagares, D. (2017). Prophylaxis and antibiotic therapy in management protocols of patients treated with oral and intravenous bisphosphonates. *Journal of Clinical and Experimental Dentistry*, 9, e141–e149.
- Beth-Tasdogan, N. H., Mayer, B., Hussein, H., Zolk, O., & Peter, J. U. (2022). Interventions for managing medication-related osteonecrosis of the jaw. *Cochrane Database of Systematic Reviews*, 10, CD012432.

- Bettini, G., Saia, G., Perra, E. S., Tognin, L., Franco, P., Bedogni, G., & Bedogni, A. (2021). Curative rates of medication-related osteonecrosis of the jaw following application of the SICMF-SIPMO surgical treatment algorithm. *Qeios*.
- Bianchi, S. D., Scoletta, M., Cassione, F. B., Migliaretti, G., & Mozzati, M. (2007). Computerized tomographic findings in bisphosphonate-associated osteonecrosis of the jaw in patients with cancer. *Oral Surgery, Oral Medicine, Oral Pathology, Oral Radiology, and Endodontology*, *104*, 249–258.
- Bisdas, S., Chambron Pinho, N., Smolarz, A., Sader, R., Vogl, T. J., & Mack, M. G. (2008). Bisphosphonate-induced osteonecrosis of the jaws: CT and MRI spectrum of findings in 32 patients. *Clinical Radiology*, *63*, 71–77.
- Brufsky, A. M., Sereika, S. M., Mathew, A., Tomifumi, O., Singh, V., & Rosenzweig, M. (2013). Long-term treatment with intravenous bisphosphonates in metastatic breast cancer: A retrospective study. *The Breast Journal*, *19*, 504–511.
- Cabras, M., Gambino, A., Broccoletti, R., Sciascia, S., & Arduino, P. G. (2021). Lack of evidence in reducing risk of mronj after teeth extractions with systemic antibiotics. *Journal of Oral Science*, *63*, 217–226.
- Camacho, P. M., Petak, S. M., Binkley, N., Diab, D. L., Eldeiry, L. S., Farooki, A., Harris, S. T., Hurley, D. L., Kelly, J., Lewiecki, E. M., Pessah-Pollack, R., McClung, M., Wimalawansa, S. J., & Watts, N. B. (2020). American association of clinical endocrinologists/American college of endocrinology clinical practice guidelines for the diagnosis and treatment of postmenopausal osteoporosis-2020 update. *Endocrine Practice*, *26*, 1–46.
- Campisi, G., Bedogni, A., & Fusco, V. (2020). In N. D. F. Srl (Ed.), *Raccomandazioni clinico-terapeutiche sull'osteonecrosi delle ossa mascellari (ONJ) farmaco-relata e sua prevenzione*. Palermo University Press.
- Campisi, G., Fedele, S., Fusco, V., Pizzo, G., Di Fede, O., & Bedogni, A. (2014). Epidemiology, clinical manifestations, risk reduction and treatment strategies of jaw osteonecrosis in cancer patients exposed to antiresorptive agents. *Future Oncology*, *10*, 257–275.
- Campisi, G., Mauceri, R., Bertoldo, F., Fusco, V., & Bedogni, A. (2021). A pragmatic window of opportunity to minimise the risk of MRONJ development in individuals with osteoporosis on Denosumab therapy: A hypothesis. *Head & Face Medicine*, *17*, 25.
- Campisi, G., Mauceri, R., Bertoldo, F., Bettini, G., Biasotto, M., Colella, G., Consolo, U., Di Fede, O., Favia, G., Fusco, V., Gabriele, M., Lo Casto, A., Lo Muzio, L., Marciàno, A., Mascitti, M., Meleti, M., Mignogna, M. D., Oteri, G., Panzarella, V., ... Bedogni, A. (2020). Medication-related osteonecrosis of jaws (MRONJ) prevention and diagnosis: Italian consensus update 2020. *International Journal of Environmental Research and Public Health*, *17*, 1–15.
- Cardoso, C. L., Barros, C. A., Curra, C., Fernandes, L. M., Franzolin, S. O., Júnior, J. S., De Antoni, C. C., & Curi, M. M. (2017). Radiographic findings in patients with medication-related osteonecrosis of the jaw. *International Journal of Dentistry*, *2017*, 3190301.
- Carlson, E. R. (2014). Management of antiresorptive osteonecrosis of the jaws with primary surgical resection. *Journal of Oral and Maxillofacial Surgery*, *72*, 655–657.
- Carlson, E. R., & Basile, J. D. (2009). The role of surgical resection in the management of bisphosphonate-related osteonecrosis of the jaws. *Journal of Oral and Maxillofacial Surgery*, *67*, 85–95.
- Carlson, E. R., Fleisher, K. E., & Ruggiero, S. L. (2013). Metastatic cancer identified in osteonecrosis specimens of the jaws in patients receiving intravenous bisphosphonate medications. *Journal of Oral and Maxillofacial Surgery*, *71*, 2077–2086.
- Cavalcante, R. C., & Tomasetti, G. (2020). Pentoxifylline and tocopherol protocol to treat medication-related osteonecrosis of the jaw: A systematic literature review. *Journal of Cranio-Maxillo-Facial Surgery*, *48*, 1080–1086.
- Cawson, R., et al. (2013). Cawson's essentials of Oral pathology and Oral medicine. *Cawson's Essentials of Oral Pathology and Oral Medicine*, *53*, 287.
- Choi, N. R., Lee, J. H., Park, J. Y., & Hwang, D. S. (2020). Surgical treatment of medication-related osteonecrosis of the jaw: A retrospective study. *International Journal of Environmental Research and Public Health*, *17*, 8801.
- Colella, G., Campisi, G., & Fusco, V. (2009). American Association of Oral and Maxillofacial Surgeons Position Paper: Bisphosphonate-related osteonecrosis of the jaws—2009 update: The need to refine the BRONJ definition. *Journal of Oral and Maxillofacial Surgery*, *67*, 2698–2699.
- Coleman, R., De Boer, R., Eidtmann, H., Llombart, A., Davidson, N., Neven, P., von Minckwitz, G., Sleeboom, H. P., Forbes, J., Barrios, C., Frassoldati, A., Campbell, I., Pajia, O., Martin, N., Modi, A., & Bundred, N. (2013). Zoledronic acid (zoledronate) for postmenopausal women with early breast cancer receiving adjuvant letrozole (ZO-FAST study): Final 60-month results. *Annals of Oncology*, *24*, 398–405.
- Coleman, R., Hadji, P., Body, J. J., Santini, D., Chow, E., Terpos, E., Oudard, S., Bruland, Ø., Flamen, P., Kurth, A., van Poznak, C., Aapro, M., & Jordan, K. (2020). Bone health in cancer: ESMO clinical practice guidelines. *Annals of Oncology*, *31*, 1650–1663.
- Comas-Calonge, A., Figueiredo, R., & Gay-Escoda, C. (2017). Surgical treatment vs. conservative treatment in intravenous bisphosphonate-related osteonecrosis of the jaws. Systematic review. *Journal of Clinical and Experimental Dentistry*, *9*, e302–e307.
- Cummings, S. R., Ferrari, S., Eastell, R., Gilchrist, N., Jensen, J. E. B., McClung, M., Roux, C., Törring, O., Valter, I., Wang, A. T., & Brown, J. P. (2018). Vertebral fractures after discontinuation of Denosumab: A post hoc analysis of the randomized placebo-controlled FREEDOM trial and its extension. *Journal of Bone and Mineral Research*, *33*, 190–198.
- Dal Prá, K. J., Lemos, C. A. A., Okamoto, R., Soubhia, A. M. P., & Pellizzer, E. P. (2017). Efficacy of the C-terminal telopeptide test in predicting the development of bisphosphonate-related osteonecrosis of the jaw: A systematic review. *International Journal of Oral and Maxillofacial Surgery*, *46*, 151–156.
- de França, T. R. T., de M Ramos-Perez, F. M., Pontual, A. D. A., de Castro, J. F. L., Bonan, P. R. F., & Perez, D. E. D. C. (2017). Effects of zoledronic acid in experimental periapical lesions in rats: An imaging and histological analysis. *Brazilian Dental Journal*, *28*, 566–572.
- de Oliveira, C. C., Brizeno, L. A. C., de Sousa, F. B., Mota, M. R. L., & Alves, A. P. N. N. (2016). Osteonecrosis of the jaw induced by receptor activator of nuclear factor-kappa B ligand (Denosumab) – review. *Medicina Oral, Patología Oral y Cirugía Bucal*, *21*, e431–e439.
- Del Fabbro, M., Galesio, G., & Mozzati, M. (2015). Autologous platelet concentrates for bisphosphonate-related osteonecrosis of the jaw treatment and prevention. A systematic review of the literature. *European Journal of Cancer*, *51*, 62–74.
- Devlin, H., Greenwall-Cohen, J., Benton, J., Goodwin, T. L., Littlewood, A., & Horner, K. (2018). Detecting the earliest radiological signs of bisphosphonate-related osteonecrosis. *British Dental Journal*, *224*, 26–31.
- Di Fede, O., Bedogni, A., Giancola, F., Saia, G., Bettini, G., Toia, F., D'Alessandro, N., Firenze, A., Matranga, D., Fedele, S., & Campisi, G. (2016). BRONJ in patients with rheumatoid arthritis: A multicenter case series. *Oral Diseases*, *22*, 543–548.
- Di Fede, O., Canepa, F., Panzarella, V., Mauceri, R., Del Gaizo, C., Bedogni, A., Fusco, V., Tozzo, P., Pizzo, G., Campisi, G., & Galvano, A. (2021). The treatment of medication-related osteonecrosis of the jaw (Mronj): A systematic review with a pooled analysis of only surgery versus combined protocols. *International Journal of Environmental Research and Public Health*, *18*, 8432.



- Di Fede, O., Del Gaizo, C., Panzarella, V., La Mantia, G., Tozzo, P., Di Grigoli, A., Lo Casto, A., Mauceri, R., & Campisi, G. (2022). Ozone infiltration for osteonecrosis of the jaw therapy: A case series. *Journal of Clinical Medicine*, *11*, 5307.
- Di Fede, O., Panzarella, V., Mauceri, R., Fusco, V., Bedogni, A., Lo Muzio, L., Board, S. O., & Campisi, G. (2018). The dental management of patients at risk of medication-related osteonecrosis of the jaw: New paradigm of primary prevention. *BioMed Research International*, *2018*, 1–10.
- Diana, A., Carlino, F., Giunta, E. F., Franzese, E., Guerrera, L. P., Di Lauro, V., Ciardiello, F., Daniele, B., & Orditura, M. (2021). Cancer treatment-induced bone loss (CTIBL): State of the art and proper Management in Breast Cancer Patients on endocrine therapy. *Current Treatment Options in Oncology*, *22*, 1–17.
- Dimopoulos, M. A., Kastiritis, E., Bamia, C., Melakopoulos, I., Gika, D., Roussou, M., Migkou, M., Eleftherakis-Papaiakovou, E., Christoulas, D., Terpos, E., & Bamias, A. (2009). Reduction of osteonecrosis of the jaw (ONJ) after implementation of preventive measures in patients with multiple myeloma treated with zoledronic acid. *Annals of Oncology*, *20*, 117–120.
- Don-Wauchope, A. C., & Cole, D. E. C. (2009). The (mis) use of bone resorption markers in the context of bisphosphonate exposure, dental surgery and osteonecrosis of the jaw. *Clinical Biochemistry*, *42*, 1194–1196.
- Dupont, J., Appermans, W., Dejaeger, M., Wauters, I., Laurent, M. R., & Gielen, E. (2022). Rebound-associated vertebral fractures after denosumab discontinuation in a lung cancer patient with bone metastases. *Bone Reports*, *16*, 101582.
- Eisen, A., Somerfield, M. R., Accordino, M. K., Blanchette, P. S., Clemons, M. J., Dhesy-Thind, S., Dillmon, M. S., D'Oronzo, S., Fletcher, G. G., Frank, E. S., Hallmeyer, S., Makhoul, I., Moy, B., Thawer, A., Wu, J. Y., & van Poznak, C. H. (2022). Use of adjuvant bisphosphonates and other bone-modifying agents in breast cancer: ASCO-OH (CCO) guideline update. *Journal of Clinical Oncology*, *40*, 787–800.
- El-Rabbany, M., Sgro, A., Lam, D. K., Shah, P. S., & Azarpazhooh, A. (2017). Effectiveness of treatments for medication-related osteonecrosis of the jaw: A systematic review and meta-analysis. *Journal of the American Dental Association (1939)*, *148*, 584–594.e2.
- Eming, S. A., & Krieg, T. (2006). Molecular mechanisms of VEGF-A action during tissue repair. *The Journal of Investigative Dermatology. Symposium Proceedings*, *11*, 79–86.
- Escobedo, M. F., Cobo, J. L., Junquera, S., Milla, J., Olay, S., & Junquera, L. M. (2020). Medication-related osteonecrosis of the jaw. Implant presence-triggered osteonecrosis: Case series and literature review. *Journal of Stomatology, Oral and Maxillofacial Surgery* *Journal of Stomatology, Oral and Maxillofacial Surgery*, *121*, 40–48.
- Everts-Graber, J., Lehmann, D., Burkard, J. P., Schaller, B., Gahl, B., Häuselmann, H. J., Studer, U., Ziswiler, H. R., Reichenbach, S., & Lehmann, T. (2022). Risk of osteonecrosis of the jaw under Denosumab compared to bisphosphonates in patients with osteoporosis. *Journal of Bone and Mineral Research*, *37*, 340–348.
- Fedele, S., Bedogni, G., Scoletta, M., Favia, G., Colella, G., Agrillo, A., Bettini, G., di Fede, O., Oteri, G., Fusco, V., Gabriele, M., Ottolenghi, L., Valsecchi, S., Porter, S., Fung, P. P. L., Saia, G., Campisi, G., & Bedogni, A. (2015). Up to a quarter of patients with osteonecrosis of the jaw associated with antiresorptive agents remain undiagnosed. *The British Journal of Oral & Maxillofacial Surgery*, *53*, 13–17.
- Fedele, S., Porter, S. R., D'Aiuto, F., Aljohani, S., Vescovi, P., Manfredi, M., Arduino, P. G., Broccoletti, R., Musciotto, A., di Fede, O., Lazarovici, T. S., Campisi, G., & Yarom, N. (2010). Nonexposed variant of bisphosphonate-associated osteonecrosis of the jaw: A case series. *The American Journal of Medicine*, *123*, 1060–1064.
- Ferlito, S., Puzzo, S., Palermo, F., & Verzi, P. (2012). Treatment of bisphosphonate-related osteonecrosis of the jaws: Presentation of a protocol and an observational longitudinal study of an Italian series of cases. *The British Journal of Oral & Maxillofacial Surgery*, *50*, 425–429.
- Fliefel, R., Tröltzsch, M., Kühnisch, J., Ehrenfeld, M., & Otto, S. (2015). Treatment strategies and outcomes of bisphosphonate-related osteonecrosis of the jaw (BRONJ) with characterization of patients: A systematic review. *International Journal of Oral and Maxillofacial Surgery*, *44*, 568–585.
- Fortunato, L., Bennardo, F., Buffone, C., & Giudice, A. (2020). Is the application of platelet concentrates effective in the prevention and treatment of medication-related osteonecrosis of the jaw? A systematic review. *Journal of Cranio-Maxillo-Facial Surgery*, *48*, 268–285.
- Franchi, S., Dosio, C., Pezzana, A., Brucoli, M., Boffano, P., Neirotti, F., Mazzer, A. M. N., Bonaso, M., & Accornero, A. (2021). *Management of Medication-Related Osteonecrosis of the jaws: A monoinstitutional experience*. Qeios.
- Freiberger, J. J., Padilla-Burgos, R., McGraw, T., Suliman, H. B., Kraft, K. H., Stolp, B. W., Moon, R. E., & Piantadosi, C. A. (2012). What is the role of hyperbaric oxygen in the Management of Bisphosphonate-Related Osteonecrosis of the jaw: A randomized controlled trial of hyperbaric oxygen as an adjunct to surgery and antibiotics. *Journal of Oral and Maxillofacial Surgery*, *70*, 1573–1583.
- Fujieda, Y., Doi, M., Asaka, T., Ota, M., Hisada, R., Ohnishi, N., Kono, M., Kameda, H., Nakazawa, D., Kato, M., Amengual, O., Takahata, M., Yasuda, S., Kitagawa, Y., & Atsumi, T. (2020). Incidence and risk of antiresorptive agent-related osteonecrosis of the jaw (ARONJ) after tooth extraction in patients with autoimmune disease. *Journal of Bone and Mineral Metabolism*, *38*, 581–588.
- Fung, P., Bedogni, G., Bedogni, A., Petrie, A., Porter, S., Campisi, G., Bagan, J., Fusco, V., Saia, G., Acham, S., Musto, P., Petrucci, M. T., Diz, P., Colella, G., Mignogna, M. D., Pentenero, M., Arduino, P., Lodi, G., Maiorana, C., ... Fedele, S. (2017). Time to onset of bisphosphonate-related osteonecrosis of the jaws: A multicentre retrospective cohort study. *Oral Diseases*, *23*, 477–483.
- Fusco, V., Campisi, G., & Bedogni, A. (2022). One changing and challenging scenario: The treatment of cancer patients with bone metastases by bisphosphonates and denosumab, the cost-benefit evaluation of different options, and the risk of medication-related osteonecrosis of the jaw (MRONJ). *Support Care Cancer*, *30*, 7047–7051.
- Fusco, V., Galassi, C., Berruti, A., Ciuffreda, L., Ortega, C., Ciccone, G., Angeli, A., & Bertetto, O. (2011). Osteonecrosis of the jaw after zoledronic acid and denosumab treatment. *Journal of Clinical Oncology*, *29*, e521–e522. author reply e523–4.
- Fusco, V., Mauceri, R., Campisi, G., & Bedogni, A. (2022). RE: American Association of Oral and Maxillofacial Surgeons' position paper on medication-related osteonecrosis of the jaws—2022 update: Quantitative risk assessment and controversial issues, *80*, 1871–1873.
- Fusco, V., Rossi, M., Fasciolo, A., Gambino, A., & Palmeri, S. (2022). Prognosis of metastatic bone cancer and myeloma patients and long-term risk of medication-related osteonecrosis of the jaw (MRONJ): Some critical points. *Supportive Care in Cancer*, *30*, 9707–9709.
- Fusco, V., Santini, D., Armento, G., Tonini, G., & Campisi, G. (2016). Osteonecrosis of jaw beyond antiresorptive (bone-targeted) agents: New horizons in oncology. *Expert Opinion on Drug Safety*, *15*, 925–935.
- Gander, T., Obwegeser, J. A., Zemmann, W., Grätz, K. W., & Jacobsen, C. (2014). Malignancy mimicking bisphosphonate-associated osteonecrosis of the jaw: A case series and literature review. *Oral Surgery, Oral Medicine, Oral Pathology, Oral Radiology*, *117*, 32–36.
- García-Ferrer, L., Bagán, J. V., Martínez-Sanjuan, V., Hernandez-Bazan, S., García, R., Jiménez-Soriano, Y., & Hervas, V. (2008). MRI of mandibular osteonecrosis secondary to bisphosphonates. *American Journal of Roentgenology*, *190*, 949–955.

- Gaudin, E., Seidel, L., Bacevic, M., Rompen, E., & Lambert, F. (2015). Occurrence and risk indicators of medication-related osteonecrosis of the jaw after dental extraction: A systematic review and meta-analysis. *Journal of Clinical Periodontology*, *42*, 922–932.
- Giovannacci, I., Meleti, M., Manfredi, M., Mortellaro, C., Greco Lucchina, A., Bonanini, M., & Vescovi, P. (2016). Medication-related osteonecrosis of the jaw around dental implants: Implant surgery-triggered or implant presence-triggered osteonecrosis? *The Journal of Craniofacial Surgery*, *27*, 697–701.
- Giovannacci, I., Vescovi, P., Magnoni, C., Corradi, D., Corcione, L., Lucchina, A. G., Mortellaro, C., Nammour, S., & Meleti, M. (2019). Auto-fluorescence and histopathologic evaluation of medication-related osteonecrosis of the jaws: Perspectives for treatment. *The Journal of Craniofacial Surgery*, *30*, 1039–1043.
- Giudice, A., Barone, S., Diodati, F., Antonelli, A., Nocini, R., & Cristofaro, M. G. (2020). Can surgical management improve resolution of medication-related osteonecrosis of the jaw at early stages? A prospective cohort study. *Journal of Oral and Maxillofacial Surgery*, *78*, 1986–1999.
- Gkouveris, I., Hadaya, D., Soundia, A., Bezouglaia, O., Chau, Y., Dry, S. M., Piri, F. Q., Aghaloo, T. L., & Tetradis, S. (2019). Vasculature submucosal changes at early stages of osteonecrosis of the jaw (ONJ). *Bone*, *123*, 234–245.
- Gnant, M., Pfeiler, G., Steger, G. G., Egle, D., Greil, R., Fitzal, F., Wette, V., Balic, M., Haslbauer, F., Melbinger-Zeinitzer, E., Bjelic-Radicic, V., Jakesz, R., Marth, C., Sevelde, P., Mlineritsch, B., Exner, R., Fesl, C., Frantal, S., Singer, C. F., & Austrian Breast and Colorectal Cancer Study Group. (2019). Adjuvant denosumab in postmenopausal patients with hormone receptor-positive breast cancer (ABCSC-18): Disease-free survival results from a randomised, double-blind, placebo-controlled, phase 3 trial. *The Lancet Oncology*, *20*, 339–351.
- Guarnieri, R., Di Nardo, D., Di Giorgio, G., Miccoli, G., & Testarelli, L. (2021). Longevity of teeth and dental implants in patients treated for chronic periodontitis following periodontal maintenance therapy in a private specialist practice: A retrospective study with a 10-year follow-up. *The International Journal of Periodontics & Restorative Dentistry*, *41*, 89–98.
- Guggenberger, R., Koral, E., Zemann, W., Jacobsen, C., Andreisek, G., & Metzler, P. (2014). Cone beam computed tomography for diagnosis of bisphosphonate-related osteonecrosis of the jaw: Evaluation of quantitative and qualitative image parameters. *Skeletal Radiology*, *43*, 1669–1678.
- Guo, Y., Wang, D., Wang, Y., Peng, X., & Guo, C. (2016). Imaging features of medicine-related osteonecrosis of the jaws: Comparison between panoramic radiography and computed tomography. *Oral Surgery, Oral Medicine, Oral Pathology, Oral Radiology*, *122*, e69–e76.
- Hadaya, D., Soundia, A., Gkouveris, I., Bezouglaia, O., Dry, S. M., Piri, F. Q., Aghaloo, T. L., & Tetradis, S. (2021). Antiresorptive-type and discontinuation-timing affect ONJ burden. *Journal of Dental Research*, *100*, 746–753.
- Hadaya, D., Soundia, A., Gkouveris, I., Dry, S. M., Aghaloo, T. L., & Tetradis, S. (2019). Development of medication-related osteonecrosis of the jaw after extraction of teeth with experimental periapical disease. *Journal of Oral and Maxillofacial Surgery*, *77*, 71–86.
- Hasegawa, T., Hayashida, S., Kondo, E., et al. (2019). Medication-related osteonecrosis of the jaw after tooth extraction in cancer patients: A multicenter retrospective study. *Osteoporosis International*, *30*, 231–239.
- Hasegawa, T., Kawakita, A., Ueda, N., Funahara, R., Tachibana, A., Kobayashi, M., Kondou, E., Takeda, D., Kojima, Y., Sato, S., Yanamoto, S., Komatsubara, H., Umeda, M., Kirita, T., Kurita, H., Shibuya, Y., Komori, T., & Japanese Study Group of Cooperative Dentistry with Medicine (JCDM). (2017). A multicenter retrospective study of the risk factors associated with medication-related osteonecrosis of the jaw after tooth extraction in patients receiving oral bisphosphonate therapy: can primary wound closure and a drug holiday really prevent MRONJ? *Osteoporosis International*, *28*, 2465–2473.
- Hasegawa, T., Ueda, N., Yamada, S. I., Kato, S., Iwata, E., Hayashida, S., Kojima, Y., Shinohara, M., Tojo, I., Nakahara, H., Yamaguchi, T., Kirita, T., Kurita, H., Shibuya, Y., Soutome, S., Akashi, M., & Japanese Study Group of Co-operative Dentistry with Medicine (JCDM). (2021). Denosumab-related osteonecrosis of the jaw after tooth extraction and the effects of a short drug holiday in cancer patients: A multicenter retrospective study. *Osteoporosis International*, *32*, 2323–2333.
- Hasegawa, Y., Kawabe, M., Kimura, H., Kurita, K., Fukuta, J., & Urade, M. (2012). Influence of dentures in the initial occurrence site on the prognosis of bisphosphonate-related osteonecrosis of the jaws: A retrospective study. *Oral Surgery, Oral Medicine, Oral Pathology, Oral Radiology*, *114*, 318–324.
- Hata, H., Imamachi, K., Ueda, M., Matsuzaka, M., Hiraga, H., Osana, T., Harabayashi, T., Fujimoto, K., Oizumi, S., Takahashi, M., Yoshikawa, K., Sato, J., Yamazaki, Y., & Kitagawa, Y. (2022). Prognosis by cancer type and incidence of zoledronic acid-related osteonecrosis of the jaw: A single-center retrospective study. *Support Care Cancer*, *30*, 4505–4514.
- Hayashida, S., Soutome, S., Yanamoto, S., Fujita, S., Hasegawa, T., Komori, T., Kojima, Y., Miyamoto, H., Shibuya, Y., Ueda, N., Kirita, T., Nakahara, H., Shinohara, M., & Umeda, M. (2017). Evaluation of the treatment strategies for medication-related osteonecrosis of the jaws (MRONJ) and the factors affecting treatment outcome: A multicenter retrospective study with propensity score matching analysis. *Journal of Bone and Mineral Research*, *32*, 2022–2029.
- Hayashida, S., Yanamoto, S., Fujita, S., Hasegawa, T., Komori, T., Kojima, Y., Miyamoto, H., Shibuya, Y., Ueda, N., Kirita, T., Nakahara, H., Shinohara, M., Kondo, E., Kurita, H., & Umeda, M. (2020). Drug holiday clinical relevance verification for antiresorptive agents in medication-related osteonecrosis cases of the jaw. *Journal of Bone and Mineral Metabolism*, *38*, 126–134.
- Heim, N., Warwas, F. B., Wilms, C. T., Reich, R. H., & Martini, M. (2017). Vitamin D (25-OHD) deficiency may increase the prevalence of medication-related osteonecrosis of the jaw. *Journal of Cranio-Maxillo-Facial Surgery*, *45*, 2068–2074.
- Heufelder, M. J., Hendricks, J., Remmerbach, T., Frerich, B., Hemprich, A., & Wilde, F. (2014). Principles of oral surgery for prevention of bisphosphonate-related osteonecrosis of the jaw. *Oral Surgery, Oral Medicine, Oral Pathology, Oral Radiology*, *117*, e429–e435.
- Hoefert, S., & Eufinger, H. (2011). Relevance of a prolonged preoperative antibiotic regime in the treatment of bisphosphonate-related osteonecrosis of the jaw. *Journal of Oral and Maxillofacial Surgery*, *69*, 362–380.
- Hokugo, A., Christensen, R., Chung, E. M., Sung, E. C., Felsenfeld, A. L., Sayre, J. W., Garrett, N., Adams, J. S., & Nishimura, I. (2010). Increased prevalence of bisphosphonate-related osteonecrosis of the jaw with vitamin D deficiency in rats. *Journal of Bone and Mineral Research*, *25*, 1337–1349.
- Huber, F. A., Schumann, P., von Spiczak, J., Wurnig, M. C., Klarhöfer, M., Finkenstaedt, T., Bedogni, A., & Guggenberger, R. (2020). Medication-related osteonecrosis of the jaw-comparison of bone imaging using ultrashort Echo-time magnetic resonance imaging and cone-beam computed tomography. *Investigative Radiology*, *55*, 160–167.
- Hutchinson, M., O’Ryan, F., Chavez, V., Lathon, P. V., Sanchez, G., Hatcher, D. C., Indresano, A. T., & Lo, J. C. (2010). Radiographic findings in bisphosphonate-treated patients with stage 0 disease in the absence of bone exposure. *Journal of Oral and Maxillofacial Surgery*, *68*, 2232–2240.
- Ikesue, H., Doi, K., Morimoto, M., Hirabatake, M., Muroi, N., Yamamoto, S., Takenobu, T., & Hashida, T. (2021). Switching from zoledronic acid to denosumab increases the risk for developing medication-related



- osteonecrosis of the jaw in patients with bone metastases. *Cancer Chemotherapy and Pharmacology*, 87, 871–877.
- Ikesue, H., Mouri, M., Tomita, H., Hirabatake, M., Ikemura, M., Muroi, N., Yamamoto, S., Takenobu, T., Tomii, K., Kawakita, M., Katoh, H., Ishikawa, T., Yasui, H., & Hashida, T. (2021). Associated characteristics and treatment outcomes of medication-related osteonecrosis of the jaw in patients receiving denosumab or zoledronic acid for bone metastases. *Support Care Cancer*, 29, 4763–4772.
- Inderjeeth, C. A., Glendenning, P., Ratnagobal, S., Inderjeeth, D. C., & Ondhia, C. (2014). Long-term efficacy, safety, and patient acceptability of ibandronate in the treatment of postmenopausal osteoporosis. *International Journal of Women's Health*, 7, 7–17.
- Inoue, M., Matsumoto, C., Nakajima, K., Kuroshima, S., & Sawase, T. (2021). Alendronate/dexamethasone combination therapy worsens soft and hard tissue wound healing around implants in rat maxillae. *Bone*, 148, 115942.
- Jacobson, D., Cadieux, B., Higano, C. S., Henry, D. H., Bachmann, B. A., Rehn, M., Stopeck, A. T., & Saad, H. (2022). Risk factors associated with skeletal-related events following discontinuation of denosumab treatment among patients with bone metastases from solid tumors: A real-world machine learning approach. *Journal of Bone Oncology*, 34, 100423.
- Jadu, F., Lee, L., Pharoah, M., Reece, D., & Wang, L. (2007). A retrospective study assessing the incidence, risk factors and comorbidities of pamidronate-related necrosis of the jaws in multiple myeloma patients. *Annals of Oncology*, 18, 2015–2019.
- Japanese Allied Committee On Osteonecrosis Of The Jaw, Yoneda, T., Hagino, H., et al. (2017). Antiresorptive agent-related osteonecrosis of the jaw: Position paper 2017 of the Japanese allied committee on osteonecrosis of the jaw. *Journal of Bone and Mineral Metabolism*, 35, 6–19.
- Jeong, H.-G. G., Hwang, J. J., Lee, J.-H. H., Kim, Y. H., Na, J. Y., & Han, S.-S. S. (2017). Risk factors of osteonecrosis of the jaw after tooth extraction in osteoporotic patients on oral bisphosphonates. *Imaging Sci Dent*, 47, 45–50.
- Jiang, C. Y., Zhao, L., Schuetze, S. M., & Chugh, R. (2022). Giant cell tumor of bone: Effect of longer dosing intervals of Denosumab on tumor control and bone-related complications. *The Oncologist*, 27, 595–599.
- Jung, S. Y., Suh, H. S., Park, J. W., & Kwon, J. W. (2019). Drug holiday patterns and bisphosphonate-related osteonecrosis of the jaw. *Oral Diseases*, 25, 471–480.
- Junquera, L., & Gallego, L. (2008). Nonexposed bisphosphonate-related osteonecrosis of the jaws: Another clinical variant? *Journal of Oral and Maxillofacial Surgery*, 66, 1516–1517.
- Kang, S. H., Park, S. J., & Kim, M. K. (2020). The effect of bisphosphonate discontinuation on the incidence of postoperative medication-related osteonecrosis of the jaw after tooth extraction. *Journal of the Korean Association of Oral and Maxillofacial Surgeons*, 46, 78–83.
- Kawahara, M., Kuroshima, S., & Sawase, T. (2021). Clinical considerations for medication-related osteonecrosis of the jaw: A comprehensive literature review. *International Journal of Implant Dentistry*, 7, 47.
- Khan, A. A., Morrison, A., Hanley, D. A., Felsenberg, D., McCauley, L. K., O'Ryan, F., Reid, I. R., Ruggiero, S. L., Taguchi, A., Tetradis, S., Watts, N. B., Brandi, M. L., Peters, E., Guise, T., Eastell, R., Cheung, A. M., Morin, S. N., Masri, B., Cooper, C., ... The International Task Force on Osteonecrosis of the Jaw. (2015). Diagnosis and management of osteonecrosis of the jaw: A systematic review and international consensus. *Journal of Bone and Mineral Research*, 30, 3–23.
- Khominsky, A., & Lim, M. A. W. T. (2018). "Spontaneous" medication-related osteonecrosis of the jaw; two case reports and a systematic review. *Australian Dental Journal*, 63, 441–454.
- Kim, H. Y., Lee, S. J., Kim, S. M., Myoung, H., Hwang, S. J., Choi, J. Y., Lee, J. H., Choung, P. H., Kim, M. J., & Seo, B. M. (2017). Extensive surgical procedures result in better treatment outcomes for bisphosphonate-related osteonecrosis of the jaw in patients with osteoporosis. *Journal of Oral and Maxillofacial Surgery*, 75, 1404–1413.
- Kim, J. E., Yoo, S., & Choi, S. C. (2020). Several issues regarding the diagnostic imaging of medication-related osteonecrosis of the jaw. *Imaging Science in Dentistry*, 50, 273–279.
- King, R., Tanna, N., & Patel, V. (2019). Medication-related osteonecrosis of the jaw unrelated to bisphosphonates and denosumab—a review. *Oral Surgery, Oral Medicine, Oral Pathology, Oral Radiology*, 127, 289–299.
- Kobayashi, Y., Hiraga, T., Ueda, A., Wang, L., Matsumoto-Nakano, M., Hata, K., Yatani, H., & Yoneda, T. (2010). Zoledronic acid delays wound healing of the tooth extraction socket, inhibits oral epithelial cell migration, and promotes proliferation and adhesion to hydroxyapatite of oral bacteria, without causing osteonecrosis of the jaw, in mice. *Journal of Bone and Mineral Metabolism*, 28, 165–175.
- Koerdt, S., Dax, S., Grimaldi, H., Ristow, O., Kuebler, A. C., & Reuther, T. (2014). Histomorphologic characteristics of bisphosphonate-related osteonecrosis of the jaw. *Journal of Oral Pathology & Medicine*, 43, 448–453.
- Kuo, P. I., Lin, T. M., Chang, Y. S., Hou, T. Y., Hsu, H. C., Lin, S. H., Chen, W. S., Lin, Y. C., Wang, L. H., Chang, C. C., & Chen, J. H. (2021). Primary Sjogren syndrome increases the risk of bisphosphonate-related osteonecrosis of the jaw. *Scientific Reports*, 11, 1612.
- Kwon, T. G., Lee, C. O., Park, J. W., Choi, S. Y., Rijal, G., & Shin, H. I. (2014). Osteonecrosis associated with dental implants in patients undergoing bisphosphonate treatment. *Clinical Oral Implants Research*, 25, 632–640.
- Kyrgidis, A., Vahtsevanos, K., Koloutsos, G., Andreadis, C., Boukovinas, I., Teleioudis, Z., Patrikidou, A., & Triaridis, S. (2008). Bisphosphonate-related osteonecrosis of the jaws: A case-control study of risk factors in breast cancer patients. *Journal of Clinical Oncology*, 26, 4634–4638.
- Landesberg, R., Cozin, M., Cremers, S., Woo, V., Kousteni, S., Sinha, S., Garrett-Sinha, L. A., & Raghavan, S. (2008). Inhibition of Oral mucosal cell wound healing by bisphosphonates. *Journal of Oral and Maxillofacial Surgery*, 66, 839–847.
- LeBoff, M. S., Greenspan, S. L., Insogna, K. L., et al. (2022). The clinician's guide to prevention and treatment of osteoporosis. *Osteoporosis International*, 33, 2049–2102.
- Lee, J. K., Kim, K.-W., Choi, J.-Y., Moon, S. Y., Kim, S. G., Kim, C. H., Kim, H. M., Kwon, Y. D., Kim, Y. D., Lee, D. K., Min, S. K., Park, I. S., Park, Y. W., Kook, M. S., Park, H. J., Baek, J. A., Park, J. W., & Kwon, T. G. (2013). Bisphosphonates-related osteonecrosis of the jaw in Korea: A preliminary report. *Journal of the Korean Association of Oral and Maxillofacial Surgeons*, 39, 9–13.
- Leite, A. F., Ogata, F. D. S., de Melo, N. S., & Figueiredo, P. T. D. S. (2014). Imaging findings of bisphosphonate-related osteonecrosis of the jaws: A critical review of the quantitative studies. *International Journal of Dentistry*, 2014, 784348.
- Levin, L., Laviv, A., & Schwartz-Arad, D. (2007). Denture-related osteonecrosis of the maxilla associated with oral bisphosphonate treatment. *Journal of the American Dental Association (1939)*, 138, 1218–1220.
- Liao, M. T., Chien, W. C., Wang, J. C., Chung, C. H., Chu, S. J., & Tsai, S. H. (2019). Increased risk of bisphosphonate-related osteonecrosis of the jaw in patients with Sjögren's syndrome: Nationwide population-based cohort study. *BMJ Open*, 9, e024655.
- Lorenzo-Pouso, A. I., Pérez-Sayáns, M., Chamorro-Petronacci, C., Gándara-Vila, P., López-Jornet, P., Carballo, J., & García-García, A. (2020). Association between periodontitis and medication-related osteonecrosis of the jaw: A systematic review and meta-analysis. *Journal of Oral Pathology & Medicine*, 49, 190–200.
- Loyson, T., Van Cann, T., Schöffski, P., Clement, P. M., Bechter, O., Spriet, I., Coropciuc, R., Politis, C., Vandeweyer, R. O., Schoenaers, J., Dumez, H., Berteloot, P., Neven, P., Nackaerts, K., Woei-A-Jin, F. J. S. H., Punie, K., Wildiers, H., & Beuselinck, B. (2018). Incidence of osteonecrosis

- of the jaw in patients with bone metastases treated sequentially with bisphosphonates and denosumab. *Acta Clinica Belgica: International Journal of Clinical and Laboratory Medicine*, 73, 100–109.
- Lyu, H., Zhao, S. S., Yoshida, K., Tedeschi, S. K., Xu, C., Nigwekar, S. U., Leder, B. Z., & Solomon, D. H. (2020). Delayed denosumab injections and bone mineral density response: An electronic health record-based study. *The Journal of Clinical Endocrinology and Metabolism*, 105, 1435–1444.
- Maj, E., Papiernik, D., & Wietrzyk, J. (2016). Antiangiogenic cancer treatment: The great discovery and greater complexity (review). *International Journal of Oncology*, 49, 1773–1784.
- Malina-Altzinger, J., Klaeser, B., Suter, V. G. A. A., Schriber, M., Vollnberg, B., & Schaller, B. (2019). Comparative evaluation of SPECT/CT and CBCT in patients with mandibular osteomyelitis and osteonecrosis. *Clinical Oral Investigations*, 23, 4213–4222.
- Marcianò, A., Ieni, A., Mauceri, R., & Oteri, G. (2021). Cd34 and cd105 microvessels in resected bone specimen may implicate wound healing in mronj. *International Journal of Environmental Research and Public Health*, 18, 11362.
- Marcianò, A., Ingrassiotta, Y., Isgrò, V., L'Abbate, L., Foti, S. S., Picone, A., Peditto, M., Guzzo, G. M., Alibrandi, A., & Oteri, G. (2021). Cancer patients at risk for medication-related osteonecrosis of the jaw. A case and control study analyzing predictors of mronj onset. *Journal of Clinical Medicine*, 10, 4762.
- Markson, L. E., Nash, D. B., Louis, D. Z., & Gonnella, J. S. (1991). Clinical outcomes management and disease staging. *Evaluation & the Health Professions*, 14, 201–227.
- Marx, R. E. (2003). Pamidronate (Aredia) and zoledronate (Zometa) induced avascular necrosis of the jaws: A growing epidemic. *Journal of Oral and Maxillofacial Surgery*, 61, 1115–1117.
- Mauceri, R., Coniglio, R., Abbinante, A., Carcieri, P., Tomassi, D., Panzarella, V., di Fede, O., Bertoldo, F., Fusco, V., Bedogni, A., & Campisi, G. (2022). The preventive care of medication-related osteonecrosis of the jaw (MRONJ): A position paper by Italian experts for dental hygienists. *Supportive Care in Cancer*, 30, 6429–6440.
- Mauceri, R., Panzarella, V., Maniscalco, L., Bedogni, A., Licata, M. E., Albanese, A., Toia, F., Cumbo, E. M. G., Mazzola, G., di Fede, O., & Campisi, G. (2018). Conservative surgical treatment of bisphosphonate-related osteonecrosis of the jaw with Er,Cr:YSGG laser and platelet-rich plasma: A longitudinal study. *BioMed Research International*, 2018, 1–10.
- Mauceri, R., Toro, C., Panzarella, V., Carbone, M. I., Rodolico, V., & Campisi, G. (2021). Oral squamous cell carcinoma mimicking medication-related osteonecrosis of the jaws (MRONJ): A case series. *Oral*, 1, 326–331.
- McClung, M. R., Lewiecki, E. M., Cohen, S. B., et al. (2006). Denosumab in postmenopausal women with low bone mineral density. *The New England Journal of Medicine*, 354, 821–831.
- McClung, M. R., Wagman, R. B., Miller, P. D., Wang, A., & Lewiecki, E. M. (2017). Observations following discontinuation of long-term denosumab therapy. *Osteoporosis International*, 28, 1723–1732.
- McGowan, K., Acton, C., Ivanovski, S., Johnson, N. W., & Ware, R. S. (2019). Systemic comorbidities are associated with medication-related osteonecrosis of the jaws: Case-control study. *Oral Diseases*, 25, 1107–1115.
- McGowan, K., McGowan, T., & Ivanovski, S. (2018). Risk factors for medication-related osteonecrosis of the jaws: A systematic review. *Oral Diseases*, 24, 527–536.
- Migliario, M., Mergoni, G., Vescovi, P., Martino, I. D., Alessio, M., Benzi, L., Renò, F., & Fusco, V. (2017). Osteonecrosis of the jaw (ONJ) in osteoporosis patients: Report of delayed diagnosis of a multisite case and commentary about risks coming from a restricted ONJ definition. *Dental Journal*, 5, 13.
- Miksad, R. A., Lai, K.-C., Dodson, T. B., Woo, S. B., Treister, N. S., Akinyemi, O., Bihle, M., Maytal, G., August, M., Gazelle, G. S., & Swan, J. S. (2011). Quality of life implications of bisphosphonate-associated osteonecrosis of the jaw. *The Oncologist*, 16, 121–132.
- Moraschini, V., Calasans-Maia, M. D., Louro, R. S., Arantes, E. B. R., & Calasans-Maia, J. A. (2021). Weak evidence for the management of medication-related osteonecrosis of the jaw: An overview of systematic reviews and meta-analyses. *Journal of Oral Pathology & Medicine*, 50, 10–21.
- Moraschini, V., de Almeida, D. C. F., Figueredo, C. M., & Calasans-Maia, M. D. (2019). Association between biomarkers and medication-related osteonecrosis of the jaws: A systematic review. *Oral Surgery, Oral Medicine, Oral Pathology, Oral Radiology*, 127, 504–515.
- Moreno-Rabié, C., Lapauw, L., Gaëta-Araujo, H., Ferreira-Leite, A., Coucke, W., van den Wyngaert, T., & Jacobs, R. (2022). Radiographic predictors for MRONJ in oncologic patients undergoing tooth extraction. *Scientific Reports*, 12, 11280.
- Moretti, F., Pelliccioni, G. A., Montebugnoli, L., & Marchetti, C. (2011). A prospective clinical trial for assessing the efficacy of a minimally invasive protocol in patients with bisphosphonate-associated osteonecrosis of the jaws. *Oral Surgery, Oral Medicine, Oral Pathology, Oral Radiology, and Endodontology*, 112, 777–782.
- Morishita, K., Soutome, S., Otsuru, M., Hayashida, S., Murata, M., Sasaki, M., Takagi, Y., Sumi, M., & Umeda, M. (2022). Relationship between drug holiday of the antiresorptive agents and surgical outcome of medication-related osteonecrosis of the jaw in osteoporosis patients. *Scientific Reports*, 12, 11545.
- Morishita, K., Yamada, S. I., Kawakita, A., Hashidume, M., Tachibana, A., Takeuchi, N., Ohbayashi, Y., Kanno, T., Yoshiga, D., Narai, T., Sasaki, N., Shinohara, H., Uzawa, N., Miyake, M., Tominaga, K., Kodani, I., Umeda, M., & Kurita, H. (2020). Treatment outcomes of adjunctive teriparatide therapy for medication-related osteonecrosis of the jaw (MRONJ): A multicenter retrospective analysis in Japan. *Journal of Orthopaedic Science*, 25, 1079–1083.
- Mücke, T., Deppe, H., Hein, J., Wolff, K. D., Mitchell, D. A., Kesting, M. R., Retz, M., Gschwend, J. E., & Thalgot, M. (2016). Prevention of bisphosphonate-related osteonecrosis of the jaws in patients with prostate cancer treated with zoledronic acid – A prospective study over 6 years. *Journal of Cranio-Maxillofacial Surgery*, 44, 1689–1693.
- Mücke, T., Krestan, C. R., Mitchell, D. A., Kirschke, J. S., & Wutzl, A. (2016). Bisphosphonate and medication-related osteonecrosis of the jaw: A review. *Seminars in Musculoskeletal Radiology*, 20, 305–314.
- Nakai, Y., Kanaki, T., Yamamoto, A., Tanaka, R., Yamamoto, Y., Nagahara, A., Nakayama, M., Kakimoto, K. I., Ishibashi, M., & Nishimura, K. (2021). Antiresorptive agent-related osteonecrosis of the jaw in prostate cancer patients with bone metastasis treated with bone-modifying agents. *Journal of Bone and Mineral Metabolism*, 39, 295–301.
- Narayanan, P. (2013). Denosumab: A comprehensive review. *South Asian Journal of Cancer*, 2, 272–277.
- Nicolatou-Galitis, O., Kouri, M., Papadopoulou, E., Vardas, E., Galiti, D., Epstein, J. B., Elad, S., Campisi, G., Tsoukalas, N., Bektas-Kayhan, K., Tan, W., Body, J. J., Migliorati, C., Lalla, R. V., & MASCC Bone Study Group. (2019). Osteonecrosis of the jaw related to non-antiresorptive medications: A systematic review. *Support Care Cancer*, 27, 383–394.
- Nicolatou-Galitis, O., Papadopoulou, E., Vardas, E., Kouri, M., Galiti, D., Galitis, E., Alexiou, K. E., Tsiklakis, K., Ardavanis, A., Razis, E., Athanasiadis, I., Droufakou, S., Psyrris, A., Karamouzis, M. V., Linardou, H., Daliani, D., Tzanninis, D., Sachanas, S., Laschos, K., ... Ripamonti, C. I. (2020). Alveolar bone histological necrosis observed prior to extractions in patients, who received bone-targeting agents. *Oral Diseases*, 26, 955–966.
- Nicolatou-Galitis, O., Razis, E., Galiti, D., Galitis, E., Labropoulos, S., Tsimpidakis, A., Sgouros, J., Karampeazis, A., & Migliorati, C. (2015). Periodontal disease preceding osteonecrosis of the jaw (ONJ) in cancer patients receiving antiresorptives alone or combined with



- targeted therapies: Report of 5 cases and literature review. *Oral Surgery, Oral Medicine, Oral Pathology, Oral Radiology*, 120, 699–706.
- Nicolatou-Galitis, O., Schiødt, M., Mendes, R. A., Ripamonti, C., Hope, S., Dudge-Coates, L., Niepel, D., & van den Wyngaert, T. (2019). Medication-related osteonecrosis of the jaw: Definition and best practice for prevention, diagnosis, and treatment. *Oral Surgery, Oral Medicine, Oral Pathology, Oral Radiology*, 127, 117–135.
- Nisi, M., Izzetti, R., Gennai, S., Bellini, P., Graziani, F., & Gabriele, M. (2020). Surgical Management of Medication-Related Osteonecrosis of the jaw patients related to dental implants. *The Journal of Craniofacial Surgery*, 31, 1037–1041.
- Ogura, I., Minami, Y., Ono, J., Kanri, Y., Okada, Y., Igarashi, K., Haga-Tsujimura, M., Nakahara, K., & Kobayashi, E. (2021). CBCT imaging and histopathological characteristics of osteoradionecrosis and medication-related osteonecrosis of the jaw. *Imaging Science in Dentistry*, 51, 73–80.
- O'Halloran, M., Boyd, N. M., & Smith, A. (2014). Denosumab and osteonecrosis of the jaws - the pharmacology, pathogenesis and a report of two cases. *Australian Dental Journal*, 59, 516–519.
- Okuyama, K., Hayashida, S., Rokutanda, S., Kawakita, A., Soutome, S., Sawada, S., Yanamoto, S., Kojima, Y., & Umeda, M. (2021). Surgical strategy for medication-related osteonecrosis of the jaw (MRONJ) on maxilla: A multicenter retrospective study. *Journal of Dental Sciences*, 16, 885–890.
- Omori, K., Otsuru, M., Morishita, K., Hayashida, S., Suyama, K., Naruse, T., Soutome, S., & Umeda, M. (2022). Ineffectiveness of Antiresorptive agent drug holidays in osteoporosis patients for treatment of medication-related osteonecrosis of the jaw: Consideration from Immunohistological observation of osteoclast suppression and treatment outcomes. *International Journal of Environmental Research and Public Health*, 19, 10898.
- Oteri, G., De Ponte, F. S., Runci, M., Peditto, M., Marciàno, A., & Cicciù, M. (2017). Oral-health-related quality of life after surgical treatment of osteonecrosis of the jaws. *The Journal of Craniofacial Surgery*, 29, 403–408.
- Otsuru, M., Soutome, S., Omori, K., Suyama, K., Morishita, K., Hayashida, S., Murata, M., Takagi, Y., Sasaki, M., Sumi, M., Kojima, Y., Sawada, S., Sakamoto, Y., & Umeda, M. (2022). Relationship between drug holidays of Antiresorptive agents and surgical outcomes in cancer patients with medication-related osteonecrosis of the jaw. *International Journal of Environmental Research and Public Health*, 19, 4624.
- Ottesen, C., Schiødt, M., & Gotfredsen, K. (2020). Efficacy of a high-dose antiresorptive drug holiday to reduce the risk of medication-related osteonecrosis of the jaw (MRONJ): A systematic review. *Heliyon*, 6, e03795.
- Otto, S., Aljohani, S., Fliefel, R., Ecke, S., Ristow, O., Burian, E., Tröltzsch, M., Pautke, C., & Ehrenfeld, M. (2021). Infection as an important factor in medication-related osteonecrosis of the jaw (MRONJ). *Medicina*, 57, 463.
- Otto, S., Baumann, S., Ehrenfeld, M., & Pautke, C. (2013). Successful surgical management of osteonecrosis of the jaw due to RANK-ligand inhibitor treatment using fluorescence guided bone resection. *Journal of Cranio-Maxillo-Facial Surgery*, 41, 694–698.
- Otto, S., Hafner, S., & Grötz, K. A. (2009). The role of inferior alveolar nerve involvement in bisphosphonate-related osteonecrosis of the jaw. *Journal of Oral and Maxillofacial Surgery*, 67, 589–592.
- Otto, S., Marx, R. E., Tröltzsch, M., Ristow, O., Ziebart, T., al-Nawas, B., Groetz, K. A., Ehrenfeld, M., Mercadante, V., Porter, S., Bedogni, A., Campisi, G., Fusco, V., Dayisoğlu, E., Fliefel, R., Herlofson, B. B., Pautke, C., Kwon, T. G., & Fedele, S. (2015). Comments on 'diagnosis and management of osteonecrosis of the jaw: A systematic review and international consensus'. *Journal of Bone and Mineral Research*, 30, 1113–1115.
- Otto, S., Pautke, C., Van den Wyngaert, T., Niepel, D., & Schiødt, M. (2018). Medication-related osteonecrosis of the jaw: Prevention, diagnosis and management in patients with cancer and bone metastases. *Cancer Treatment Reviews*, 69, 177–187.
- Otto, S., Schreyer, C., Hafner, S., Mast, G., Ehrenfeld, M., Stürzenbaum, S., & Pautke, C. (2012). Bisphosphonate-related osteonecrosis of the jaws - characteristics, risk factors, clinical features, localization and impact on oncological treatment. *Journal of Cranio-Maxillo-Facial Surgery*, 40, 303–309.
- Otto, S., Tröltzsch, M., Jambrovic, V., Panya, S., Probst, F., Ristow, O., Ehrenfeld, M., & Pautke, C. (2015). Tooth extraction in patients receiving oral or intravenous bisphosphonate administration: A trigger for BRONJ development? *Journal of Cranio-Maxillofacial Surgery*, 43, 847–854.
- Owosho, A. A., Liang, S. T. Y., Sax, A. Z., Wu, K., Yom, S. H. K., Huryn, J. M., & Estilo, C. L. (2018). Medication-related osteonecrosis of the jaw: An update on the memorial sloan kettering cancer center experience and the role of premedication dental evaluation in prevention. *Oral Surgery, Oral Medicine, Oral Pathology, Oral Radiology*, 125, 440–445.
- Palmerini, E., Chawla, N. S., Ferrari, S., Sudan, M., Picci, P., Marchesi, E., Leopardi, M. P., Syed, I., Sankhala, K. K., Parthasarathy, P., Mendanha, W. E., Pierini, M., Paioli, A., & Chawla, S. P. (2017). Denosumab in advanced unresectable giant-cell tumour of bone (GCTB): For how long? *European Journal of Cancer*, 76, 118–124.
- Park, J.-H., Kwoen, M.-J., Lee, J.-R., Kim, K. S., Lee, H. J., Kim, J. W., & Gradual, L. H. (2021). Gradual, but not sudden, dose-dependent increase of ONJ risk with bisphosphonate exposure: A Nationwide cohort study in women with osteoporosis. *Front Endocrinol (Lausanne)*, 12, 1674.
- Patel, S., Choyee, S., Uyanne, J., Nguyen, A. L., Lee, P., Sedghizadeh, P. P., Kumar, S. K. S., Lytle, J., Shi, S., & le, A. D. (2012). Non-exposed bisphosphonate-related osteonecrosis of the jaw: A critical assessment of current definition, staging, and treatment guidelines. *Oral Diseases*, 18, 625–632.
- Peisker, A., Raschke, G. F., Fahmy, M. D., Guentsch, A., Roshanghias, K., König, K. C., & Schultze-Mosgau, S. (2017). Cross-sectional study of four serological bone turnover markers for the risk assessment of medication-related osteonecrosis of the jaw. *The Journal of Craniofacial Surgery*, 00, 1.
- Pignatelli, P., Podda, G. M., Pergolini, D., Rocchetti, F., Romeo, U., Tenore, G., & Gaglioti, D. (2021). A single reference center, 2 years retrospective study on the risk factors associated with anti-resorptive medication-related osteonecrosis of the jaws in osteoporotic and oncological patients. *Qeios*.
- Planchard, D., Popat, S., Kerr, K., Novello, S., Smit, E. F., Faivre-Finn, C., Mok, T. S., Reck, M., van Schil, P., Hellmann, M. D., Peters, S., & ESMO Guidelines Committee. (2018). Metastatic non-small cell lung cancer: ESMO clinical practice guidelines for diagnosis, treatment and follow-up. *Annals of Oncology*, 29, iv192–iv237.
- Raimondi, A., Simeone, N., Guzzo, M., Maniezzo, M., Collini, P., Morosi, C., Greco, F. G., Frezza, A. M., Casali, P. G., & Stacchiotti, S. (2020). Rechallenge of denosumab in jaw osteonecrosis of patients with unresectable giant cell tumour of bone: A case series analysis and literature review. *ESMO Open*, 5, e000663.
- Ravosa, M. J., Ning, J., Liu, Y., & Stack, M. S. (2011). Bisphosphonate effects on the behaviour of oral epithelial cells and oral fibroblasts. *Archives of Oral Biology*, 56, 491–498.
- Ripamonti, C. I., Maniezzo, M., Boldini, S., Pessi, M. A., Mariani, L., & Cislighi, E. (2012). Efficacy and tolerability of medical ozone gas insufflations in patients with osteonecrosis of the jaw treated with bisphosphonates-preliminary data medical ozone gas insufflation in treating ONJ lesions. *Journal of Bone Oncology*, 1, 81–87.
- Ripamonti, C. I., Maniezzo, M., Campa, T., Fagnoni, E., Brunelli, C., Saibene, G., Bareggi, C., Ascani, L., & Cislighi, E. (2009). Decreased occurrence of osteonecrosis of the jaw after implementation of dental preventive measures in solid tumour patients with bone metastases treated with bisphosphonates. The experience of

- the National Cancer Institute of Milan. *Annals of Oncology*, 20, 137–145.
- Ristow, O., Otto, S., Geiß, C., Kehl, V., Berger, M., Troeltzsch, M., Koerdts, S., Hohlweg-Majert, B., Freudlsperger, C., & Pautke, C. (2016). Comparison of auto-fluorescence and tetracycline fluorescence for guided bone surgery of medication-related osteonecrosis of the jaw: A randomized controlled feasibility study. *International Journal of Oral and Maxillofacial Surgery*, 46, 157–166.
- Ristow, O., & Pautke, C. (2014). Auto-fluorescence of the bone and its use for delineation of bone necrosis. *International Journal of Oral and Maxillofacial Surgery*, 43, 1391–1393.
- Ristow, O., Rückschloß, T., Moratin, J., Müller, M., Kühle, R., Dominik, H., Pilz, M., Shavlokhova, V., Otto, S., Hoffmann, J., & Freudlsperger, C. (2021). Wound closure and alveoplasty after preventive tooth extractions in patients with antiresorptive intake—a randomized pilot trial. *Oral Diseases*, 27, 532–546.
- Rossi, M., Gambino, A., Cabras, M., Alessio, M., & Fusco, V. (2021). Persistence, compliance, discontinuation rates and switch rates in denosumab and bisphosphonate treatment of bone metastases in cancer patients: Reasons of switch, osteonecrosis of the jaw (ONJ) and other critical points. *Support Care Cancer*, 29, 4185–4186.
- Rugarli, C. (2017). *Medici a metà: quel che manca nella relazione di cura*. Cortina.
- Ruggiero, S. L., Dodson, T. B., Aghaloo, T., Carlson, E. R., Ward, B. B., & Kademani, D. (2022). American Association of Oral and Maxillofacial Surgeons' position paper on medication-related osteonecrosis of the jaws—2022 update. *Journal of Oral and Maxillofacial Surgery*, 80, 920–943.
- Ruggiero, S. L., Dodson, T. B., Assael, L. A., Landesberg, R., Marx, R. E., & Mehrotra, B. (2009). American Association of Oral and Maxillofacial Surgeons position paper on bisphosphonate-related osteonecrosis of the jaw - 2009 update. *Australian Endodontic Journal*, 35, 119–130.
- Ruggiero, S. L., Dodson, T. B., Fantasia, J., Goodday, R., Aghaloo, T., Mehrotra, B., O'Ryan, F., & American Association of Oral and Maxillofacial Surgeons. (2014). American Association of Oral and Maxillofacial Surgeons Position Paper on medication-related osteonecrosis of the jaw—2014 update. *Journal of Oral and Maxillofacial Surgery*, 72, 1938–1956.
- Ruggiero, S. L., & Kohn, N. (2015). Disease stage and mode of therapy are important determinants of treatment outcomes for medication-related osteonecrosis of the jaw. *Journal of Oral and Maxillofacial Surgery*, 73, S94–S100.
- Şahin, O., Odaşası, O., Aliyev, T., & Tatar, B. (2019). Risk factors of medication-related osteonecrosis of the jaw: A retrospective study in a Turkish subpopulation. *Journal of the Korean Association of Oral and Maxillofacial Surgeons*, 45, 108–115.
- Saia, G., Blandamura, S., Bettini, G., Tronchet, A., Totola, A., Bedogni, G., Ferronato, G., Nocini, P. F., & Bedogni, A. (2010). Occurrence of bisphosphonate-related osteonecrosis of the jaw after surgical tooth extraction. *Journal of Oral and Maxillofacial Surgery*, 68, 797–804.
- Ministero Della Salute. (2014). *Raccomandazioni per la promozione della salute orale, la prevenzione delle patologie orali e la terapia odontostomatologica nei pazienti adulti con malattia neoplastica*.
- Saran, U., Gemini Piperni, S., & Chatterjee, S. (2014). Role of angiogenesis in bone repair. *Archives of Biochemistry and Biophysics*, 561, 109–117.
- Saussez, S., Javadian, R., Hupin, C., Magremanne, M., Chantrain, G., Loeb, I., & Decaestecker, C. (2009). Bisphosphonate-related osteonecrosis of the jaw and its associated risk factors: A Belgian case series. *Laryngoscope*, 119, 323–329.
- Scappaticci, F. A., Fehrenbacher, L., Cartwright, T., Hainsworth, J. D., Heim, W., Berlin, J., Kabbinavar, F., Novotny, W., Sarkar, S., & Hurwitz, H. (2005). Surgical wound healing complications in metastatic colorectal cancer patients treated with bevacizumab. *Journal of Surgical Oncology*, 91, 173–180.
- Schiødt, M., Otto, S., Fedele, S., Bedogni, A., Nicolatou-Galitis, O., Guggenberger, R., Herlofson, B. B., Ristow, O., & Kofod, T. (2019). Workshop of European task force on medication-related osteonecrosis of the jaw—Current challenges. *Oral Diseases*, 25, 1815–1821.
- Schiødt, M., Reibel, J., Oturai, P., & Kofod, T. (2014). Comparison of non-exposed and exposed bisphosphonate-induced osteonecrosis of the jaws: A retrospective analysis from the Copenhagen cohort and a proposal for an updated classification system. *Oral Surgery, Oral Medicine, Oral Pathology, Oral Radiology*, 117, 204–213.
- Schiødt, M., Vadhan-Raj, S., Chambers, M. S., Nicolatou-Galitis, O., Politis, C., Coropciuc, R., Fedele, S., Jandial, D., Zhang, J., Ma, H., & Saunders, D. P. (2018). A multicenter case registry study on medication-related osteonecrosis of the jaw in patients with advanced cancer. *Support Care Cancer*, 26, 1905–1915.
- Scoletta, M., Arduino, P. G., Dalmaso, P., Broccoletti, R., & Mozzati, M. (2010). Treatment outcomes in patients with bisphosphonate-related osteonecrosis of the jaws: A prospective study. *Oral Surgery, Oral Medicine, Oral Pathology, Oral Radiology, and Endodontics*, 110, 46–53.
- Smith, M. R., Saad, F., Coleman, R., Shore, N., Fizazi, K., Tombal, B., Miller, K., Sieber, P., Karsh, L., Damião, R., Tammela, T. L., Egerdie, B., van Poppel, H., Chin, J., Morote, J., Gómez-Veiga, F., Borkowski, T., Ye, Z., Kupic, A., ... Goessl, C. (2012). Denosumab and bone-metastasis-free survival in men with castration-resistant prostate cancer: Results of a phase 3, randomised, placebo-controlled trial. *Lancet*, 379, 39–46.
- Song, M., Alshaiikh, A., Kim, T., Kim, S., Dang, M., Mehrazarin, S., Shin, K. H., Kang, M., Park, N. H., & Kim, R. H. (2016). Preexisting periapical inflammatory condition exacerbates tooth extraction-induced bisphosphonate-related osteonecrosis of the jaw lesions in mice. *Journal of Endodontia*, 42, 1641–1646.
- Soundia, A., Hadaya, D., Esfandi, N., Gkouveris, I., Christensen, R., Dry, S. M., Bezouglaia, O., Pirihi, F., Nikitakis, N., Aghaloo, T., & Tetradis, S. (2018). Zoledronate impairs socket healing after extraction of teeth with experimental periodontitis. *Journal of Dental Research*, 97, 312–320.
- Srivastava, A., Nogueiras Gonzalez, G. M., Geng, Y., Won, A. M., Myers, J., Li, Y., & Chambers, M. S. (2021). Medication-related osteonecrosis of the jaw in patients treated concurrently with antiresorptive and antiangiogenic agents: Systematic review and meta-analysis. *Journal of Immunotherapy and Precision Oncology*, 4, 196–207.
- Stavropoulos, A., Bertl, K., Pietschmann, P., Pandis, N., Schiødt, M., & Klinge, B. (2018). The effect of antiresorptive drugs on implant therapy: Systematic review and meta-analysis. *Clinical Oral Implants Research*, 29(Suppl 1), 54–92.
- Stockmann, P., Vairaktaris, E., Wehrhan, F., Seiss, M., Schwarz, S., Spriewald, B., Neukam, F. W., & Nkenke, E. (2010). Osteotomy and primary wound closure in bisphosphonate-associated osteonecrosis of the jaw: A prospective clinical study with 12 months follow-up. *Support Care Cancer*, 18, 449–460.
- Suryani, I. R., Ahmadzai, I., Shujaat, S., Ma, H., & Jacobs, R. (2022). Non-antiresorptive drugs associated with the development of medication-related osteonecrosis of the jaw: A systematic review and meta-analysis. *Clinical Oral Investigations*, 26, 2269–2279.
- Tempesta, A., Capodiferro, S., Mauceri, R., Lauritano, D., Maiorano, E., Favia, G., & Limongelli, L. (2021). Peri-implantitis-like medication-related osteonecrosis of the jaw: Clinical considerations and histological evaluation with confocal laser scanning microscope. *Oral Diseases*, 28, 1603–1609.
- Tenore, G., Zimbalatti, A., Rocchetti, F., Graniero, F., Gaglioti, D., Mohsen, A., Caputo, M., Lollobrigida, M., Lamazza, L., de Biase, A., Barbato, E., & Romeo, U. (2020). Management of Medication-Related Osteonecrosis of the jaw (MRONJ) using leukocyte- and platelet-rich fibrin (L-PRF) and Photobiomodulation: A retrospective study. *Journal of Clinical Medicine*, 9, 3505.



- Terenzi, V., Cassoni, A., Coiante, E., Spadoni, D., Della Rocca, C., Pernazza, A., & Valentini, V. (2018). The possible contemporary presence of BRONJ and oral squamous cell carcinoma. *Oral Oncology*, 83, 160–161.
- Tocaciu, S., Breik, O., Lim, B., Angel, C., & Rutherford, N. (2017). Diagnostic dilemma between medication-related osteonecrosis and oral squamous cell carcinoma in a mandibular lytic lesion. *The British Journal of Oral & Maxillofacial Surgery*, 55, e53–e57.
- Tomasi, C., Wennström, J. L., & Berglundh, T. (2008). Longevity of teeth and implants - a systematic review. *Journal of Oral Rehabilitation*, 35, 23–32.
- Traboulsi-Garet, B., Jorba-García, A., Camps-Font, O., Alves, F. A., Figueiredo, R., & Valmaseda-Castellón, E. (2022). Is serum C-terminal telopeptide cross-link of type 1 collagen a reliable parameter for predicting the risk of medication-related osteonecrosis of the jaws? A systematic review and meta-analysis of diagnostic test accuracy. *Clinical Oral Investigations*, 26, 2371–2382.
- Troeltzsch, M. M. M., Cagna, D., Stähler, P., Probst, F., Kaepler, G., Troeltzsch, M., Ehrenfeld, M., & Otto, S. (2016). Clinical features of peri-implant medication-related osteonecrosis of the jaw: Is there an association to peri-implantitis? *Journal of Cranio-Maxillofacial Surgery*, 44, 1945–1951.
- Tsourd, E., Zillikens, M. C., Meier, C., Body, J. J., Gonzalez Rodriguez, E., Anastasilakis, A. D., Abrahamsen, B., McCloskey, E., Hofbauer, L. C., Guañabens, N., & Obermayer-Pietsch, B. (2021). Fracture risk and management of discontinuation of denosumab therapy: A systematic review and position statement by ECTS. *The Journal of Clinical Endocrinology & Metabolism*, 106, 264–281.
- Ueda, N., Aoki, K., Shimotsuji, H., Nakashima, C., Kawakami, M., Imai, Y., & Kirita, T. (2021). Oral risk factors associated with medication-related osteonecrosis of the jaw in patients with cancer. *Journal of Bone and Mineral Metabolism*, 39, 623–630.
- Van den Wyngaert, T., Claeys, T., Huizing, M. T., Vermorcken, J. B., & Fossion, E. (2009). Initial experience with conservative treatment in cancer patients with osteonecrosis of the jaw (ONJ) and predictors of outcome. *Annals of Oncology*, 20, 331–336.
- Vescovi, P., Campisi, G., Fusco, V., Mergoni, G., Manfredi, M., Merigo, E., Solazzo, L., Gabriele, M., Gaeta, G. M., Favia, G., Peluso, F., & Colella, G. (2011). Surgery-triggered and non surgery-triggered bisphosphonate-related osteonecrosis of the jaws (BRONJ): A retrospective analysis of 567 cases in an Italian multicenter study. *Oral Oncology*, 47, 191–194.
- Vescovi, P., Merigo, E., Meleti, M., & Manfredi, M. (2006). Bisphosphonate-associated osteonecrosis (BON) of the jaws: A possible treatment? *Journal of Oral and Maxillofacial Surgery*, 64, 1460–1462.
- Vescovi, P., Merigo, E., Meleti, M., Manfredi, M., Fornaini, C., Nammour, S., Mergoni, G., Sarraj, A., & Bagan, J. V. (2014). Conservative surgical management of stage I bisphosphonate-related osteonecrosis of the jaw. *International Journal of Dentistry*, 2014, 107690.
- Voss, P. J., Steybe, D., Poxleitner, P., Schmelzeisen, R., Munzenmayer, C., Fuellgraf, H., Stricker, A., & Semper-Hogg, W. (2018). Osteonecrosis of the jaw in patients transitioning from bisphosphonates to denosumab treatment for osteoporosis. *Odontology*, 106, 469–480.
- Watanabe, R. (2020). High incidence of antiresorptive agent-related osteonecrosis of the jaw in patients with rheumatoid arthritis. *Journal of Bone and Mineral Metabolism*, 38, 737–738.
- Watanabe, S., Nakajima, K., & Kinuya, S. (2019). ☆ symposium: Imaging modalities for drug-related osteonecrosis of the jaw (5), utility of bone scintigraphy and 18 F-FDG PET/CT in early detection and risk assessment of medication-related osteonecrosis of the jaw (secondary publication). *Japanese Dental Science Review*, 55, 76–79.
- Watts, N. B., Grbic, J. T., Binkley, N., Papapoulos, S., Butler, P. W., Yin, X., Tierney, A., Wagman, R. B., & McClung, M. (2019). Invasive oral procedures and events in postmenopausal women with osteoporosis treated with denosumab for up to 10 years. *The Journal of Clinical Endocrinology and Metabolism*, 104, 2443–2452.
- Wick, A., Bankosegger, P., Otto, S., Hohlweg-Majert, B., Steiner, T., Probst, F., Ristow, O., & Pautke, C. (2022). Risk factors associated with onset of medication-related osteonecrosis of the jaw in patients treated with denosumab. *Clinical Oral Investigations*, 26, 2839–2852.
- Wongratwanich, P., Shimabukuro, K., Konishi, M., Nagasaki, T., Ohtsuka, M., Sueti, Y., Nakamoto, T., Verdonshot, R. G., Kanesaki, T., Sutthiprapaporn, P., & Kakimoto, N. (2021). Do various imaging modalities provide potential early detection and diagnosis of medication-related osteonecrosis of the jaw? A review. *Dentomaxillofacial Radiology*, 50, 20200417.
- Wutzl, A., Biedermann, E., Wanschitz, F., Seemann, R., Klug, C., Baumann, A., Watzinger, F., Schicho, K., Ewers, R., & Millesi, G. (2008). Treatment results of bisphosphonate-related osteonecrosis of the jaws. *Head & Neck*, 30, 1224–1230.
- Yang, Y. L., Xiang, Z. J., Yang, J. H., Wang, W. J., & Xiang, R. L. (2019). The incidence and relative risk of adverse events in patients treated with bisphosphonate therapy for breast cancer: A systematic review and meta-analysis. *Therapeutic Advances in Medical Oncology*, 11, 1758835919855235.
- Yarom, N., Fedele, S., Lazarovici, T. S., & Elad, S. (2010). Is exposure of the jawbone mandatory for establishing the diagnosis of bisphosphonate-related osteonecrosis of the jaw? *Journal of Oral and Maxillofacial Surgery*, 68, 705.
- Yarom, N., Shapiro, C. L., Peterson, D. E., van Poznak, C. H., Bohlke, K., Ruggiero, S. L., Migliorati, C. A., Khan, A., Morrison, A., Anderson, H., Murphy, B. A., Alston-Johnson, D., Mendes, R. A., Beadle, B. M., Jensen, S. B., & Saunders, D. P. (2019). Medication-related osteonecrosis of the jaw: MASCC/ISOO/ASCO clinical practice guideline. *Journal of Clinical Oncology*, 37, 2270–2290.
- Zadik, Y., Ganor, Y., Rimon, O., Bersudski, E., & Meirovitz, A. (2021). Assessment of jaw osteonecrosis diagnostic criteria in cancer patients with a history of radiation therapy and exposure to bone-modifying agents. *Radiotherapy and Oncology*, 156, 275–280.

SUPPORTING INFORMATION

Additional supporting information can be found online in the Supporting Information section at the end of this article.

How to cite this article: Bedogni, A., Mauceri, R., Fusco, V., Bertoldo, F., Bettini, G., Di Fede, O., Lo Casto, A., Marchetti, C., Panzarella, V., Saia, G., Vescovi, P., & Campisi, G. (2024). Italian position paper (SIPMO-SICMF) on medication-related osteonecrosis of the jaw (MRONJ). *Oral Diseases*, 30, 3679–3709. <https://doi.org/10.1111/odi.14887>