

LETTER TO THE EDITOR

Spesolimab in patients with flare of generalized pustular psoriasis: A multicentre case-series

Dear Editor,

Generalized pustular psoriasis (GPP) is a rare, potentially life-threatening, chronic inflammatory disease characterized by acute flares of pustular eruptions that can be accompanied by systemic inflammation. GPP can be associated with chronic plaque psoriasis.^{1,2} There is a significant unmet need in the current treatment of GPP and its flares.³⁻⁵

Spesolimab is a novel, selective antibody that blocks the interleukin (IL)-36 receptor, a key component of the signalling pathway that plays a critical role in the pathophysiology of GPP.⁶ EFFISAYIL 1 trial showed that over half of the spesolimab-treated patients were free of pustules 1 week after receiving a single dose.⁷ Real-world data of the effectiveness and safety of spesolimab in patients with GPP flare are needed. We report the clinical data of a consecutive series of patients with a GPP flare ($n = 11$) who were treated with intravenous spesolimab 900 mg. All except one patient received 2 doses of spesolimab 1 week apart. GPP was diagnosed according to European Rare and Severe Psoriasis Expert Network (ERASPEN) criteria.⁸ The flare was defined as a Generalized Pustular Psoriasis Physician Global Assessment (GPPGA) total score of ≥ 3 , a GPPGA pustulation sub-score ≥ 2 and a $\geq 5\%$ of body surface area with erythema and pustules.⁹ Spesolimab has been administered as monotherapy. A specific wash out period from previous medications was not scheduled because the patients had an urgent need for treatment as the flare was resistant to therapies. The study was approved by the local Ethical Committee (Prog. 4030CESC, 15 November 2022). Descriptive demographic and clinical characteristics of the study population are reported in Table 1. Mean age was 58.9 ± 13.5 years and seven patients (63%) were females. GPP was persistent (i.e. characterized by flares lasting >3 months)^{2,8} in all patients, and the flare severity as assessed by GPP PASI (GPPASI) was 20.0 ± 6.5 , GPPGA 3.6 ± 0.5 and BSA $54.5 \pm 12.9\%$. Nine out of 11 (81.8%) of patients were affected by arterial hypertension, 5 by dyslipidaemia and 2 by Type 2 diabetes mellitus; 3 patients had psoriatic arthritis (2 affected by peripheral arthritis and 1 by dactylitis). Patients had already failed therapies with conventional systemic treatments [corticosteroids (100%), acitretin (81.8%), methotrexate (27.3%) and cyclosporine (27.3%)] and biologics (ixekizumab (27.3%), infliximab (18.2%) and single cases with adalimumab, secukinumab, tildrakizumab and risankizumab). Spesolimab showed rapid effectiveness in all the

TABLE 1 Descriptive characteristics of the study population.

Number of patients	N= 11
Age, mean \pm SD years	58.9 \pm 13.5
Gender, female, n (%)	7 (63.6)
Age of onset, mean \pm SD years	46.0 \pm 39.7
Body mass index, mean \pm SD (kg/m ²)	28.0 \pm 5.3
History of chronic plaque psoriasis	7 (63.6)
Current smoking habit	3 (27.3)
Psoriatic arthritis	3 (27.3)
Arterial hypertension	9 (81.8)
Dyslipidaemia	5 (45.5)
Type 2 diabetes mellitus	2 (18.2)
Disease course	
Relapsing (>1 episode)	10 (90.9)
Persistent (flares lasting >3 months)	11 (100)
Disease severity	
GPPASI, mean \pm SD	19.2 \pm 6.7
GPPGA, mean \pm SD	3.6 \pm 0.5
BSA, mean \pm SD	54.5 \pm 12.9
VAS itch, mean \pm SD	8.2 \pm 1.4
VAS pain, mean \pm SD	6.9 \pm 1.8
DLQI, mean \pm SD	21.7 \pm 6.4
Fever ($>38^\circ\text{C}$)	6 (54.5)
Leucocytosis (WBC $> 12 \times 10^9/\text{L}$)	5 (45.5)

Abbreviations: BSA, body surface area; DLQI, Dermatology Life Quality Index; GPPASI, Generalized Pustular Psoriasis Area and Severity Index; GPPGA, Generalized Pustular Psoriasis Physician Global Assessment; VAS, Visual Analogue Scale.

patients, with a mean reduction of GPPASI from 28.0 ± 6.5 to 11.5 ± 8.1 after 1 week ($p < 0.001$) and to 5.4 ± 4.4 after 4 weeks. GPPASI75 and GPPASI pustulation sub-score 0 were reached by 6 out of 11 (54%) patients at Week 1. In parallel, there was a marked improvement in the impact of disease on quality of life assessed through Dermatology Life Quality Index (DLQI), which reduced from 21.7 ± 6.4 to 14.3 ± 8.9 after 1 week ($p < 0.001$) to 7.0 ± 4.9 at Week 4 (Figure 1).⁹ As regards safety, a mild asthenia was reported by one patient and moderate worsening of itch in another. No changes in complete blood count, liver and kidney function tests were

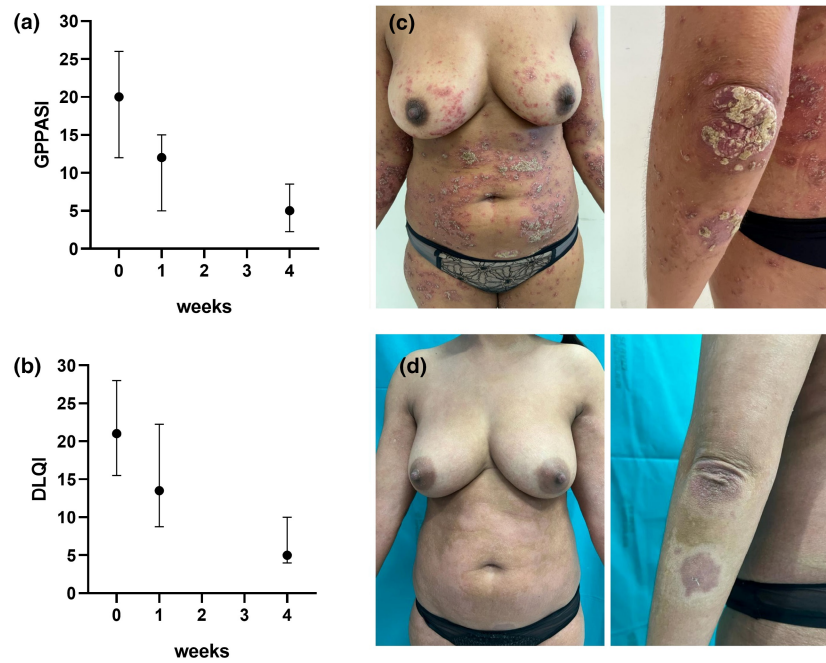


FIGURE 1 Reduction of disease severity assessed through Generalized Pustular Psoriasis PASI (GPPASI) (a) and Dermatology Life Quality Index (DLQI) (b) after 1 and 4 weeks of treatment with spesolimab 900 mg iv. Erythematous plaques covered by pustules/desquamation of the trunk and left arm in a 52-year-old woman of Moroccan origin, with a flare of GPP at baseline (c) and 8 days after the intravenous infusion of spesolimab 900 mg (d), showing a complete clinical remission (GPPASI score of 0).

identified. Study limitations include its open label nature, lack of a control group, and limited observation period. In conclusion, this study supports spesolimab can be effective in the flare of GPP which is not responsive to other conventional and biological systemic treatments, including IL-17 and IL-23 inhibitors and endorses its favourable tolerability and safety profile.

CONFLICT OF INTEREST STATEMENT

AVM reports consultancy/advisory boards disease-relevant honoraria from AbbVie, Boehringer-Ingelheim, Novartis, Pfizer, Sanofi and UCB. MV has been a consultant and/or speaker for Sanofi, Leo Pharma, Eli Lilly, Novartis, Janssen, AbbVie, Boehringer Ingelheim and UCB-Pharma. CDS has served as a speaker, consultant or advisory board member and has received honoraria from Abbvie, Almirall, Amgen, Boehringer Ingelheim, Eli Lilly, Leo Pharma, Janssen, Novartis and UCB Pharma. AD has received honoraria for participation in advisory boards, meetings, or as speaker for AbbVie, Janssen, Eli Lilly, UCB Pharma, Amgen, Almirall, Boehringer-Ingelheim. Boehringer-Ingelheim had no role in the design, analysis or interpretation of the results in this study. Boehringer-Ingelheim was given the opportunity to review the manuscript for medical and scientific accuracy as it relates to Boehringer-Ingelheim substances, as well as intellectual property considerations. FB, PG, AGR, AC, MZ, EP, MN, GP and GG have no disclosures.

DATA AVAILABILITY STATEMENT

The data that support the findings of this study are available from the corresponding author upon reasonable request.

ETHICS STATEMENT

The patients in this manuscript have given written informed consent to the publication of their case details.

F. Bellinato¹
 P. Gisondi¹
 A. Dattola²
 A. G. Richetta²
 A. Costanzo^{3,4}
 M. Valenti^{3,4}
 C. De Simone^{5,6}
 A. V. Marzano^{7,8}
 M. Zussino⁸
 E. Pezzolo⁹
 M. Nacca¹⁰
 G. Pellacani²
 G. Girolomoni¹

¹Section of Dermatology and Venereology, Department of Medicine, University of Verona, Verona, Italy

²Unit of Dermatology, Department of Internal Medicine and Medical Specialties, Sapienza University, Rome, Italy

³Dermatology Unit, IRCCS Humanitas Research Hospital, Rozzano, MI, Italy

⁴Dermatology Unit, Department of Biomedical Sciences, Humanitas University, Pieve Emanuele, Italy

⁵Dermatologia, Dipartimento Scienze Mediche e Chirurgiche, Fondazione Policlinico Universitario A. Gemelli IRCCS, Rome, Italy

⁶*Dermatologia, Dipartimento Universitario di Medicina e Chirurgia Traslazionale, Università Cattolica del Sacro Cuore, Rome, Italy*

⁷*Dermatology Unit, Fondazione IRCCS Ca' Granda Ospedale Maggiore Policlinico, Milan, Italy*

⁸*Department of Pathophysiology and Transplantation, Università degli Studi di Milano, Milan, Italy*

⁹*Dermatology Unit, Ospedale San Bortolo, Vicenza, Italy*

¹⁰*A.O.R.N. Sant'Anna e San Sebastiano Caserta, Caserta, Italy*

Correspondence

F Bellinato, Section of Dermatology and Venerology, Department of Medicine, University of Verona, Piazzale A. Stefani 1, Verona 37126, Italy.
Email: francesco.bellinato@univr.it

ORCID

F. Bellinato  <https://orcid.org/0000-0002-6163-6921>

P. Gisondi  <https://orcid.org/0000-0002-1777-9001>

A. Dattola  <https://orcid.org/0000-0001-9504-5882>

A. Costanzo  <https://orcid.org/0000-0001-9697-2557>


M. Valenti  <https://orcid.org/0000-0001-9140-9263>

C. De Simone  <https://orcid.org/0000-0002-0898-0045>

A. V. Marzano  <https://orcid.org/0000-0002-8160-4169>

E. Pezzolo  <https://orcid.org/0000-0003-0121-4812>

G. Pellacani  <https://orcid.org/0000-0002-7222-2951>

G. Girolomoni  <https://orcid.org/0000-0001-8548-0493>

REFERENCES

1. Genovese G, Moltrasio C, Cassano N, Maronese CA, Vena GA, Marzano AV. Pustular psoriasis: from pathophysiology to treatment. *Biomedicine*. 2021;9(12):1746.
2. Bellinato F, Gisondi P, Marzano AV, Piaserico S, De Simone C, Damiani G, et al. Characteristics of patients experiencing a flare of generalized pustular psoriasis: a multicenter observational study. *Vaccines (Basel)*. 2023;11(4):740.
3. Costanzo A, Bardazzi F, Simone C DE, Fabbrocini G, Foti C, Marzano AV, et al. Pustular psoriasis with a focus on generalized pustular psoriasis: classification and diagnostic criteria. An Italian Expert Consensus. *Ital J Dermatol Venerol*. 2022;157(6):489–96.
4. Krueger J, Puig L, Thaçi D. Treatment options and goals for patients with generalized pustular psoriasis. *Am J Clin Dermatol*. 2022;23(Suppl 1):51–64.
5. Zema CL, Valdecantos WC, Weiss J, Krebs B, Menter AM. Understanding flares in patients with generalized pustular psoriasis documented in US electronic health records. *JAMA Dermatol*. 2023;158(10):1142–8.
6. European Medicines Agency. Committee for Medicinal Products for Human Use (CHMP) summary of positive opinion: Spevigo (spesolimab). 2022. [Accessed 2022 Oct 27] https://www.ema.europa.eu/en/documents/smop-initial/chmp-summary-positive-opinion-spevigo_en.pdf
7. Bachelez H, Choon SE, Marrakchi S, Burden AD, Tsai T, Morita A, et al. Trial of spesolimab for generalized pustular psoriasis. *N Engl J Med*. 2021;385(26):2431–40.
8. Navarini AA, Burden AD, Capon F, Mrowietz U, Puig L, Köks S, et al. European consensus statement on phenotypes of pustular psoriasis. *J Eur Acad Dermatol Venereol*. 2017;31(11):1792–9.
9. Navarini AA, Prinz JC, Morita A, Tsai TF, Viguier MA, Li L, et al. Spesolimab improves patient-reported outcomes in patients with generalized pustular psoriasis: results from the Effisayil 1 study. *J Eur Acad Dermatol Venereol*. 2023;37(4):730–6.