





ORIGINAL ARTICLE

Clinical and pathology characterization of small nerve fiber neuro(n)opathy in cerebellar ataxia with neuropathy and vestibular areflexia syndrome

Matteo Tagliapietra¹ | Alex Incensi² | Moreno Ferrarini¹ | Nazarena Mesiano³ |
Alessandro Furia²  | Giovanni Rizzo²  | Rocco Liguori²  | Tiziana Cavallaro¹ |
Salvatore Monaco¹ | Gian Maria Fabrizi¹ | Vincenzo Donadio² 

¹Dipartimento di Neuroscienze, Biomedicina e Movimento, Università di Verona, Verona, Italy

²IRCCS Istituto delle Scienze Neurologiche di Bologna, UOC Clinica Neurologica, Bologna, Italy

³Dipartimento di Scienze Chirurgiche, Odontostomatologiche e Materno-infantili, UOC Otorinolaringoiatria, Verona, Italy

Correspondence

Matteo Tagliapietra, Dipartimento di Neuroscienze, Biomedicina e Movimento, Università di Verona, Piazzale L. Scuro 10, Verona 37134, Italy.
Email: matteo.tagliapietra@univr.it

Abstract

Background and purpose: Biallelic mutation/expansion of the gene *RFC1* has been described in association with a spectrum of manifestations ranging from isolated sensory neuro(n)opathy to a complex presentation as cerebellar ataxia with neuropathy and vestibular areflexia syndrome (CANVAS). Our aim was to define the frequency and characteristics of small fiber neuropathy (SFN) in *RFC1* disease at different stages.

Methods: *RFC1* cases were screened for SFN using the Neuropathic Pain Symptom Inventory and Composite Autonomic Symptom Score 31 questionnaires. Clinical data were retrospectively collected. If available, lower limb skin biopsy samples were evaluated for somatic epidermal and autonomic subepidermal structure innervation and compared to healthy controls (HCs).

Results: Forty patients, median age at onset 54 years (interquartile range [IQR] 49–61) and disease duration 10 years (IQR 6–16), were enrolled. Mild-to-moderate positive symptoms (median Neuropathic Pain Symptom Inventory score 12.1/50, IQR 5.5–22.3) and relevant autonomic disturbances (median Composite Autonomic Symptom Score 31 37.0/100, IQR 17.7–44.3) were frequently reported and showed scarce correlation with disease duration. A non-length-dependent impairment in nociception was evident in both clinical and paraclinical investigations. An extreme somatic denervation was observed in all patients at both proximal (fibers/mm, *RFC1* cases 0.0 vs. HCs 20.5, $p < 0.0001$) and distal sites (fibers/mm, *RFC1* cases 0.0 vs. HCs 13.1, $p < 0.0001$); instead only a slight decrease was observed in cholinergic and adrenergic innervation of autonomic structures.

Conclusions: *RFC1* disease is characterized by a severe and widespread somatic SFN. Skin denervation may potentially represent the earliest feature and drive towards the suspicion of this disorder.

KEYWORDS

dysautonomia, familial, humans, neuropathic pain, nociception, replication factor C, subunit 1, skin/pathology, small fiber neuropathy

This is an open access article under the terms of the [Creative Commons Attribution-NonCommercial-NoDerivs](https://creativecommons.org/licenses/by-nc-nd/4.0/) License, which permits use and distribution in any medium, provided the original work is properly cited, the use is non-commercial and no modifications or adaptations are made.

© 2023 The Authors. *European Journal of Neurology* published by John Wiley & Sons Ltd on behalf of European Academy of Neurology.

INTRODUCTION

Sensory neuronopathy with large fiber involvement has recently been recognized as the cardinal feature of cerebellar ataxia with neuronopathy and vestibular areflexia syndrome (CANVAS), a hereditary degenerative disease presenting with a complex ataxic disorder in middle age and associated with a biallelic mutation of the Replication Factor C subunit 1 (*RFC1*) gene [1]. The same genetic alteration has in turn been described as a frequent cause of apparently idiopathic sensory neuro(n)opathies in multiple studies [2–4]. In addition to sensory ataxia, symptoms and signs of small fiber neuropathy (SFN) such as thermal paresthesia, loss of pain sensation and dysautonomia were also noted since the first reports [5], but the pathological evidence of SFN is still limited to a small case series assessing skin biopsies in seven *RFC1*-positive patients [6], two advanced non-genetically confirmed CANVAS cases [7] and three studies assessing sural nerve biopsy specimens qualitatively [3, 5, 8].

Here the prevalence of SFN in CANVAS in a cohort of *RFC1*-positive patients is reported and its clinical and pathological features are characterized in relation to the disease course.

MATERIALS AND METHODS

The register of the local neurogenetic laboratory was reviewed for adult patients of both sexes with a documented biallelic (AAGGG)_n *RFC1* mutation expansion [3] and an available visit at our clinic in the last 24 months, irrespective of their clinical presentation. Patients with a concomitant risk factor for neuropathy or parkinsonism or who were unable to provide an informed consent according to the local Ethics Committee (CESC Verona-Rovigo and Comitato Etico Indipendente AUSL Bologna) were excluded. The study conforms with the World Medical Association Declaration of Helsinki.

Eligible patients were contacted to investigate for small fiber symptoms using the Italian version of the Neuropathic Pain Symptom Inventory (NPSI) [9] and the Composite Autonomic Symptom Score 31 (COMPASS-31) [10]. In short, the NPSI includes 10 items describing the presence and intensity of different aspects of positive symptoms, and two items assessing the frequency of spontaneous ongoing and paroxysmal pain. A total intensity score is provided ranging from 0 (none) to 50 points (worst), as well as a subdomain intensity score ranging from 0 to 10 points. COMPASS-31 includes 31 items investigating six subdomains (orthostatic intolerance, alterations of vasomotor, sudomotor, gastrointestinal, bladder and pupilomotor functions). A total weighted score is provided ranging from 0 (none) to 100 points (worst), as well as a percentage of the score obtained in each subdomain. In the literature, both conservative (30 points) and sensitive (10 points) thresholds have been described [11].

Clinical records at the last visit were reevaluated to assess the disease duration since the appearance of the first neurological disturbance apart from cough, presence/absence of chronic cough, signs and pattern of sensory impairment (light touch, pain and vibration sensation), dysfunction of cerebellar (limb and gait ataxia,

dysarthria, oculomotor disturbances) and vestibular systems (head impulse test) and disease severity according to the SPATAX functional disability scale, ranging from 0 (no disability) to 7 (severe disability/confined to bed). If available, previous neurophysiological studies obtained at our center comprising nerve conduction studies, laser evoked potentials (testing afferent A δ fiber integrity), sympathetic skin response (indirectly testing central and peripheral sympathetic cholinergic pathway integrity by means of the corresponding organ effector–sweat gland [SG]–response) and electrochemical skin conductance (indirectly testing post-ganglionic sympathetic cholinergic neuron integrity by means of the corresponding organ effector–SG–response) of the upper limbs (ULs) and lower limbs (LLs), as well as otoneurological advanced testing (videonystagmography, caloric testing, vestibular evoked myogenic potentials), were collected.

Skin biopsy

Available skin biopsies, previously obtained as a part of the diagnostic workup, were reevaluated. Skin biopsies had been obtained either as a 3 mm diameter skin punch biopsy from the distal leg (10 cm above the lateral malleolus) and proximal thigh (15 cm above the patella) under aseptic and anesthetic conditions, according to previous recommendations [12], or concomitant to a sural nerve biopsy procedure as a 3 × 15 mm full-thickness strip along the retromalleolar incision edge. According to previously published procedures [13], skin samples were immediately fixed in cold Zamboni's fixative and kept at 4°C overnight. Skin sections were obtained using a cryostat (HM550, Thermo Scientific, Waltham, MA, USA). Sections 50 μ m thick were obtained during the cryostat session. Twelve free-floating sections were incubated overnight with a panel of primary antibodies, including the pan-neuronal marker protein gene product 9.5 (rabbit PGP, 1:500, Abcam, Cambridge, UK, cat. no. ab108986; or mouse PGP, 1:750, Abcam, cat. no. ab72911), mouse collagen IV (CollIV, 1:800, Chemicon, Temecula, CA, USA, cat. no. MAB1910) and autonomic markers like rabbit tyrosine hydroxylase (TH, 1:1000, Novus Biologicals, Littleton, CO, USA, cat. no. NB300-109) to identify the noradrenergic fibers and rabbit vasoactive intestinal peptide (VIP, 1:1000, Incstar, Stillwater, MN, USA) co-localized in sudomotor cholinergic fibers [14]. Sections were then washed and secondary antibodies were labeled with mouse Alexa Fluor(R) 488 (1:400, Jackson ImmunoResearch, West Grove, PA, USA, cat. no. 715-545-150) and rabbit cyanine dye fluorophores 3.18 (1:800 double-stained with the remaining primary antibodies, Jackson ImmunoResearch, cat. no. 711-165-152) were added for overnight incubation. Sections were initially viewed under a Zeiss fluorescent microscope (model Axioskop 40, Jena, Germany). Autonomic innervation density was quantified using the previously described automated technique known as the 'unsharp mask filter' which creates a composite image by subtracting the background color in the out-of-focus image from the base image expressing the autonomic innervation staining (Image Pro Plus, Media Cybernetics, Rockville, MD,

USA). Target autonomic structures included skin vessels and muscle arrector pilorum (MAP) mainly expressing adrenergic nerve fibers and SGs expressing cholinergic fibers [13]. Due to the highly variable pattern of innervation in skin vessels, the autonomic innervation was only quantified in SGs and MAP by using the PGP signal, providing a stronger staining easier to quantify than the specific autonomic markers but which was correlated with the innervation quantified by the specific autonomic markers [13]. The autonomic innervation score was usually expressed as the percentage area of PGP staining in two or three different cholinergic or adrenergic target structures identified by ColIV staining for each skin site. Epidermal nerve fiber (ENF) density was calculated by considering a single ENF marked by PGP crossings of the dermal-epidermal junction stained by ColIV [15]. Healthy controls for skin biopsy findings were age- and sex-matched subjects recruited at the IRCCS Istituto delle Scienze Neurologiche di Bologna.

Microneurography

Recordings were made from the peroneal nerve with patients sat in an ambient temperature of 25°C and relative humidity of 30% in a semi-dark sound-proof room lying semi-reclining. Multi-unit recordings of efferent post-ganglionic muscle sympathetic nerve activity (MSNA) and skin sympathetic nerve activity (SSNA) with the corresponding organ effector responses (skin sympathetic response [SSR] and skin vasomotor response [SVR]) were recorded [16, 17].

MSNA was considered acceptable when it revealed spontaneous, pulse-synchronous bursts of neural activity that fulfilled the criteria previously described [16]. A burst of SSNA was considered if it had irregular frequency with variation in amplitude and duration not relating to heart beats; was followed at rest by changes in finger pulse amplitude (SVR) and/or skin electrical potential (SSR); and was elicited by various arousal stimuli, including surface electrical stimulation.

To measure SVR and SSR in the corresponding impaled skin fascicles, an infrared photoelectric transducer (model PPS, Grass Instruments, A-M Systems, Sequim, WA, USA) and Ag-AgCl surface electrodes (filter setting 0.2–100 Hz for both) were used, respectively. A search for SSNA and MSNA bursts was performed on the same day by changing skin nerve fascicles, which took a maximum of 70 min. The absence of sympathetic bursts was established after exploring at least three different corresponding nerve fascicles [18].

Statistical analysis

Numerical variables were assessed with histograms, Q–Q plots and Kolmogorov–Smirnov's test for normality. Descriptive statistics of clinical and demographic data are provided accordingly as median and interquartile range (IQR). Simple linear regression was used to estimate the correlation of age and disease duration with NPSI, COMPASS-31 scores and pathology results. Levene's test of

homogeneity of variances was followed by the Mann–Whitney *U* test or median test to compare demographic and pathology data between RFC1 cases and controls.

RESULTS

Forty out of 75 eligible RFC1-positive patients previously visited in our clinic were enrolled; median age at onset was 54 years (IQR 49–61) and disease duration 10 years (IQR 6–16). Reasons for exclusion were as follows: 24 patients lost to follow-up, five with other concomitant neuropathy (four diabetic neuropathy, one alcohol neuropathy), one with Parkinson disease, one for refusal and four for inability to provide consent. Sensory neuropathy was observed in all and sensory ataxia in all but one patient (98%), cerebellar disturbances were present in 28 (70%) but overt in 15 (38%), and vestibular impairment was observed in 19/38 (50%) on bedside testing and in 27/32 (84%) if including instrumental testing. Chronic cough was reported in 38 patients (95%). Ultimately, 22 patients (55%) could be classified as CANVAS (neuropathy, cerebellar ataxia and vestibular impairment), 11 (28%) as complex neuropathies (neuropathy and cerebellar or vestibular impairment) and seven (18%) as isolated neuropathies. Patients had a mild-to-moderate disease severity at last visit with median SPATAX score 3 points (IQR 2–3).

Patients exhibited a multi-modal sensory impairment which overall was more frequent at the LLs (impairment UL vs. LL: superficial tactile sensation 43% vs. 78%, vibration sensation 63% vs. 95%, nociception 83% vs. 86%). A length-dependent pattern was frequently observed on tactile sensation at the four limbs (UL 76%, LL 81%) and vibration sensation in the LLs (71%), but it was less common on vibration sensation in the ULs (56%) and on nociception at the four limbs (UL 21%, LL 27%). In nearly all patients presenting with a non-length-dependent pattern the loss of nociception was remarkably patchy; instead the loss of vibration sensation was often of a similar degree at all sites in the affected limb or occasionally showed a proximal-greater-than-distal involvement. Skin ulcerations were reported in a single patient at the feet.

Pain and autonomic questionnaires were obtained in all but two patients. The median total NPSI score was 12.1/50 (IQR 5.5–22.3) (Figure 1) and showed a weak correlation with disease duration ($R=0.38$, $p=0.020$), negligible with disease severity ($R=0.21$, $p=0.20$) and age at evaluation ($R=0.04$, $p=0.8$) (Figure S1). Paresthesiae were a universal disturbance and major constituents of positive symptoms (median intensity 5.0/10, IQR 3.0–7.0), irrespective of disease duration ($R=0.17$, $p=0.3$), disease severity ($R=0.02$, $p=0.9$) and age at evaluation ($R=-0.09$, $p=0.6$). Pain was reported less frequently, as a mild pressing or burning sensation (median intensity 1.5/10, IQR 0.0–3.5; and 0.0/10, IQR 0.0–5.0 respectively) or as paroxysmal bouts (median intensity 3.0/10, IQR 0.0–5.0). Evoked pain was usually mild (median intensity 1.5/10, IQR 0.0–3.3). Patients reported improvement with medication such as non-steroidal anti-inflammatory drugs (NSAIDs) ($n=7$), gabapentinoids ($n=8$), duloxetine ($n=4$), opioids ($n=1$), benzodiazepines ($n=1$) and

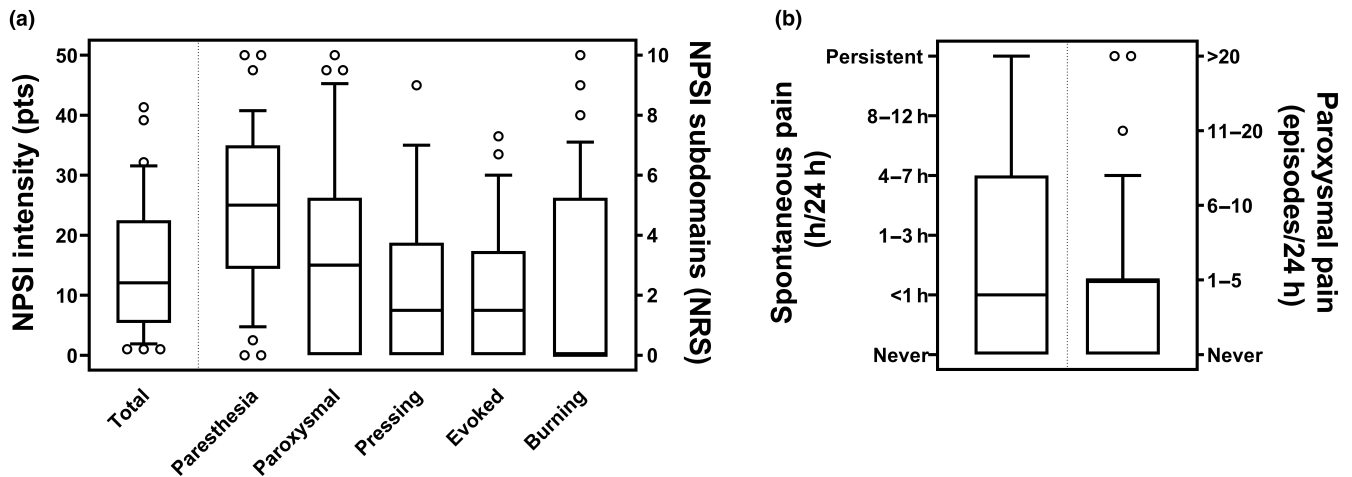


FIGURE 1 NPSI total and subdomain scores in RFC1 cases: positive symptoms are reported by most patients as a disturbance of mild-to-moderate intensity, with paresthesia being the most severe manifestation (a); occurrence of pain proper is often limited in duration and frequency (b). Box, first and third quartile; middle bar, median; upper/lower whisker, 10°–90° percentiles; dots, outliers; NPSI, Neuropathic Pain Symptom Inventory; NRS, Numerical Rating Scale.

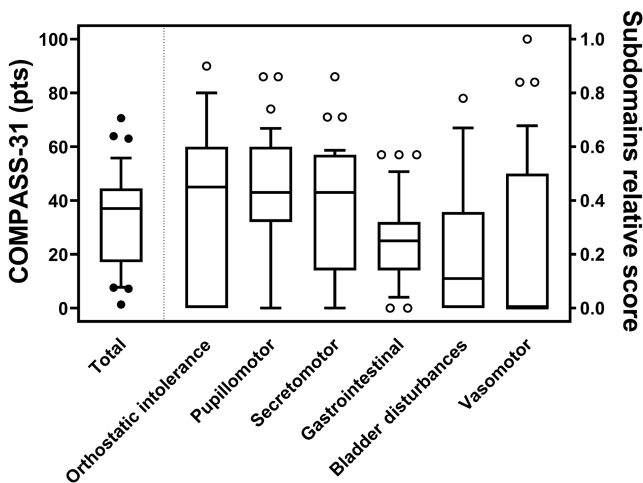


FIGURE 2 COMPASS-31 total and subdomain relative scores in RFC1 cases: box, first and third quartile; middle bar, median; upper/lower whisker, 10°–90° percentiles; dots, outliers; COMPASS-31, Composite Autonomic Symptom Score 31.

immunoglobulins ($n=1$), or by physical action such as movement ($n=9$), massage ($n=4$), rest ($n=1$), cooling ($n=2$). Others reported worsening with rest ($n=11$), cold exposure ($n=2$), physical exertion ($n=2$) or movement ($n=1$).

COMPASS-31 total score median 37.0/100 (IQR 17.7–44.3) (Figure 2), above the reported thresholds for autonomic disturbances in 33/38 (87%) or 22/38 (58%) if the sensitive cut-off at 10 points or the conservative cut-off at 30 points were to be adopted, showed a moderate association with disease severity ($R=0.42$, $p=0.009$), weak with disease duration ($R=0.34$, $p=0.039$) and negligible with age at evaluation ($R=0.1$, $p=0.6$) (Figure S1). There was a strong correlation with total NPSI score ($R=0.70$, $p<0.001$). The most severely affected domains appeared to be orthostatic intolerance (median 45%, IQR 0%–60%), pupillomotor function (median 43%, IQR 34%–60%) and secretomotor function (median 43%, IQR

14%–57%), whereas gastrointestinal, bladder and vasomotor disturbances were less reported. Reports of pupillomotor function were not affected by the presence of clinical oculomotor impairment on a post hoc analysis.

Skin biopsies were available from 30 patients and 19 healthy controls (Table I). The median interval between biopsy and questionnaire/clinical reevaluation was 1 year (IQR 0–3). A complete ENF denervation was observed at both proximal and distal sites in the majority of patients. In a few cases with very short disease duration ENFs were evident but they also showed a severe loss of ENFs both at proximal and distal sites. Analysis of arrector pili autonomic adrenergic innervation was obtained in at least one site in 26 patients and cholinergic innervation in 28; both were mildly decreased at the distal site, whereas adrenergic but not cholinergic innervation was mildly decreased at the proximal site (Figure 3). Correlation with age at biopsy and disease duration was weak or negligible in all instances in both groups (Figure S2).

Nerve conduction studies showed markedly decreased or absent sensory nerve action potential (SNAP) in all patients except for a single case with SNAPs still within normal values. Laser evoked potentials were frequently altered at both ULs and LLs. Sudomotor function was affected only in a fraction of patients as assessed on both SSR and electrochemical skin conductance, with LL prevalence (Table I).

Microneurographic recording of sympathetic activity was performed in five patients. In all patients MSNA and SSNA were recordable confirming a prevalently preserved post-ganglionic sympathetic outflow and mild autonomic impairment in RFC1-positive patients.

DISCUSSION

The study underlines the high prevalence of SFN in CANVAS. It also provides an extensive clinical, paraclinical and pathological

TABLE 1 Demographical, pathology and neurophysiology in RFC1 cases and controls.

	RFC1		Controls		p value	R
	Median (IQR)	n	Median (IQR)	n		
Age at biopsy (years)	65 (57–71)	30	57 (44–68)	19	0.5	n.a.
ENFD thigh (fibers/mm)	0.0 (0.0–0.4)	21	20.5 (15.8–21.8)	19	<0.0001	n.a.
ENFD leg (fibers/mm)	0.0 (0.0–0.4)	27	13.1 (11.1–15.1)	18	<0.0001	n.a.
Cholinergic innervation thigh (area%)	13.5 (10.8–16.5)	18	14.9 (13.5–16.7)	17	0.15	0.24
Cholinergic innervation leg (area%)	10.3 (9.6–12.4)	26	13.6 (12.7–14.2)	17	0.001	0.48
Adrenergic innervation thigh (area%)	14.6 (12.2–17.0)	21	17.3 (15.2–20.6)	17	0.018	0.38
Adrenergic innervation leg (area%)	9.6 (7.0–15.1)	17	15.3 (12.5–18.3)	10	0.018	0.45
SNAP amplitude ULs (μ V)	0 (0–3)	40	n.a.			
SNAP amplitude LLs (μ V)	0 (0–1)	40	n.a.			
LEP ULs (n, %)		15	n.a.			
Abnormal	3 (21%)					
Absent	8 (57%)					
LEP LLs (n, %)		15	n.a.			
Abnormal	4 (27%)					
Absent	9 (60%)					
SSR ULs (n, %)		14	n.a.			
Absent	2 (14%)					
SSR LLs (n, %)		14	n.a.			
Absent	3 (21%)					
ESC ULs (n, %)		24	n.a.			
Borderline	3 (13%)					
Abnormal	1 (4%)					
ESC LLs (n, %)		24	n.a.			
Borderline	9 (38%)					
Abnormal	4 (17%)					

Note: Significant values are presented in bold. Effect size is represented as R.

Abbreviations: ENFD, epidermal nerve fiber density; ESC, electrochemical skin conductance; IQR, interquartile range; LEP, laser evoked potential; LLs, lower limbs; SGNFD, sweat gland nerve fiber density; SNAP, sensory nerve action potential; SSR, sympathetic skin response; ULs, upper limbs.

characterization of SFN in a cohort of patients representative of the full range of symptoms, severity and disease duration, from early and mild cases with isolated sensory neuronopathy, to severe and late forms exhibiting a fully fledged CANVAS. Somatic SFN was a universal finding in our cohort, observed in every patient as a non-length-dependent skin denervation, extreme in severity in all except a few cases with very short disease duration. Similar findings were reported in two other preliminary studies on skin biopsies reporting a small cohort of patients [6, 7]. The fiber depletion observed on pathology strongly suggests that the process is at least concurrent with the large fiber neuronopathy which commonly brings attention to the disease. Intriguingly, the frequent chronic cough reported in this form and also antedating ataxic disturbances by decades has already been postulated as the result of vagal SFN [8, 19]. An illustrative case is that of the single patient presenting with a 3-year history

of neuropathic pain and paresthesia beginning in her fifth decade together with a long-established chronic cough, in the absence of ataxia. Nerve conduction studies showed SNAPs within normal values at the four limbs, albeit at the lower end of local normal values. Skin biopsy of the distal LL (obtained at another center, not included in the present study) instead confirmed a marked loss in somatic nerve fibers (ENF 2.0/mm).

The widespread involvement of ENFs in CANVAS is supportive of a neuropathy as the mechanism underlying this disorder [20], in agreement with the diffuse abnormality of nociception observed at the four limbs and at variance with the apparent length-dependent distribution observed on clinical evaluation of sensory impairments conveyed by sensory large nerve fibers (i.e., superficial tactile and vibration sensations), the latter a finding also reported in other previous works [2, 3, 5]. In routine practice, the almost total absence of

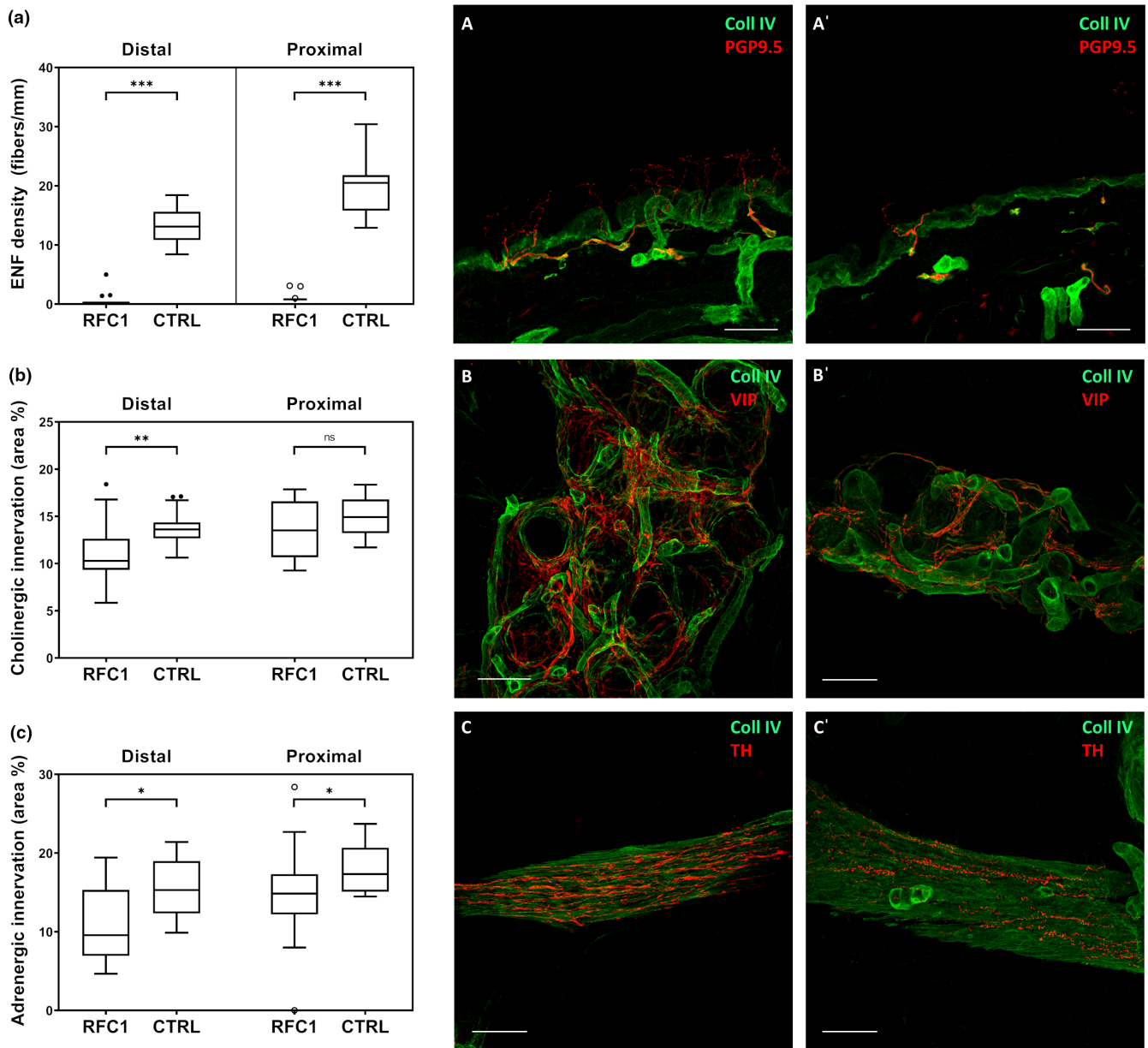


FIGURE 3 Somatic and autonomic skin innervation: boxplots of the differences between RFC1 cases and healthy controls in ENF density (a), sweat gland innervation (b) and adrenergic structure innervation (c) at distal and proximal sites. Side-by-side illustrative exempla of epidermal and autonomic innervation disclosed by a confocal microscope ($\times 20$) in a control subject (A, B and C) and an age-matched patient with CANVAS (A', B' and C'). Nerve fibers are marked in red whereas the collagen staining is shown in green. Bar $50\ \mu\text{m}$. ENF density is substantially depleted in RFC1 cases at both distal and proximal sites (a). Free-ending PGP 9.5 immunoreactive nociceptive fibers are evident in the epidermis of the control (a) but are scarcely represented in the RFC1 case (A'). The basement membrane separating epidermis from dermis is marked by collagen staining and indicated by an arrow. A mild decrease in sudomotor VIP-positive (b) and adrenergic TH-positive (c) nerve fibers is observed especially at the distal site. Sudomotor VIP-positive nerve fibers encircle sweat tubules in the healthy controls (B) whereas they are poorly represented with a deranged pattern of innervation in the RFC1 case (B'). Muscle arrector pilorum is rich in TH-positive adrenergic fibers running in a longitudinal and wavy pattern in the control subject (C) but a decreased density with abnormal pattern of innervation is observed in the RFC1 case (C'). Box, first and third quartile; middle bar, median; upper/lower whisker, higher/lower value up to 1.5 interquartile range; dots, outliers. Differences in group comparisons: *** $p < 0.001$; ** $p < 0.01$; * $p < 0.05$; ns $p \geq 0.05$. ENF, epithelial nerve fiber; VIP, vasointestinal peptide; TH, tyrosine hydroxylase.

epidermal fibers in proximal and distal skin sites and a non-length-dependent pattern of nociception abnormalities at clinical testing are distinct and may thus orient the clinician toward a neuronopathic disorder and to suspect RFC1 disease. Indeed, the observation of

this severe and widespread epidermal denervation pattern since early clinical phases seems highly characteristic in RFC1 disease.

Positive sensory symptoms are correspondingly frequent throughout the disease history and consist predominantly of limb

paresthesia and, to a lesser degree, spontaneous and evoked pain. These findings are consistent with our previous report [3], even though other studies reported lower figures [8, 21]. Anecdotal evidence on the effectiveness of medications was provided, with perceived relief from typical neuropathic pain medications but also from NSAIDs, which would require further investigation.

Similar to sensory symptoms, autonomic disturbances were frequently reported in our group and consisted predominantly of sicca syndrome, orthostatic intolerance and visual disturbances. Orthostatic hypotension has previously been reported as a frequent disturbance [22] and should be monitored as an additional risk factor for falls in these ataxic patients. Autonomic disturbances were present since early phases of the disease, partially correlating in severity with overall disease stage and independently of disease duration, the latter finding shared with a previous report [22]. Compared to sensory SFN, milder abnormalities of efferent autonomic cholinergic and adrenergic sympathetic innervation were observed on pathology and microneurographic recording. Similarly, dedicated neurophysiology testing of sudomotor functions disclosed fewer abnormalities than tests exploring A α afferent fibers.

At variance with the limited alterations of the sympathetic system observed in our patients, prior studies reported frequent abnormalities on functional cardiac autonomic tests [8, 23]. The cardiovascular reflex arc integrity relies both on visceral afferents and vagal parasympathetic efferents, and an impairment in either branch suffices for an altered response. Sympathetic function testing, on the other hand, explores predominantly the efferent neurons. Further studies are needed to ascertain whether this divergence in autonomic testing is the result of selective autonomic afferent fiber loss or a greater impairment of vagal autonomic fibers compared to sympathetic fibers.

Ultimately, this peculiar pattern of early widespread afferent small fiber involvement with relatively smaller sympathetic fiber loss seems to be characteristic and could aid in the identification of RFC1 cases amongst patients with predominant or isolated SFN.

Strengths and limitations

The adoption of inclusive selection criteria and the systematic proposal of the study irrespective of clinical presentation, together with the significant response rate, limited the possibility of a selection bias toward more severe forms in our sample. Our setting as a Peripheral Nerve Clinic is actually a possible explanation for the population instead being skewed toward earlier and more limited forms in comparison to the remaining literature.

As a retrospective study, it cannot be excluded that patients offered a skin biopsy procedure represented a subpopulation more likely to have SFN. However, this subgroup represents a significant majority of the enrolled patients and did not differ from the remaining sample regarding symptoms or disease severity, except for a mildly longer disease duration (Table S1). Moreover, concordant

results were observed in skin samples obtained in parallel to sural nerve biopsy, a procedure that is usually reserved to patients with large fiber neuropathy irrespective of the suspicion of SFN (Table S2).

CONCLUSIONS

RFC1 disease shows early and widespread loss of somatic afferent small fibers with minor involvement of autonomic efferent fibers, at least concurrent to the large fiber sensory neuropathy that often heralds other features of this multiform disease.

AUTHOR CONTRIBUTIONS

Matteo Tagliapietra: writing—original draft; formal analysis; investigation; methodology. Alex Incensi: investigation; methodology. Moreno Ferrarini: investigation; methodology. Nazarena Mesiano: investigation; methodology. Alessandro Furia: investigation. Giovanni Rizzo: investigation. Rocco Liguori: conceptualization; writing—review and editing. Tiziana Cavallaro: conceptualization; supervision. Salvatore Monaco: writing—review and editing. Gian Maria Fabrizi: writing—review and editing; conceptualization; supervision. Vincenzo Donadio: conceptualization; writing—review and editing; supervision; investigation.

ACKNOWLEDGEMENTS

The results of an interim analysis from this study were presented during the Twelfth Annual Meeting of the Italian Association for the Study of the Peripheral Nervous System (ASNP), 9–11 June 2022, Genova (*J Periph Nerv Sys* 2022; 27(S2): S3–S38).

CONFLICT OF INTEREST STATEMENT

None to declare.

DATA AVAILABILITY STATEMENT

The data that support the findings of this study are available on request from the corresponding author. The data are not publicly available due to privacy or ethical restrictions.

ORCID

Alessandro Furia  <https://orcid.org/0000-0002-7385-2744>

Giovanni Rizzo  <https://orcid.org/0000-0002-9718-2044>

Rocco Liguori  <https://orcid.org/0000-0002-1815-1013>

Vincenzo Donadio  <https://orcid.org/0000-0002-1290-7318>

REFERENCES

1. Cortese A, Simone R, Sullivan R, et al. Biallelic expansion of an intronic repeat in RFC1 is a common cause of late-onset ataxia. *Nat Genet.* 2019;51:649–658.
2. Currò R, Salvalaggio A, Tozza S, et al. RFC1 expansions are a common cause of idiopathic sensory neuropathy. *Brain.* 2021;144:1542–1550.
3. Tagliapietra M, Cardellini D, Ferrarini M, et al. RFC1 AAGGG repeat expansion masquerading as chronic idiopathic axonal polyneuropathy. *J Neurol.* 2021;268:4280–4290.

4. Beijer D, Dohrn MF, De Winter J, et al. RFC1 repeat expansions: a recurrent cause of sensory and autonomic neuropathy with cough and ataxia. *Eur J Neurol*. 2023;29:2156-2161.
5. Szmulewicz DJ, Waterston JA, Halmagyi GM, et al. Sensory neuropathy as part of the cerebellar ataxia neuropathy vestibular areflexia syndrome. *Neurology*. 2011;76:1903-1910.
6. Magy L, Chazelas P, Richard L, et al. Early diagnosis in cerebellar ataxia, neuropathy, vestibular areflexia syndrome (CANVAS) by focusing on major clinical clues: beyond ataxia and vestibular impairment. *Biomedicine*. 2022;10:2046.
7. Umeh CC, Polydefkis M, Chaudhry V, Zee DS. Sweat gland denervation in cerebellar ataxia with neuropathy and vestibular areflexia syndrome (CANVAS). *Mov Disord Clin Pract*. 2017;4:46-48.
8. Cortese A, Tozza S, Yau WY, et al. Cerebellar ataxia, neuropathy, vestibular areflexia syndrome due to RFC1 repeat expansion. *Brain*. 2020;143:480-490.
9. Padua L, Briani C, Jann S, et al. Validation of the Italian version of the neuropathic pain symptom inventory in peripheral nervous system diseases. *Neurol Sci*. 2009;30:99-106.
10. Pierangeli G, Turrini A, Giannini G, et al. Translation and linguistic validation of the composite autonomic symptom score COMPASS 31. *Neurol Sci*. 2015;36:1897-1902.
11. Treister R, O'Neil K, Downs HM, Oaklander AL. Validation of the composite autonomic symptom scale 31 (COMPASS-31) in patients with and without small fiber polyneuropathy. *Eur J Neurol*. 2015;22:1124-1130.
12. Donadio V, Cortelli P, Elam M, et al. Autonomic innervation in multiple system atrophy and pure autonomic failure. *J Neurol Neurosurg Psychiatry*. 2010;81:1327-1335.
13. Donadio V, Incensi A, Giannoccaro MP, et al. Peripheral autonomic neuropathy: diagnostic contribution of skin biopsy. *J Neuropathol Exp Neurol*. 2012;71:1000-1008.
14. Donadio V. Skin nerve α -synuclein deposits in Parkinson's disease and other synucleinopathies: a review. *Clin Auton Res*. 2019;29:577-585.
15. Provitera V, Gibbons CH, Wendelschafer-Crabb G, et al. A multi-center, multinational age- and gender-adjusted normative dataset for immunofluorescent intraepidermal nerve fiber density at the distal leg. *Eur J Neurol*. 2016;23:333-338.
16. Hainsworth R, Mark AL. *Cardiovascular Reflex Control in Health and Disease*. Saunders; 1993.
17. Donadio V, Cortelli P, Giannoccaro MP, et al. Muscle and skin sympathetic activities in Ross syndrome. *Clin Neurophysiol*. 2012;123:1639-1643.
18. Donadio V, Liguori R. Microneurographic recording from unmyelinated nerve fibers in neurological disorders: an update. *Clin Neurophysiol*. 2015;126:437-445.
19. Fargeot G, Humbert M, Echaniz-Laguna A. RFC1 gene intronic repeat expansion and unexplained chronic cough: a pathophysiological conundrum. *Respir Med*. 2021;80:100831.
20. Provitera V, Gibbons CH, Wendelschafer-Crabb G, et al. The role of skin biopsy in differentiating small-fiber neuropathy from ganglionopathy. *Eur J Neurol*. 2018;25:848-853.
21. Träschütz A, Cortese A, Reich S, et al. Natural history, phenotypic spectrum, and discriminative features of multisystemic RFC1-disease. *Neurology*. 2021;96:e1369-e1382.
22. Schmitt GDS, Lima FD, Matos PCAAP, et al. Dysautonomia in RFC1-related disorder: clinical and neurophysiological evaluation. *Clin Neurophysiol*. 2022;142:68-74.
23. Wu TY, Taylor JM, Kilfoyle DH, et al. Autonomic dysfunction is a major feature of cerebellar ataxia, neuropathy, vestibular areflexia "CANVAS" syndrome. *Brain*. 2014;137:2649-2656.

SUPPORTING INFORMATION

Additional supporting information can be found online in the Supporting Information section at the end of this article.

How to cite this article: Tagliapietra M, Incensi A, Ferrarini M, et al. Clinical and pathology characterization of small nerve fiber neuro(no)pathy in cerebellar ataxia with neuropathy and vestibular areflexia syndrome. *Eur J Neurol*. 2023;00:1-8. doi:[10.1111/ene.16018](https://doi.org/10.1111/ene.16018)