



# Endoscopic stapedotomy: safety and audiological results in 150 patients

Luca Bianconi<sup>1</sup> · Luca Gazzini<sup>1</sup> · Elisa Laura<sup>1</sup> · Stefano De Rossi<sup>1</sup> · Alessandro Conti<sup>1</sup> · Daniele Marchioni<sup>1</sup>

Received: 11 July 2019 / Accepted: 3 October 2019  
© Springer-Verlag GmbH Germany, part of Springer Nature 2019

## Abstract

**Objective** The most widely accepted treatment for otosclerosis is currently microscopic stapes surgery under either local or general anesthesia. The aim of the study is to describe the surgical steps in endoscopic stapes surgery and to evaluate the audiological and surgical outcomes.

**Materials and methods** All patients who underwent exclusive endoscopic stapes surgery or revision surgery for previous stapedotomy between November 2014 and September 2018 were enrolled in this study. Demographic data, surgical information, preoperative and postoperative pure tone averages and air bone gaps, intraoperative and postoperative complications and follow-up data were summarized and gathered in a database for further consideration and analysis.

**Results** In the period examined, 181 stapes surgical procedures were performed and out of these 150 met the inclusion criteria. There were no cases of major intraoperative complications. Sensorineural hearing loss was observed in one case. In one patient a gusher effect occurred during surgery. The postoperative air–bone gap improved significantly compared to the preoperative gap (8 vs 29 dB HL, respectively), and the mean air–bone gap closure was 20 dB HL. In 78.7% of cases, the observed postoperative air–bone gap was less than 10 dB HL and in 14% it was between 11 dB HL and 20 dB HL. An ABG closure lower than 20 dB HL was achieved in a total of 92.7% of patients.

**Conclusions** Endoscopic stapes surgery is a safe procedure with a low risk of peri- or postoperative complications and is a possible alternative to the traditional microscopic surgical procedure in the treatment of otosclerosis.

**Keywords** Stapes surgery · Endoscopic ear surgery · Endoscopic stapes surgery · Otosclerosis

## Introduction

Otosclerosis is a complex and progressive disease that mainly affects the stapes footplate, and in more advanced stages, the otic capsule of the temporal bone. The location and extent of the remodeled pathological bone lesions determine the symptomatology, which is most often a conductive or mixed hearing loss [1, 2]. The most widely accepted treatment for otosclerosis is microscopic stapes surgery [1–3]. This is a minimally invasive and safe procedure performed under general or local anesthesia, with favorable hearing outcome and a low risk of complications. Surgical corrections may include a small opening within the central footplate of

the stapes, which is referred to as a stapedotomy, or a total or partial removal of the stapes footplate which is known as stapedectomy [2, 3]. In recent years, advances in optics have revolutionized medical practice with the concept of minimally invasive surgical procedures. Recently, the endoscope has been introduced in otologic surgery and is gaining popularity worldwide as an exclusive or complementary tool in many otologic procedures. In stapes surgery, the good exposure and wide field of view provided by the endoscope improve visualization of middle ear anatomy resulting in a great advantage, in particular, in malformed ears or in revision procedures [4–7]. Since it is a recently introduced technique, only a few studies have been published about assisted or fully endoscopic stapes surgery. The aim of the study is to describe the surgical steps of endoscopic transcanal stapes surgery assessing the outcomes in terms of hearing gain and surgical complications.

✉ Luca Gazzini  
lucagazzini100@gmail.com

<sup>1</sup> Otolaryngology-Head and Neck Surgery Department,  
University Hospital of Verona, Piazzale Aristide Stefani, 1,  
37126 Verona, Italy

## Materials and methods

This is a retrospective review of patients who underwent stapes surgery using the stapedotomy technique at our tertiary referral center in the period between November 2014 and September 2018. The inclusion criteria were:

- patients diagnosed with otosclerosis, confirmed by an intraoperative stapes footplate fixation;
  - patients who underwent exclusive endoscopic stapedotomy or who required revision surgery;
  - at least 6 months of postoperative follow-up.
- Exclusion criteria were:
- patients with otosclerosis and coexisting ossicular chain anomalies;
  - patients with middle ear and retrocochlear pathology;
  - microscopic stapes surgery or combined microscopic–endoscopic stapes surgery;
  - lack of postoperative audiometric evaluation or clinical follow-up.

Demographic data and surgical information such as date of surgery, surgical reports, operated ear, operative times, types of endoscope and prosthesis used, ossicular chain anomalies encountered, intraoperative complications and their management were collected and gathered in a database. The procedures were categorized as primary stapes surgery or revision surgery after prior stapedotomy. Preoperative and postoperative pure-tone averages from air and bone conduction thresholds at frequencies of 0.5, 1, 2, and 3 kHz were calculated. The air–bone gap (ABG) was obtained by subtracting the bone conduction threshold (BCT) from the air conduction threshold (ACT) as recommended by the Hearing Committee of the American Academy of Otolaryngology—Head and Neck Surgery [8]. Complications during surgery and postoperative follow-up were also investigated and subdivided as follows:

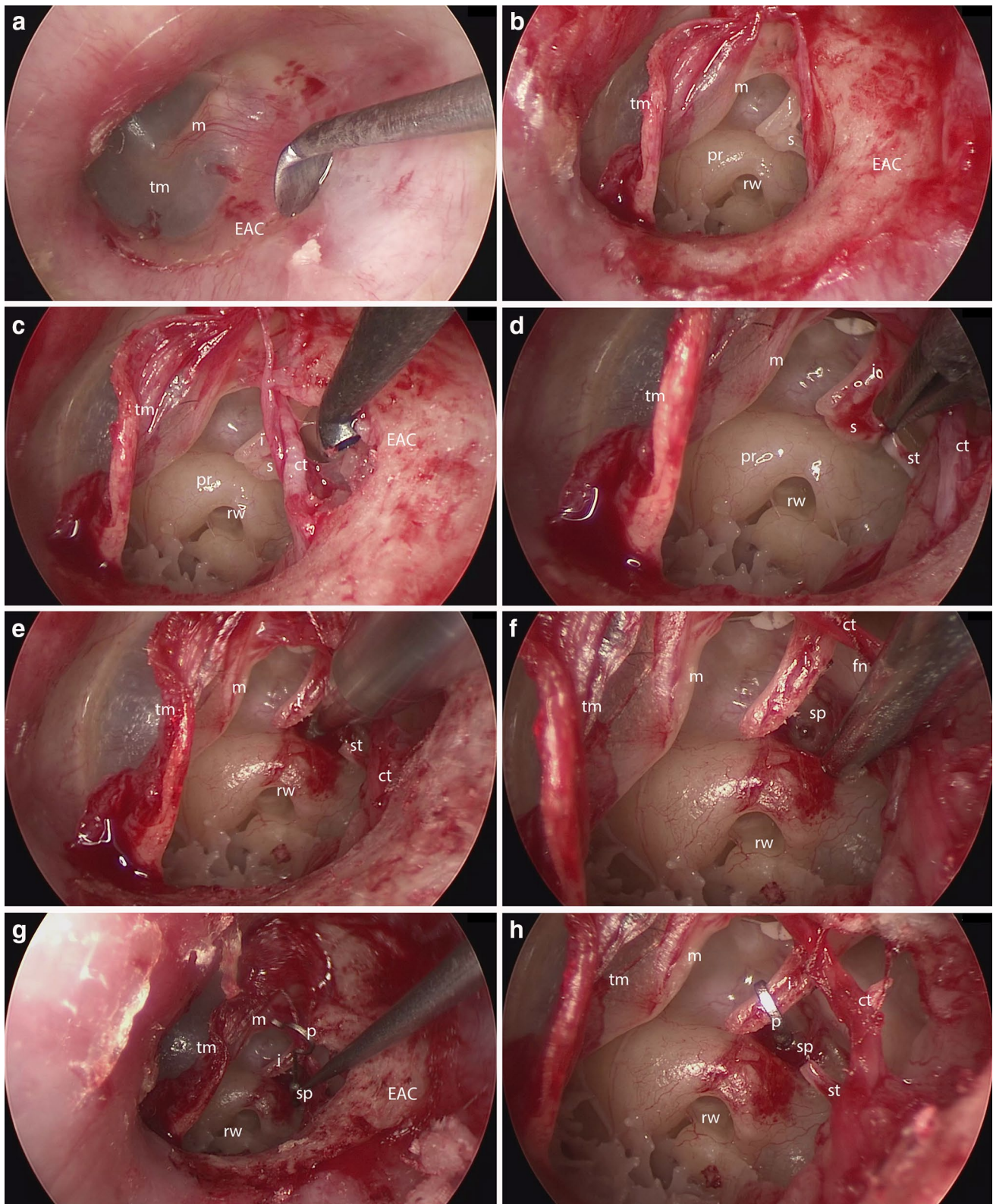
- intraoperative complications, including chorda tympani or facial nerve injury, sensorineural hearing loss, excessive bleeding, tympanic–ossicular system injuries and stapes gusher phenomenon;
- early postoperative complications, occurring within 1 month after surgery, including dizziness, facial nerve weakness, tympanic membrane perforation, infections and dysgeusia;
- late postoperative complications, observed after the first postoperative month, including prosthesis extrusion or dislocation and iatrogenic cholesteatoma.

## Preoperative assessment

In the preoperative evaluation, patients underwent an otoendoscopic examination using either a 0°, 3–4 mm diameter, 14–18 cm long scope (Karl Storz®, Tuttlingen, Germany) or a 45°, 3–4 mm diameter, 14–18 cm long scope (Karl Storz) to eliminate external ear canal pathology or other middle ear diseases. Pure tone audiometry, tympanometry and stapedia reflex tests were also performed in all patients. Indications for surgical management of otosclerosis included conductive or mixed hearing loss with > 30 dB preoperative ABG, the absence of a stapedia reflex or an on–off phenomenon, the presence of a type A tympanometry and normal endoscopic findings. A CT scan was routinely performed to exclude middle ear malformations and possible concurrent middle or inner ear diseases.

## Surgical procedure

- The procedures were performed under general anesthesia. The video equipment was placed in front of the surgeon. The instruments used were 0° and 45°, 3 mm-diameter and 14 cm-long endoscopes (Karl Storz). Occasionally, if the external auditory canal (EAC) was wide enough, a 4 mm-diameter, 18 cm-long endoscope was also used to ensure better image quality. Hemostasis was obtained by maintaining a hypotensive status (blood pressure < 90/60 mmHg) and placing epinephrine (1:2000)-soaked cottonoids in the EAC for 5 min.
- After adequate local anesthesia infiltration, using 0° endoscopic view, an ear canal skin incision was made from the 5 to the 12 o'clock position allowing elevation of the tympanomeatal flap (Fig. 1a, b).
- Occasionally, part of the scutum had to be curetted or drilled to increase exposure of the stapes, oval window, footplate, and facial nerve, to allow instrument access to the retrotympanic region of the middle ear and to facilitate the surgical maneuvers. In this case, it is important to visualize and take special care around the chorda tympani to avoid injuries to this structure (Fig. 1c).
- Exploration of the middle ear with 0° or 45° endoscopes allowed the anatomical landmarks to be checked. The facial nerve runs closely to the oval window and the footplate, so attention must be given to ensure that it is not displaced onto the footplate. Then stapes fixation was confirmed by testing ossicular chain mobility with a hook. After this step, the stapedia tendon and then the posterior stapes crura were cut with a scissors, the incudo-stapedia joint was disarticulated, and the stapes superstructure was carefully removed leaving the footplate in place (Fig. 1d).



**Fig. 1** **a** External auditory canal skin incision using a round scalpel. **b** Elevation of the tympanomeatal flap. **c** Visualization of the chorda tympani and incudo-stapedial joint after curettage of the posterior wall of the EAC. **d** Stapedial tendon section. **e, f** Platynotomy using a microdrill. **g, h** Positioning of the prosthesis and its fixation at the

handle of the malleus. *EAC* external auditory canal, *m* malleus, *tm* tympanic membrane, *rw* round window, *i* incus, *s* stapes, *ct* chorda tympani, *pr* promontory, *st* stapedial tendon, *sp* stapes plate, *p* prosthesis, *fn* facial nerve



- A microdrill was then used to perform a calibrated platinotomy using a 0.6 mm diameter diamond drill bur (Skeeter®, Otologic Drill System, Medtronic Xomed, Dublin, Ireland) at the medial or posterior portion of the footplate. A piston-type titanium prosthesis 0.6 × 4–6 mm (K-Piston stapes prosthesis, Kurz, Dusslingen, Germany) was then inserted and placed between the oval window and the incus (Fig. 1e–h). This surgical step represents the main difference between the microscopic and endoscopic technique: since the endoscopic technique is one-handed, precautions are required in the handling and positioning of the prosthesis. A suction tube with diameter smaller than the piston hook is used, adjusted to a power barely sufficient to pick up the prosthesis and insert it through the EAC in the middle ear, close to the platinotomy. It is very important to pick up the prosthesis from the uppermost portion of the hook to guide the piston toward the platinotomy. At this point, to perfect the positioning and proceed to inserting the piston in the platinotomy, a straight instrument (e.g., a Rosen's needle) is used. After correct positioning, a crimper is used to fix the prosthesis to the long process of the incus.
- After that, the malleus was carefully palpated to ensure the mobility of the ossicular chain through the prosthesis, checking the movement of the round window membrane after gently pushing on the handle of the malleus.
- The tympanomeatal flap was finally relocated into its original position, fixed in this position with Gelfoam (Pfizer, New York, USA) and treated with antibiotic otologic drops during the postoperative period.

### Postoperative follow-up

Regular healing of the tympanic membrane and the absence of early postoperative complications were confirmed in the first endoscopic examination, 30 days after surgery. A second evaluation was performed at 4 months follow-up to assess the hearing gain and to monitor the occurrence of any late complications.

The percentage recovery after the procedure was calculated and compared with the best possible recovery (complete closure of the ABG) using the following formula:

$$\left[ \frac{\text{Preoperative ABG} - \text{postoperative ABG}}{\text{preoperative ABG}} \right] \times 100.$$

In this way, complete closure of the ABG was considered to be 100% recovery, and at the opposite end complete lack of improvement was calculated as 0% recovery. Negative values correspond to worsening of the ABG after surgery.

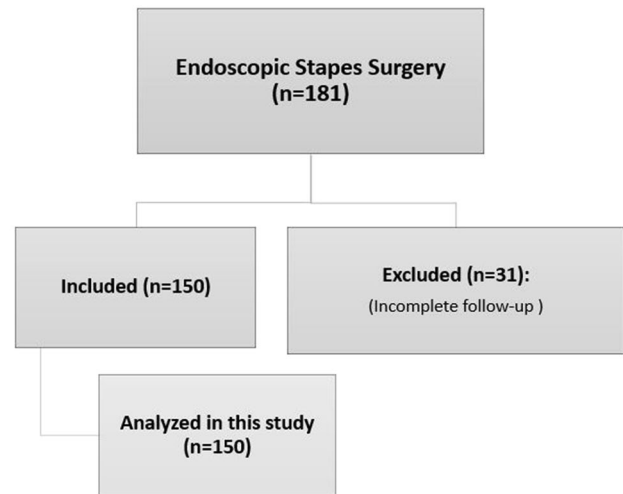


Fig. 2 Flowchart: patient included in the present study

### Ethical approval

All procedures performed in studies involving human participants were in accordance with the ethical standards of the institutional (Comitato etico delle province di Verona e Rovigo) and national research committee and with the 1964 Helsinki Declaration and its later amendments or comparable ethical standards.

### Informed consent

Informed consent was obtained from all individual participants included in the study.

### Statistical analysis

Student's *T* test was used to compare the pre- and postoperative means with normally distributed data, Mann–Whitney *U* test was used to compare independent samples among the same group of patients and *p* values < 0.05 were considered statistically significant.

### Results

Between November 2014 and September 2018, 181 patients underwent endoscopic stapedotomy in our Department of Otorhinolaryngology and Head and Neck Surgery. Out of these, 150 patients met the inclusion criteria and were enrolled in the present study (Fig. 2).

The mean age of the patients was 48.02 years (range 6–78 years), 84 (56.0%) were female and 66 (44.0%) were male.

**Table 1** Intraoperative, short-term or long-term postoperative complications in this study

Intraoperative complications	
Facial nerve lesion	0 (0%)
Vascular structure lesion	0 (0%)
Gusher	1 (0.7%)
Sensorineural hearing loss	1 (0.7%)
Ossicular chain dislocation	0 (0%)
Tympanic membrane lesion	6 (4.0%)
Chorda tympani lesion	1 (0.7%)
Short-term postoperative complications	
Persistent tympanic membrane perforation	1 (0.7%)
Infection	0 (0%)
Dizziness or vertigo	9 (6.0%)
Long-term postoperative complications	
Iatrogenic cholesteatoma	0 (0%)
Prosthesis dislocation	1 (0.7%)

**Table 2** Preoperative and postoperative audiological results

	Preoperative	Postoperative	<i>p</i> value <sup>o</sup>
Bone conduction, mean $\pm$ SD, dB HL <sup>a</sup>	26 $\pm$ 20	23 $\pm$ 22	0.99202
Air conduction, mean $\pm$ SD, dB HL <sup>a</sup>	55 $\pm$ 24	32 $\pm$ 24	<0.00001
Air–bone gap	29 $\pm$ 21	8 $\pm$ 21	<0.00001
Percentage recovery 73.85%			

<sup>a</sup>Average of the frequencies at 0.5, 1, 2, and 3 kHz<sup>o</sup>Calculated with Mann–Whitney *U* test

The disease was present on the right side in 90 (60.0%) patients and on the left side in 60 (40.0%).

Regarding the type of surgery, 128 out of 150 were undergoing a first procedure (85.3%) and 22 were revision surgeries (14.7%). The average length of the procedure was 34 min (range 18–76 min). Considering the intraoperative data, in 84 patients (56.0%) it was necessary to remove, using a curette, a part of the postero-superior bone frame of the posterior wall of the EAC, to expose the incus–stapes joint and the oval window to ease the following surgical steps. A total of 11 intraoperative complications (7.3%) were observed in our sample. The most frequent adverse event was a lesion of the tympanic membrane, involving six patients (4.0%) during tympanomeatal flap elevation.

In one case (0.7%), there was a modest gusher effect during the stapedotomy which resolved without further consequences.

Early complications (<30 days after surgery) were reported in 11 patients (7.4%) including 9 patients (6.0%) who complained of self-limited postoperative vertigo, and one patient (0.7%) with persistent tympanic membrane perforation, treated successfully with endoscopic type I tympanoplasty using a temporalis fascia graft. In one case a postoperative dysgeusia was reported, since a lesion to

the chorda tympani occurred during surgery. Revision surgery was needed in three patients (2.0%) because of progressive conductive hearing loss at long-term follow-up. Out of these, the prosthesis was dislocated in only one case, while in the other two patients, the prosthesis was blocked by scar tissue.

Complications classified as intraoperative, short-term or long-term postoperative are summarized in Table 1.

## Audiological results

Preoperative audiometric evaluation of the hearing threshold (dB HL) at frequencies of 0.5, 1, 2, and 3 kHz showed a bone conduction (mean  $\pm$  SD) of 26  $\pm$  20 dB HL, while the air conduction was 55  $\pm$  24 dB HL; therefore, the preoperative air–bone gap (ABG) was 29  $\pm$  21 dB HL. In the postoperative audiometric evaluation, performed between 3 and

6 months after surgery, air conduction was 32  $\pm$  24 dB HL and bone conduction was 23  $\pm$  22 dB HL. The corresponding ABG was 8  $\pm$  21 dB HL. Moreover, there was a statistically significant improvement in ABG closure of 20  $\pm$  22 dB HL between the preoperative and postoperative ABG (Mann–Whitney *U* test  $p$  < 0.00001) (Table 2).

In our study, the average recovery rate (calculated with the formula explained in “Materials and methods”) was 73.85% of the maximum expected recovery, and 127 patients (84.7%) achieved an ABG closure of > 50%. Moreover, an ABG lower than 10 dB HL was achieved in 118 patients (78.7%) and an ABG between 11 dB HL and 20 dB HL was obtained in 21 patients (14%), with an ABG closure lower than 20 dB HL in a total of 139 patients (92.7%). One case (0.7%) suffered sensorineural hearing loss (the patient had preoperative severe hearing loss of 60 dB HL for bone conduction and 107 dB HL for air conduction).

Audiological results were also compared between the first procedure and revision surgery. A postoperative ABG closure of 20  $\pm$  21 dB HL was obtained in the first surgery, while it was 21  $\pm$  26 dB HL in the revision surgery. The difference between the two groups was not statistically significant (Student’s *T* test,  $p$  = 0.22554).

## Discussion

Recently, the endoscope has been introduced as an exclusive tool to perform stapedotomy. In 2016, Hunter et al. reported the first multi-institutional endoscopic stapes surgery study in 65 subjects from four tertiary care otologic referral centers [4]. With a mean preoperative air–bone gap of 35.0 dB, they described a 5-month mean postoperative air–bone gap of 9.0 dB, a statistically significant improvement.

In our study, preoperative pure tone audiometry (PTA) for air conduction was 55 dB HL, whereas for bone conduction, it was 26 dB HL resulting in a preoperative ABG of 29. This result is consistent with the scientific literature with regard to microscopic stapes surgery [2, 9–22]. Following surgery, a significant improvement was obtained in all three parameters in our study, with a postoperative ABG of 8 dB HL. This is also consistent with the scientific literature. In our study, the percentage of procedures that obtained a good result (defined as an ABG of 10 or less) was 78.7%, whereas the percentage of procedures that obtained an acceptable result (ABG of 20 or less) was 92.7%. Both results are consistent with the literature [9, 11, 13, 15, 18–20, 23–26].

Another interesting aspect from our study is that no difference in outcome was noted between patients undergoing first surgery or revision surgery. This is in contrast to the current literature, in which results obtained with classic microscopic techniques have been shown to be worse during revision surgery [27–29]. However, one of the limitations of our study is represented by the absence of a control microscopic stapes surgery group, so this comparison is only based on data offered by current literature.

As far as duration of surgery is concerned, four studies [21, 23–25] reported a mean duration of surgery of 55 min versus 34 min obtained in our study. This dispels the criticism that might arise with regard to the increasing duration of surgery when considering a one-handed technique, especially about positioning of the prosthesis and management of bleeding. In fact, the mean duration of stapes surgery in our study turned out to be among the shortest in the literature, probably due to the lack of need for EAC calibration when compared to traditional procedures. Anyway, this does not imply that a shorter surgical time is to be expected in all cases for endoscopic stapes surgery: a possible bias of this comparison may lie in the fact that all procedures at our institution were carried out by a single senior ear surgeon, particularly experienced in endoscopic ear surgery, and not by a group of surgeons.

As far as the risk of sensorineural hearing loss is concerned, it was observed in only 0.7% of cases in our series, a result close to that reported in publications on

microscopic stapes surgery [2, 10–20, 22, 25, 30, 31], thus challenging the heating-related injury assumed in some articles [32]. Further publications [33] have clearly demonstrated that the use of low-intensity LED lighting during endoscopic ear surgery is completely safe, and does not affect the clear visualization of middle ear structures. In support of this, other publications [34] have pointed out that a 4 mm LED scope, set at the lighting intensity generally used during endoscopic ear surgery, does not cause an increase in middle ear temperature above 31 °C. When considering the manipulation of the chorda tympani needed to gain an adequate view of the oval window and stapes during drilling of the posterior wall of the EAC, under microscopic view this is required in 100% of cases [14, 20, 23–25, 31], whereas it was needed in 56% of our series. To support this, dysgeusia is reported in 8.11% of cases in microscopic stapes surgery [2, 13, 14, 16, 20, 23–25, 30, 31], against 2.0% reported in this study.

The lack of a tridimensional view during endoscopic ear surgery is one of the main criticisms against it. Nevertheless, this is very rarely perceived to be a problem by endoscopic ear surgeons adequately trained in the technique and can easily be overcome due to the different angles offered by the endoscopic view. On the other hand, the magnification allowed by the endoscope does not negatively affect the manipulation of important structures and tissues and can represent a useful feature in cases of anatomical alteration such as ossicular chain malformations and/or facial nerve dehiscence [35]. Coherently with this remark, no lesion of the ossicular chain or facial nerve injury has been reported in our series.

With respect to the lack of improvement or worsening of the ABG, this issue can be attributed to various causes (prosthesis dislocation, erosion of the long process of the incus, short prosthesis or loosening of its attachment to the incus, granuloma formation, fixation of the stapes footplate due to reossification) [19], often leading to revision surgery. In our series, 2.0% of cases required further surgery, consistently with literature [9, 10, 12, 16, 18, 30]. This confirms the adequate prosthesis positioning allowed by the endoscopic one-handed technique. Of course, this technique presents some disadvantages, especially related to inadequate EAC dimensions and the possibility of bleeding during opening of the tympanomeatal flap, which result in increased difficulty during surgery and require adequate preoperative evaluation of the patient as well as active collaboration by the anesthesiologist during surgery. In particular, our study shows that one of the most frequent intraoperative complications is the adventitious laceration of the tympanic membrane. In cases in which such injury occurred, the tympanic membrane was markedly thinned and therefore a lesion during the tympanomeatal flap elevation represented a possible

complication. Moreover, two out of six lesions happened during revision surgery, characterized by frail tympanic membrane due to the scars resulting from previous surgery. In all cases, the tympanic membrane lesion was small and it was promptly repaired with an underlay technique during surgery, and the stapes surgery was regularly finalized. Nonetheless, it is possible to have difficulties in the management of the tympanomeatal flap using one hand even for an experienced endoscopic ear surgeon, especially in case of bleeding.

Another step that is considered as particularly difficult is the positioning and crimping of the prosthesis using one hand during endoscopy: these operations, if carried out by inexperienced hands, can potentially cause a dislocation of the incus. In our case series, no intraoperative complications regarding these steps occurred, but our opinion is that endoscopic stapedotomy should be considered as an operation to be performed at the end of an appropriate endoscopic skill training, after numerous exclusive endoscopic procedures such as type I tympanoplasty, middle ear cholesteatoma removal, etc. In fact, in our opinion, microscopic stapedotomy should be preferred in case the endoscopic ear surgery training is insufficient, the microscopic technique being a standardized procedure with safe and well-established results. Ultimately, in the case of a gusher identified during endoscopic surgery, a microscopic approach is advised to adequately address the pathology). In the author's opinion, in fact, endoscopic stapes surgery has to be considered as a possible alternative to microscopic stapes surgery only in institutions with a strong expertise in endoscopic ear surgery. In all other cases, microscopic stapes surgery still represents the gold standard technique for the surgical treatment of otosclerosis.

## Conclusions

Endoscopic stapes surgery in our case series revealed itself to be a safe procedure in terms of complications and outcomes. Audiological results are consistent with the scientific literature on microscopic stapedotomy. Thanks to its better visualization of middle ear structures, the use of the endoscope can be advantageous in revision surgery and when a malformation of the ossicular chain or facial nerve dislocation is present. In conclusion, endoscopic stapes surgery can be considered as an alternative to microscopic procedures for surgeons with appropriate endoscopic ear surgery skills, even though the microscopic technique still embodies the gold standard surgical treatment for otosclerosis.

**Funding** This study was not funded.

## Compliance with ethical standards

**Conflict of interest** The present authors have no financial relationships to disclose.

**Ethical approval** All procedures performed in studies involving human participants were in accordance with the ethical standards of the institutional and national research committee and with the 1964 Helsinki Declaration and its later amendments or comparable ethical standards.

**Informed consent** Informed consent was obtained from all individual participants included in the study. All of the authors have read and approved the manuscript.

## References

- Batson L, Rizzolo D (2017) Otosclerosis: an update on diagnosis and treatment. *JAAPA*. 30(2):17–22
- Dhooge I, Desmedt S, Maly T, Loose D, Van Hoecke H (2018) Long-term hearing results of stapedotomy: analysis of factors affecting outcome. *Eur Arch Otorhinolaryngol*. 275(5):1111–1119
- Alzhrani F, Mokhatrish MM, Al-Momani MO, Alshehri H, Hagr A, Garadat SN (2017) Effectiveness of stapedotomy in improving hearing sensitivity for 53 otosclerotic patients: Retrospective review. *Ann Saudi Med*. 37(1):49–55
- Hunter JB, O'Connell BP, Rivas A (2017) Transcanal endoscopic stapedotomy. Operative techniques. *Otolaryngol Head Neck Surg* 28(1):44–49
- Dursun E, Özgür A, Terzi S, Oğurlu M, Coşkun ZO, Demirci M (2016) Endoscopic transcanal stapes surgery: our technique and outcomes. *Kulak Burun Bogaz Ihtis Derg*. 26(4):201–206
- Hunter JB, Rivas A (2016) Outcomes following endoscopic stapes surgery. *Otolaryngol Clin N Am* 49:1215–1225
- Özdek A, Bayir Ö, Keseroğlu K et al (2016) Fully endoscopic stapes surgery: preliminary results. *Ann Otolaryngol Rhinol* 3(1):1085
- Committee on Hearing and Equilibrium guidelines for the evaluation of results of treatment of conductive hearing loss (1995) American Academy of Otolaryngology-Head and Neck Surgery Foundation, Inc. *Otolaryngol Head Neck Surg* 113(3):186–187
- Sproat R, Yiannakis C, Iyer A (2017) Endoscopic stapes surgery: a comparison with microscopic surgery. *Otol Neurotol*. 38(5):662–666
- Vincent R, Sperling NM, Oates J, Jindal M (2006) Surgical findings and long-term hearing results in 3,050 stapedotomies for primary otosclerosis: a prospective study with the otology-neurology database. *Otol Neurotol* 27(8 Suppl 2):S25–S47
- Kisilevsky VE, Dutt SN, Bailie NA, Halik JJ (2009) Hearing results of 1145 stapedotomies evaluated with Amsterdam hearing evaluation plots. *J Laryngol Otol* 123(7):730–736
- Justicz N, Strickland KF, Motamedi KK, Mattox DE (2017) Review of a single surgeon's stapedotomy cases with a nickel titanium prosthesis over a 14-year period. *Acta Otolaryngol* 137(4):442–446
- Strömbäck K, Lundman L, Bjorsne A, Grendin J, Stjernquist-Desatnik A, Dahlin-Redfors Y (2017) Stapes surgery in Sweden: evaluation of a national-based register. *Eur Arch Otorhinolaryngol* 274(6):2421–2427
- Parida PK, Kalaiarasi R, Gopalakrishnan S (2016) Diode laser stapedotomy vs conventional stapedotomy in otosclerosis: a double-blinded randomized clinical trial. *Otolaryngol Head Neck Surg* 154(6):1099–1105

15. Parrilla C, Gall J, Fetoni AR, Rigante M, Paludetti G (2008) Erbium: yttrium–aluminium–garnet laser stapedotomy—a safe technique. *Otolaryngol Head Neck Surg* 138(4):507–512
16. Aarnisalo AA, Vasama JP, Hopsu E, Ramsay H (2003) Long-term hearing results after stapes surgery: a 20-year follow-up. *Otol Neurotol* 24(4):567–571
17. Marchese MR, Cianfrone F, Passali GC, Paludetti G (2007) Hearing results after stapedotomy: role of the prosthesis diameter. *Audiol Neurootol* 12(4):221–225
18. Murfee J, O’Connell B, Haynes D, Rivas A, Dedmon M, Bennett M (2018) Outcomes of stapedotomy with heat-crimped prostheses. *Otol Neurotol* 39(10):1235–1240
19. Vincent R, Rovers M, Zingade N et al (2010) Revision stapedotomy: operative findings and hearing results. A prospective study of 652 cases from Otolaryngology-Neurotology Database. *Otol Neurotol* 31(6):875–882
20. Moneir W, Abd El-Fattah AM, Mahmoud E, Elshaer M (2018) Endoscopic stapedotomy: merits and demerits. *J Otol* 13(3):97–100
21. Surmelioglu O, Ozdemir S, Tarkan O, Tuncer U, Dagkiran M, Cetik F (2017) Endoscopic versus microscopic stapes surgery. *Auris Nasus Larynx* 44(3):253–257
22. Quaranta N, Besozzi G, Fallacara RA, Quaranta A (2005) Air and bone conduction change after stapedotomy and partial stapedectomy for otosclerosis. *Otolaryngol Head Neck Surg* 133(1):116–120
23. Iannella G, Magliulo G (2016) Endoscopic versus microscopic approach in stapes surgery: are operative times and learning curve important for making the choice? *Otol Neurotol* 37(9):1350–1357
24. Kojima H, Komori M, Chikazawa S et al (2014) Comparison between endoscopic and microscopic stapes surgery. *Laryngoscope* 124(1):266–271
25. Daneshi A, Jahandideh H (2016) Totally endoscopic stapes surgery without packing: novel technique bringing most comfort to the patients. *Eur Arch Otorhinolaryngol* 273(3):631–634
26. Adedeji TO, Indorewala S, Indorewala A, Nemade G (2016) Stapedotomy and its effect on hearing—our experience with 54 cases. *Afr Health Sci* 16(1):276–281
27. Somers T, Govaerts P, de Varebeke SJ, Offeciers E (1997) Revision stapes surgery. *J Laryngol Otol* 111(3):233–239
28. Farris J, Sutherland A (1991) Revision stapes surgery. *Laryngoscope* 101(11):1155–1161
29. Gros A, Vatovec J, Zargi M, Jenko K (2005) Success rate in revision stapes surgery for otosclerosis. *Otol Neurotol* 26(6):1143–1148
30. Sedwick JD, Loudon CL, Shelton C (1997) Stapedectomy vs stapedotomy. Do you really need a laser? *Arch Otolaryngol Head Neck Surg* 123(2):177–180
31. Mahfudz Z, Lokman S (2004) Outcome of stapes surgery for otosclerosis. *Med J Malay* 59(2):171–176
32. Dundar R, Bulut H, Güler OK et al (2015) Oval window temperature changes in an endoscopic stapedectomy. *J Craniofac Surg* 26(5):1704–1708
33. Marchioni D, Rubini A, Gazzini L et al (2018) Complications in endoscopic ear surgery. *Otol Neurotol* 39(8):1012–1017
34. Ito T, Kubota T, Takagi A et al (2016) Safety of heat generated by endoscope light sources in simulated transcanal endoscopic ear surgery. *Auris Nasus Larynx* 43(5):501–506
35. Marchioni D, Soloperto D, Villari D et al (2016) Stapes malformations: the contribute of the endoscopy for diagnosis and surgery. *Eur Arch Otorhinolaryngol* 273(7):1723–1729

**Publisher’s Note** Springer Nature remains neutral with regard to jurisdictional claims in published maps and institutional affiliations.