



## How much and for how long does the neonatal myocardium suffer from mild perinatal asphyxia?

C Cavalli, RM Dorizzi, L Lanzoni, M Caputo & P Biban

To cite this article: C Cavalli, RM Dorizzi, L Lanzoni, M Caputo & P Biban (2005) How much and for how long does the neonatal myocardium suffer from mild perinatal asphyxia?, The Journal of Maternal-Fetal & Neonatal Medicine, 17:1, 85-86, DOI: [10.1080/14767050400013438](https://doi.org/10.1080/14767050400013438)

To link to this article: <https://doi.org/10.1080/14767050400013438>



Published online: 07 Jul 2009.



Submit your article to this journal [↗](#)



Article views: 46



View related articles [↗](#)



Citing articles: 1 View citing articles [↗](#)

## CASE REPORT

# How much and for how long does the neonatal myocardium suffer from mild perinatal asphyxia?

C. CAVALLI<sup>1</sup>, R. M. DORIZZI<sup>2</sup>, L. LANZONI<sup>3</sup>, M. CAPUTO<sup>3</sup>, & P. BIBAN<sup>1</sup>

<sup>1</sup>*Pediatric and Neonatal Intensive Care Unit, Division of Pediatrics, Hospital of Verona, Parma, Italy,* <sup>2</sup>*Clinical Chemistry and Hematology Laboratory, Hospital of Verona, Parma, Italy,* and <sup>3</sup>*Pediatric Cardiology Unit, Department of Cardiology, Hospital of Verona, Parma, Italy*

(Received 14 November 2003; revised 20 April 2004; accepted 21 April 2004)

### Abstract

Cardiac troponins can be useful in monitoring cardiac injury following perinatal distress. We report here an increase of cardiac troponin I (cTnI) to 2.84  $\mu\text{g/l}$  at 3 weeks (age-related median: 0.07  $\mu\text{g/l}$ ) followed by normalization in a newborn with an uneventful clinical course after resuscitation at birth. Serial echocardiographs showed normal cardiac function. Such a time course of cTnI, not previously reported, could be due to either a greater sensitivity of biochemical markers than of instrumental tools or birth asphyxia. Larger studies are needed.

**Keywords:** *Perinatal asphyxia, transient myocardial ischemia of the newborn, cardiac troponins*

### Introduction

Transient myocardial ischemia (TMI) and myocardial damage are relatively common complications of birth asphyxia and other perinatal conditions [1–3]. In the past, the diagnosis of neonatal cardiac injury was difficult due to the lack of specific biochemical markers. The recent availability of cardiac troponins with higher tissue specificity than other markers such as creatine kinase MB fraction [3–5] suggests their adoption as reliable indicators of cardiac injury even in newly born infants [6].

We report here the case of a newborn who required resuscitation for a short time in the delivery room and thereafter presented with an atypical and prolonged rise of cardiac troponin I (cTnI) level.

### Case report

A female infant was born at term by spontaneous delivery (birth weight 2780 g). She showed mild birth asphyxia (Apgar score: 1 min = 3, 5 min = 9) and required bag and mask ventilation with oxygen. She was therefore admitted to our neonatal intensive-care unit (NICU) in good clinical condition. Balanced

mild metabolic acidosis (pH = 7.42, arterial  $p\text{CO}_2$  = 24 mmHg,  $\text{HCO}_3^-$  = 15.4 mmol/l, arterial lactate = 5 mmol/l) was demonstrated 90 min after birth. As part of the standard care of asphyxiated newborn infants, we performed continuous electrocardiographic monitoring and serial measurements of cTnI using an automated analyzer (Dimension RxL; Dade Behring, Newark, DE, USA). The analytical performance was similar to that described elsewhere [7]: in particular, day-to-day coefficient of variation was lower than 10%. No electrocardiographic sign of TMI emerged in the first 48 h of life according to Jedeikin's criteria [1]. Echocardiography in the first day of life excluded congenital heart diseases, coronary anomalies and left ventricular segmental dysfunction. The clinical and laboratory course was uneventful. Thus, on day 2 of life, the infant was transferred from the NICU to the normal care unit of our institution even though cTnI concentration showed an upward trend (Figure 1) during the first days of life. The latter exceeded the upper reference limit (Table I) we previously defined for our neonatal population [8]. The patient was discharged on day 3 of life, in healthy condition and breastfed. Electrocardiograms, echocardiographic recordings and

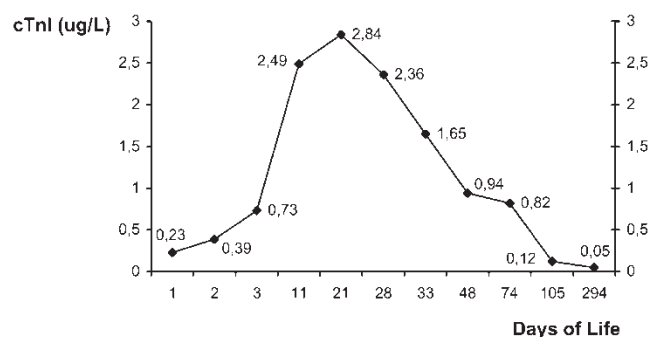


Figure 1. Plasma concentration of cardiac troponin I (cTnI) from day 1 to day 294 of life.

Table I. Upper reference limits for plasma concentration ( $\mu\text{g/l}$ ) of cardiac troponin I in the first month of life.

Day of life	n	Median	Lower quartile	Upper quartile
1	34	0.07	0.04	0.15
2	17	0.11	0.04	0.15
3	12	0.11	0.03	0.18
8–12	16	0.14	0.05	0.26
13–21	10	0.07	0.02	0.1
22–30	11	0.16	0.08	0.32

blood cTnI assays were therefore scheduled for follow-up. In the following weeks the infant was healthy and showed normal cardiac function (left ventricular ejection fraction consistently remained around 70%). However, cTnI concentration increased markedly to a peak value of 2.84  $\mu\text{g/l}$  at 3 weeks of life, returning within the reference interval at 3.5 months (0.12  $\mu\text{g/l}$ ) and falling to below 0.1  $\mu\text{g/l}$  at 9.5 months of age (Figure 1).

## Discussion

Troponins usually show near-zero background levels in adults as well as newly born infants [5]. Thus, a rise of troponin, even in the absence of echocardiographic findings or other markers of elevation, reliably indicates cardiac damage or myocardial ischemia [9].

Interestingly, short-lived cTnI elevations have been reported in adult patients with chest pain without cardiac ischemic disease [10], and troponin level have been evaluated for detecting minor myocardial damage in adult patients with acute non-cardiac disease [11]. Furthermore, in newborns, several perinatal conditions can be complicated by TMI or troponin elevations following a perinatal injury [1–3,6,12]. Even if, according to many authors, TMI is a self-limiting problem, the effects of a long-lasting event, if any, have been considered a relevant question since TMI was first reported [1].

In the present case report we describe an episode of mild perinatal asphyxia followed by a healthy clinical course associated with increased cTnI extending until the 3rd week of life. The latter course has been previously reported [3], but the remarkable aspect of our case is that cTnI remained high for a long time (almost until 3 months of life) without any clinical or instrumental sign of cardiovascular disease (Figure 1). To our knowledge, this is the first report of such a time course of cTnI in a newborn and we speculate a role of birth asphyxia. The intrinsic mechanism might be due to a fragmentation of troponins and/or their intracellular compartmentation [3,5]. Nevertheless, the phenomenon remains only partly understood.

Both the lack of any evidence of TMI in the clinical course of our case and the lack of any echocardiographic evidence of left ventricular segmental dysfunction in the follow-up could suggest that cTnI might provide higher sensitivity than instrumental diagnostic tools at substantially lower cost. Larger studies are needed to confirm this potential.

## References

- Jedeikin R, Primhak A, Shennan AT, et al. Serial electrocardiographic changes in healthy and stressed neonates. *Arch Dis Child* 1983;58:605–11.
- Panteghini M, Agnoletti G, Pagani F, Spandrio M. Cardiac troponin T in serum as marker for myocardial injury in newborns. *Clin Chem* 1997;43:1455–7.
- Adamcova M, Kokstein Z, Palicka V, et al. Cardiac troponin T in neonates after acute and long-term tocolysis. *Biol Neonate* 2000;78:288–92.
- Ghaemmaghami CA, Nooy RV, Ullman E, et al. Troponin I usurps the role of CKMB in the biochemical diagnosis of myocardial injury. *Acad Emerg Med* 2001;8:552–3.
- Wu AHB, Jialal I. How specific is cardiac troponin? *Am J Clin Pathol* 2000;114:509–11.
- Moller JC, Thielsen B, Schaible TF, et al. Value of myocardial hypoxia markers (creatinine kinase and its MB-fraction, troponin-T, QT-intervals) and serum creatinine for the retrospective diagnosis of perinatal asphyxia. *Biol Neonate* 1998;73:367–74.
- Hafner G, Peetz D, Dati F, et al. Analytical and clinical evaluation of troponin I determination on Dimension RXL-HM. *Clin Chem Lab Med* 2000;38:355–61.
- Cavalli C, Dorizzi RM, Caputo M, Biban P. Serendipitous detection of umbilical venous catheter displacement by cardiac troponin I measurement. *Clin Chem* 2001;47:1328–9.
- Menhusen M. Isolated troponin I elevation in acute myocardial infarction: a case report. *Aviat Space Environ Med* 2002;72:763–4.
- Wright SA, Sawyer DB, Sacks DB, et al. Elevation of troponin I levels in patients without evidence of myocardial injury. *J Am Med Assoc* 1997;278:2144.
- Arlati S, Brenna S, Prencipe L, et al. Myocardial necrosis in ICU patients with acute non-cardiac disease: a prospective study. *Intensive Care Med* 2000;26:31–7.
- Trevisanuto D, Zaninotto M, Altinier S, et al. High serum cardiac troponin T concentrations in preterm infants with respiratory distress syndrome. *Acta Paediatr* 2000;89:1134–6.