

# Endoscopic Ultrasound Guided Gallbladder Interventions: a Review of the Current Literature

Stefano Francesco Crinò<sup>1\*</sup>, Mihai Rimbaş<sup>2\*</sup>, Armando Gabbrielli<sup>1</sup>, Alberto Larghi<sup>3</sup>

1) Gastroenterology and Digestive Endoscopy Unit, The Pancreas Institute, University Hospital of Verona, Verona, Italy

2) Gastroenterology Department, Colentina Clinical Hospital, Carol Davila University of Medicine, Bucharest, Romania

3) Digestive Endoscopy Unit, Fondazione Policlinico Universitario A. Gemelli, IRCCS, Rome, Italy

## ABSTRACT

Interventional endoscopic ultrasound (EUS) is a rapidly expanding field with a wide variety of indications, including different drainage procedures and delivery of locoregional treatment mainly for pancreatic solid tumors. Transgastric or transduodenal gallbladder drainage in high-risk patients with acute cholecystitis or biliary decompression in patients with unresectable distal biliary malignant obstruction who failed endoscopic retrograde cholangiography is one of the newest areas of EUS-guided intervention. The large-caliber lumen apposing metal stents placed during these procedures allow direct endoscopic gallbladder access and the possibility of performing gallstone treatment or resection of mucosal polyps. The current review presents the indications of endoscopic gallbladder interventions and discusses the results of available studies, foreseeing future potential applications.

**Key words:** endoscopic ultrasound – biliary drainage – lumen apposing metal stent – acute cholecystitis.

**Abbreviations:** AE: adverse event; EUS: endoscopic ultrasound; ERCP: endoscopic retrograde cholangio-pancreatography; ETD: endoscopic transpapillary drainage; LAMS: lumen apposing metal stents; LC: laparoscopic cholecystectomy; PT-GBD: percutaneous transhepatic gallbladder drainage.

## Address for correspondence:

Stefano Francesco Crinò MD  
Gastroenterology and Digestive Endoscopy Unit  
The Pancreas Institute,  
University Hospital of Verona  
P.le L.A. Scuro, 37134, Verona,  
Italy  
stefanofrancesco.crinò@aovr.  
veneto.it  
stefanocrino@hotmail.com

## INTRODUCTION

Endoscopic ultrasound (EUS) has progressed over the last years from a purely diagnostic tool into an interventional technique, allowing minimally invasive procedures that have gradually substituted previous approaches and become the standard of care. This is the case with the gallbladder, an area never explored before. The most frequent indication is gallbladder drainage in patients with acute cholecystitis unfit for surgery. The availability of dedicated lumen apposing metal stents (LAMS) has made the interventional EUS technically easier and inspired some interventional endosonographers to use the

same approach to decompress the biliary system in patients with unresectable distal biliary malignant obstruction and failed endoscopic retrograde cholangio-pancreatography (ERCP). The stable communication of the gallbladder with the stomach/duodenum created by LAMS with an inner diameter of 10 to 15mm allows cholecystoscopy performed with a gastroscope and, subsequently, gallstone removal or polyp resection.

The aim of this review is to present the current literature regarding EUS-guided gallbladder drainage procedures and the novel direct gallbladder endoscopic interventions.

Several databases (Medline, Embase, and Cochrane Central) were investigated. The search terms included “endoscopic ultrasound”, “acute cholecystitis”, “gallbladder”, “gallstones” and “cholecystostomy”. Articles were reviewed by title and abstracts by two independent reviewers (S.F.C., M.R.) and duplicates were removed. We selected the studies that evaluated the EUS approach for gallbladder drainage or for creating cholecysto-enteric communication allowing direct endoscopic access. Only English language articles were included.

The initial search identified 706 articles, of which 31 comprised endoscopic gallbladder interventions.

Received: 22.06.2019

Accepted: 08.08.2019

\* equally contributed

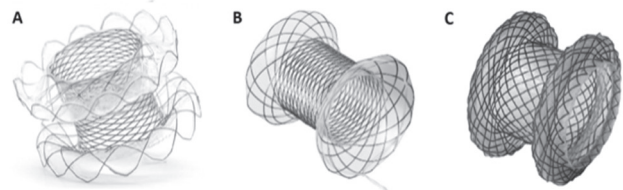
## EUS-GUIDED GALLBLADDER DRAINAGE FOR ACUTE CHOLECYSTITIS IN HIGH-RISK PATIENTS

Laparoscopic cholecystectomy (LC) represents the gold standard for urgent treatment of acute cholecystitis. However, in critically ill patients, the surgical approach is associated with a significant risk of morbidity (up to 41%) [1, 2] and mortality (up to 19%) [3]. Therefore, in this setting, minimally-invasive alternative drainage procedures have been performed as a bridge to surgery or even as a definitive treatment. Currently, two options are worldwide established: ultrasound-guided percutaneous transhepatic gallbladder drainage (PT-GBD) [4] and endoscopic transpapillary stenting or drainage (ETD) [5]. Both approaches have several limitations. Despite a technical success of nearly 100%, PT-GBD is characterized by a significant rate of adverse events (AEs) (mean 6.2%, range 0-25%, including intrahepatic hemorrhage, pneumothorax, or biliary peritonitis) [3] and a mortality that can be as high as 17.5% in poor surgical candidates [6]. Furthermore, recurrent cholecystitis or inadvertent tube dislodgement and migration requiring repetition of the PT-GBD procedure occur in up to 12% of cases [3]. Last but not the least, the percutaneous catheter determines a significant degree of discomfort and local pain for the patient [3]. The ETD has a technical success rate of about 80% [7]. The main difficulty is related to the selective guide-wired cannulation of the cystic duct. It is often technically challenging and time-consuming given the angulation of the cystic duct takeoff, often associated with a narrowing of cystic duct orifice from edema, obstruction by stones or tumor, besides its valves and tortuosity. After the guide-wire is coiled in the gallbladder, the cystic duct dilation with a 6-Fr or 8-Fr dilator can be performed before placing a plastic double pigtail biliary stent (usually with a caliber of 7-Fr) with a pigtail into the gallbladder and the other into the duodenal lumen, across the ampulla. In addition to technical difficulties, the clinical response rate of ETD is not higher than 75% with an incidence of procedure-related AEs ranging between 0 to 14% [7].

Since 2007, EUS-guided transmural gallbladder drainage (EUS-GBD) has been proposed as an alternative treatment to the previous minimally-invasive techniques [8]. Several retrospective and prospective studies have been published reporting the feasibility and safety of the procedure both using conventional drainage devices (nasobiliary drainage, plastic stents, or self-expandable metal stent - SEMS) or LAMS [8-20]. In the initially described technique, the gallbladder was punctured using a FNA needle, then a 0.035- or 0.025-inch guidewire was inserted, and the fistula tract dilated using a 4mm balloon or a tapered catheter. Sometimes an electrocautery device (e.g., a needle-knife) had to be used to definitely allow the stent-delivery passage. Finally, conventional drainage devices (plastic double pigtails, SEMS, or nasobiliary drainage) were inserted. Despite a theoretically increased risk of bile leakage compared with SEMS, in the case of EUS-GBD performed as a “bridge to surgery” or in patients likely to undergo LC after transmural drainage, plastic stents or nasobiliary drainage should be preferred and should be placed transgastrically when possible. Indeed, in the study of Jang et al.

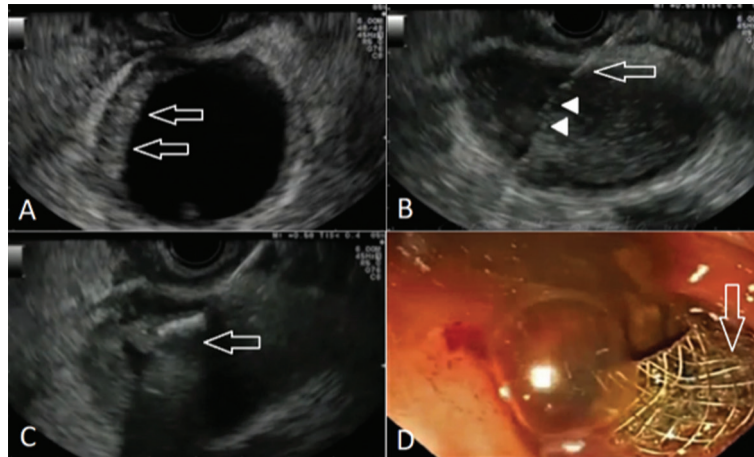
[11], 23 patients underwent cholecystectomy after EUS-GBD performed with plastic devices and no adhesions between the gallbladder and the surrounding tissue complicated the surgical procedure [11]. Compared with plastic stents, standard SEMS are associated with longer patency and could reduce the risk of a bile leak. However, stent migration can occur with SEMS not designed for this type of procedure. To prevent SEMS migration, an additional double pigtail plastic stent can be inserted through the SEMS [12, 13, 15]. Overall, this “initial” technique was used in about 220 patients, with a clinical success of 95% and a 7% AEs rate [8-16].

The recently available LAMS, specifically designed to juxtapose two hollow organs/cavities to create a stable anastomosis/fistula tract, has represented a technical advancement for EUS-GBD, with the advantages of a decreased risk for bile leak and stent migration due to the shape of the flanges of these stents [17-21]. Different types of LAMS with different shapes are currently available (Fig. 1). Moreover, the large caliber of the LAMS (10 mm or more) allows better drainage, making the procedure more effective and definitive. In addition, the LAMS mounted on a delivery system with a cautery device at its tip (Hot-Axios™, Boston Scientific, Marlborough, Massachusetts, USA) has provided an additional advantage, rendering the procedure faster and easier to be accomplished. Indeed, a single step procedure without the need for accessory exchange can be done (Fig. 2). A recent meta-analysis including 13 studies on 233 patients demonstrated an overall clinical success of 92.5% and an AEs rate of 18% [22]. Moreover, a systematic review with pooled analysis published in 2016 suggested a lower rate of AEs by using LAMS compared with plastic stents [23].



**Fig. 1.** Lumen-apposing or bi-flanged self-expandable metal stents that were studied for EUS-guided gallbladder drainage. A) The Spaxus™ stent; B) The NAGI™ stent; C) The AXIOS™ stent which can be mounted on and inserted with an electrocautery-enhanced delivery system [images courtesy of: A-B) Taewoong Medical Co., Ltd.; C) Boston Scientific Corp].

Regardless of the type of stent, EUS-GBD can be carried out by puncturing the gallbladder from the stomach or from the duodenum. The access site is usually chosen according to the best visualization of the gallbladder with the shorter distance from the gastrointestinal wall. Moreover, if the procedure is performed as a “bridge to surgery” the transgastric route is preferred because the stomach can be easily sealed during a cholecystectomy in case of adherence, while for definitive treatment the transduodenal route should be used to avoid reflux of the bile in the stomach and in the esophagus. No difference in overall technical, clinical success, and adverse events rate has been observed between the two access sites [16, 24]. However, due to the reduced mobility of the duodenum compared with the stomach, the risk of stent migration



**Fig. 2.** EUS-guided drainage using a lumen-apposing metal stent (LAMS) in a patient with acute cholecystitis with multiple co-morbidities unfit for surgical cholecystectomy. A) Endoscopic ultrasound appearance of the gallbladder, which presents an obviously thickened wall (arrows); B) EUS-guided puncture of the gallbladder with a 19-gauge needle (arrow), through which a guidewire was inserted (arrowheads); C) Over-the-guidewire insertion of a LAMS; in this step the distal flange was deployed (arrow); D) After proximal flange (arrow) was deployed inside the duodenum: pus is seen draining from the gallbladder.

is theoretically lower with the transduodenal approach. Moreover, food impaction is less likely to occur when the procedure is performed from the duodenum. On the other hand, the large body of the gallbladder is usually visualized from the stomach and is easier to be punctured compared with the smaller gallbladder neck normally visualized from the duodenum. Furthermore, if a perforation occurs during EUS-GBD, the subsequent surgical management is easier when the procedure is performed from the stomach.

Whether and when the stent, especially SEMS or LAMS, should be removed is unknown. In the study of Choi et al. [12] evaluating long-term outcomes after EUS-GBD in 56 patients, the median stent patency was 190 days and the rate of late AEs was 7%. The decision to remove or leave in place the stent should be strictly related to the life expectancy of the patients [14, 20]. In patients with short-term survival (e.g., with advanced malignancy or severe comorbidities) the stent could be left in place to avoid the discomfort of a repeated procedure for stent removal [20]. Conversely, when survival is likely to be longer, stent removal should be considered to reduce the risk of late adverse events (i.e., stent migration, bleeding, tissue overgrowth, stent disfunction) [14]. In these cases, SEMS can be exchanged with a plastic double pig-tail stent for safety reasons and to further reduce the risk of recurrent cholecystitis.

### EUS-GBD VERSUS PT-GBD FOR ACUTE CHOLECYSTITIS

So far, there have been no good quality studies published comparing EUS-GBD and PT-GBD (Table I). Jang et al. [11] published a first comparative study in 2012 involving 59 patients who were randomized in two arms (30 in EUS-GBD and 29 in PT-GBD). EUS drainage was performed by placing a 5-Fr nasobiliary drainage after puncturing the gallbladder with a 19G needle and dilating the tract with a 6-Fr dilator. The reported technical success rate was 97% in both arms, and

the clinical success rate was 100% for EUS-guided drainage versus 97% for PT-GBD. However, in patients who underwent EUS-guided drainage, a significant decrease in the median post-procedural pain score was observed (1 vs. 5,  $p < 0.001$ ). The described technique needs several devices exchange over the guidewire, which in non-expert hands could result in failures and in AEs. Moreover, in this study the majority of patients underwent gallbladder drainage as a “bridge” to cholecystectomy, thus the follow-up period was extremely short (less than two weeks) to fully assess long-term post-procedural AEs.

In 2017, Choi et al. [25] published a study comparing EUS-GBD and PT-GBD in patients with malignant cystic duct obstruction. This was a retrospective single center study involving 14 patients with acute cholecystitis or symptomatic gallbladder hydrops, in which EUS-GBD was performed by placing a transmural SEMS using a 19G needle and a dilator before stent delivery, similarly to the technique described by Jang et al. [10]. Nineteen patients treated with PT-GBD were used as a control group. Technical and clinical success in the EUS-GBD group was 85.7% and 91.7%, and in the PT-GBD group 100% and 86.4%, respectively, with no statistically significant differences. Similar AEs rate (28%) for the two groups was observed after a median follow-up of 60 days. Conclusions, however, were limited by the small sample size, retrospective design, and utilization of SEMSs not specifically designed for this type of procedure, thus potentially accounting for some AEs and cholecystitis recurrence.

Currently, two retrospective studies comparing EUS-GBD with LAMS and PT-GBD are available [24, 26]. The first one is a 1:1 matched cohort study, in which both the device without or with the cautery tip (the Axios™ and the Hot-Axios™, Boston Scientific, Marlborough, Massachusetts, USA) were used for EUS-GBD and compared to PT-GBD [24]. The study included 59 patients per group, but the overall follow-up period was not reported. Technical and clinical success rates were comparable,

**Table I.** Summary of studies comparing percutaneous with endoscopic ultrasound-guided gallbladder drainage

Author, year	Design	Percutaneous gallbladder drainage					Endoscopic ultrasound-guided gallbladder drainage				
		Patients (N)	Device	Technical success	Clinical success	Adverse events	Patients (N)	Device	Technical success	Clinical success	Adverse events
Jang, 2012 [14]	Prospective randomized	29	8.5-Fr pigtail catheter	28/29 (97%)	27/29 (93%)	1/29 (3%)	30	5-Fr nasobiliary drainage	29/30 (97%)	29/30 (97%)	2/30 (7%)
Tyberg, 2016 [19]	Retrospective	113	7- to 12 Fr pigtail catheter	112/113 (99%)	97/113 (86%)	24/113 (21%)	42	PS, SEMS, LAMS*	40/42 (95%)	40/42 (95%)	9/42 (21%)
Teoh, 2017 [17]	Retrospective, matched-cohort	59	6- to 10 Fr pigtail catheter	59/59 (100%)	56/59 (95%)	44/59 (75%)	59	10- or 15-mm LAMS	57/59 (97%)	53/59 (90%)	19/59 (32%)
Irani, 2017 [18]	Retrospective	45	8- or 10-Fr pigtail catheter	45/45 (100%)	14/45 (91%)	14/45 (31%)	45	10- or 15-mm LAMS*	44/45 (98%)	43/45 (96%)	8/45 (18%)
Choi, 2017 [15]	Retrospective, case-control	19	8.5-Fr pigtail catheter	19/19 (100%)	17/19 (86%)	4/19 (21%)	14	Fully covered SEMS	12/14 (86%)	11/14 (79%)	4/14 (29%)
Siddiqui, 2018 [30]	Retrospective	146	8- or 10-Fr pigtail catheter	143/146 (98%)	141/146 (97%)	6/146 (4%)	102	10- or 15-mm LAMS*	96/102 (94%)	92/102 (90%)	12/102 (32%)
Total		411	-	406/411 (99%)	352/411 (86%)	93/411 (23%)	292	-	278/292 (95%)	268/292 (92%)	54/292 (18%)

LAMS: lumen-apposing metal stent; PS: plastic stent; SEMS: self-expanding metal stents; \*Both electrocautery-enhanced and nonelectrocautery-enhanced.

but in the EUS-GBD group fewer patients suffered from overall AEs (32% vs. 75%,  $p < 0.001$ ) and serious AEs (24% vs. 75%,  $p < 0.001$ ) compared to the PT-GBD group. Some biases could account for these results as suggested by such a high rate of AEs in the PT-GBD group as compared with the literature. Patients in the EUS-GBD group required fewer unplanned admissions (7% vs. 71%,  $p < 0.001$ ), which in 95% of cases were due to problems related to the cholecystostomy tube in the PT-GBD arm. Acute cholecystitis recurred in 4 (6.8%) patients treated by PT-GBD and in none in the EUS-GBD group ( $p = 0.12$ ). However, the 30-day mortality rate was higher in the EUS-GBD group (5 patients [8.5%] vs. 1 patient [1.7%]) but was not statistically significant ( $p = 0.21$ ). In this study, the authors for the first time used a specific follow-up schedule for EUS-GBD patients who underwent cholecystoscopy 12 weeks after the procedure using a standard endoscope through the previously placed LAMS, to check for residual stones and if necessary, to perform lithotripsy until complete clearance. Once clearance was obtained, the LAMS was exchanged for a plastic stent.

The second study is a multicenter retrospective study in 90 high-risk surgical patients with acute cholecystitis (45 managed by EUS-GBD and 45 by PT-GBD) [26]. As in the previous study, cautery and non-cautery LAMS were used. Technical and clinical success rates were comparable between the two groups (89% vs. 100%, and 96% vs. 91% for EUS-GBD and PT-GBD, respectively). Fewer AEs occurred in the EUS-GBD group (8 vs. 14,  $p = 0.07$ ), with no differences in severity or deaths. Post-procedural pain scores were lower in the EUS-GBD group ( $p < 0.05$ ), as well as the length of hospital stay (3 days vs. 9 days,  $p < 0.05$ ) and the need for repeated interventions (11 vs. 112,  $p < 0.01$ ).

Finally, another retrospective study by Tyberg et al. [16] compared EUS-GBD performed using different types of SEMS with PT-GBD. Comparable outcomes for EUS-GBD and PT-

GBD regarding technical and clinical success and the rate of immediate and delayed AEs were found.

Recently, a meta-analysis compared the outcomes of 298 patients treated by PT-GBD and 206 patients who underwent EUS-GBD [27]. No statistically significant differences both in technical and clinical success were observed. However, patients in the EUS-GBD group experienced fewer AEs, had shorter hospital stay with fewer readmissions, and required less frequently reinterventions [27].

## EUS-GBD VERSUS ETD FOR ACUTE CHOLECYSTITIS

Regarding ETD versus EUS-GBD, two studies were recently published [28, 29]. The first study including 172 patients (76 EUS-GBD and 96 ETD) showed in the EUS-GBD group significantly higher technical and clinical success rates (99% vs. 83%, and 99% vs. 82%, respectively,  $p < 0.01$ ), a better safety profile (procedure-related AEs after statistical adjustment of 7% vs. 19%,  $p = 0.02$ ) and lower post-procedural cholecystitis and cholangitis rates (3% vs. 12%,  $p = 0.04$ ) [28]. In the second one, EUS-GBD was performed in 40 patients by using a LAMS (both with electrocautery and nonelectrocautery tip) whereas 38 patients underwent ETD with a 7-Fr double pigtail stent. As in the first study, technical and clinical success were higher in the EUS-GBD group compared with the ETD group (97% vs. 84%, and 95% vs. 76%, respectively). Moreover, the rate of recurrent cholecystitis was significantly lower after EUS-GBD (2.6% vs. 18.8% in the ETD group) [29].

A three-way retrospective study comparing EUS-GBD vs. PT-GBD vs. ETD is also available [30]. In this study, 372 patients were included (146 by PT-GBD, 124 by ETD, and 102 EUS-GBD). Technical and clinical success rates were significantly higher for PT-GBD and EUS-GBD (98% vs.

**Table II.** Summary of studies comparing endoscopic transpapillary with endoscopic ultrasound-guided gallbladder drainage

Author, year	Design	Endoscopic transpapillary gallbladder drainage					Endoscopic ultrasound-guided gallbladder drainage				
		Patients (N)	Device	Technical success	Clinical success	Adverse events	Patients (N)	Device	Technical success	Clinical success	Adverse events
Oh, 2019 [28]	Retrospective	96	7-Fr double pigtail stent	80/96 (83%)	79/96 (82%)	9/96 (9%)	76	SEMS	75/76 (99%)	75/76 (99%)	6/76 (8%)
Higa, 2019 [29]	Retrospective	38	7-Fr double pigtail stent	32/38 (84%)	29/38 (76%)	3/38 (8%)	40	10- or 15-mm LAMS*	39/40 (97.5%)	38/40 (95%)	7/40 (17.5%)
Siddiqui, 2018 [30]	Retrospective	124	5- to 10-Fr double pigtail stent	109/124 (88%)	99/124 (80%)	9/124 (7%)	102	10- or 15-mm LAMS*	96/102 (94%)	92/102 (90%)	12/102 (32%)
Total		258	-	221/258 (86%)	207/258 (80%)	21/258 (8%)	218	-	210/218 (96%)	205/218 (94%)	25/218 (11%)

SEMS: self-expanding metal stents; LAMS: lumen-apposing metal stent. \*Both electrocautery-enhanced and nonelectrocautery-enhanced.

88% vs. 94%,  $p = 0.004$ ; and 97% vs. 90% vs. 80%,  $p < 0.001$ , respectively). Significantly higher post-procedural AEs rate and additional surgical interventions were reported for PT-GBD (20% vs. 2% vs. 5%,  $p = 0.01$ ; and 49% vs. 4% vs. 11%,  $p < 0.0001$ , respectively) [30]. Outcomes of studies comparing EUS-GBD with ETD are summarized in Table II.

### EUS-GBD AS AN ALTERNATIVE ROUTE FOR BILIARY DECOMPRESSION

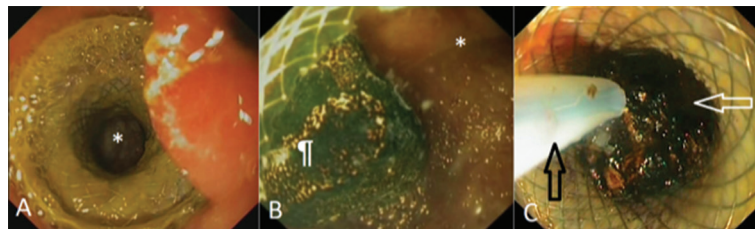
In patients with unresectable malignant distal biliary obstruction and a patent cystic duct communicating with the obstructed biliary system, drainage of the gallbladder appears a viable alternative of biliary drainage in case of failures of ERCP [31]. In this clinical setting, EUS drainage can be more easily performed through the gallbladder than the dilated bile duct, due to gallbladder distension with a large surface superficially located, with generally no interposing structures with the gastric or duodenal wall. Careful examination to exclude cystic duct involvement prior to performing the drainage is mandatory, as is intraprocedural cholangiogram.

Only one small study on 12 patients evaluated EUS-GBD for this indication and reported technical and clinical success for biliary drainage in 100% and 91.7% of cases [32], promoting this technique as potentially useful for cases with previously failed ERCP and a patent cystic duct. In this situation, where

drainage is left in place indefinitely, the transduodenal route is favoured over the transgastric one, because it avoids bile reflux through the stomach into the esophagus.

### DIRECT ENDOSCOPIC GALLSTONE TREATMENT

Removal of gallstones, the most common cause of cholecystitis, seems feasible once the gallbladder has been accessed (Fig. 3). The wide opening of the currently available LAMS offers an “open door” for most of the stones to naturally leave the gallbladder and provides a second drainage route for the bile secretions in case of cystic duct blockage. When large stones are retained in the gallbladder and cannot be removed using Dormia baskets, despite balloon dilation of the mid portion of the stent, access of the gallbladder with a standard endoscope and intraluminal lithotripsy either with holmium laser or mechanical devices can be done [33]. Stone fragments can be flushed out or removed from the gallbladder using a polypectomy retrieval basket until complete clearance is obtained, as previously shown [34]. This is relevant given the potential risk of recurrent cholecystitis due to residual stones impaction in the stent. Once clearance has been obtained, LAMS can be removed using a snare or grasping forceps and the fistula tract completely closed using an over-the-scope clip [33] or standard clips [35].



**Fig. 3.** Direct endoscopic gallbladder stones removal. A) The gallbladder lumen (\*) is visible through a lumen-apposing metal stent (LAMS) previously placed under EUS-guidance creating a cholecysto-gastrostomy. B) The cholecysto-gastrostomy is entered with an endoscope depicting the regular aspect of the gallbladder mucosa (\*) and gallbladder stones (♣). C) Gallbladder stones (white arrow) being extracted with a Dormia basket (black arrow) through the lumen of the LAMS.

## ENDOSCOPIC GALLBLADDER MUCOSA IMAGING

Once the gallbladder has been accessed, the available technologies already implemented for regular endoscopy can be applied for mucosa examination. Virtual chromoendoscopy techniques can be used to inspect for neoplastic tissue detection. Confocal imaging, cholangioscopy or high frequency miniprobe for intraluminal ultrasound can also be used to examine the gallbladder mucosa. Only initial reports have been published so far [34], and the detection of early gallbladder mucosal neoplasia remains challenging. A histology study reported that none of the 37 cases with suspected dysplasia at gallbladder mucosa examination was confirmed at the histology examination of the surgical specimen [36].

## ENDOSCOPIC GALLBLADDER POLYPECTOMY THROUGH EUS-GUIDED CHOLECYSTO-ENTEROSTOMY

Gallbladder polyp prevalence can reach 9.5% [37]. However, up to 70% of suspected gallbladder polyps are pseudopolyps (cholesterol or inflammatory pseudopolyps or focal adenomyomatosis) with no malignant potential [38]. True polyps are generally adenomas but, in contrast to colonic polyps, the adenoma-carcinoma sequence is not well established. The low incidence of gallbladder adenomas and the presence of adenomatous remnants in the mucosa close to early carcinomas in less than 3% of the cases suggest the limited importance of this carcinogenic pathway [39]. Current guidelines recommend LC for large (>10mm) polyps, or for middle-sized polyps (6-9mm) in high-risk patients (age >50 years, Indian ethnicity, primary sclerosing cholangitis, sessile polyps) [40]. Surgery is also indicated in symptomatic patients because polyps can be indicative of underlying inflammation or cholelithiasis [40].

In 2011, Chen et al. [41] reported the first case of endoscopic gallbladder polypectomy through a previously performed surgical cholecysto-gastrostomy [41]. EUS-guided cholecysto-gastrostomy or cholecysto-duodenostomy with large lumen through LAMS makes possible the direct endoscopic polypectomy. In 2016, Ge et al. [42] reported a small case series of EUS-GB access using a LAMS followed by gallstones removal in seven cases and gallbladder polypectomy in two cases. Recently, Tian et al. [35] described another case of successful gallbladder polypectomy of three polyps through an electrocautery-enhanced LAMS. In this case, authors had to remove the LAMS before the last polypectomy because of the difficult visualization and the limited operating space.

A possible advantage of endoscopic polypectomy is that no incision in the abdominal wall is necessary, offering better cosmetic results as compared to LC. Another theoretical advantage of the EUS approach is the preservation of the gallbladder. However, the long-term rate of polyps recurrence is unknown, thus repeated endoscopic treatment could be required over time. Moreover, it is unknown if the gallbladder wall can sustain a polypectomy in all cases.

Endoscopic gallbladder polypectomy through an EUS-guided cholecysto-enterostomy should at present be offered

only when cholecystectomy is absolutely contraindicated, in patients who refuse surgery, or in those in whom EUS-GBD has been already performed for acute cholecystitis treatment and the presence of polyp(s) disclosed after the procedure. In all these cases, whenever possible, it could be convenient to perform the drainage of the gallbladder from the stomach to avoid formation of adherence from the gallbladder wall and the duodenum, which can make a subsequent surgical intervention more difficult.

## DISCUSSION

Based on current evidence from the available studies, advantages of EUS-GBD over the percutaneous approach are mainly in terms of quality of life, the decreased need for repeat procedures, and the capability of solving the cause of the cholecystitis. However, because of the retrospective design of the available comparative studies, no definitive conclusions can be drawn, and randomized controlled trials are desperately needed. With regard to the latter, a randomized study (NCT01146743) was completed several years ago, but results are not yet available. Hopefully, further evaluations will come from another randomized trial comparing PT-GBD and EUS-GBD that is still ongoing (NCT02212717). Up to now, based on the conclusions of the Tokyo guidelines on management strategies in patients with acute cholecystitis, EUS-GBD should be considered in high-volume centers when performed by skilled echoendoscopists (level of evidence B) [43].

At present, the main indication for EUS-GBD is acute cholecystitis in high-risk surgical patients [44], but a number of different EUS-guided gallbladder interventions could be foreseen for the near future, as already discussed. However, little is known about the long-term consequences of creating a cholecysto-enteric anastomosis. Alterations in the normal physiological functions of the gastrointestinal tract might result in long-term effects on the gastrointestinal and biliary mucosal surfaces. One representative case attributed to cholecystectomy is the increased risk of colorectal cancer [45]. Likewise, a cholecysto-gastro-anastomosis, with the bile flowing into the stomach, might theoretically lead to bile gastritis and an increased risk of gastric cancer, similarly to what is observed in patients with Billroth II anastomosis [46]. Moreover, gallbladder mucosa might be injured by the reflux of enteric content, and recurrent cholecystitis might represent a long-term complication in patients with cholecysto-enteric anastomoses. In the case of cholecysto-enterostomy, the passage of food into the gallbladder is considered inevitable [47, 48] and this might predispose to cholecystitis and cholelithiasis. Regarding recurrence of acute cholecystitis after EUS-GBD, in a small retrospective study it was observed in 1/13 patients (7.7%) after a median follow up of 240 days [49]. In another larger retrospective study on 56 patients followed for a median of 275 days after EUS-GBD, acute cholecystitis recurred in 2 patients (3.6%) due to stent occlusion [12], while in a study using LAMS, after a mean follow-up period of 298 days, 7% of the patients developed recurrent cholecystitis [20].

Looking into the surgically created gallbladder anastomoses, in a retrospective study of 34 patients with cholecysto-enterostomy for benign biliary obstruction over a 17-year

period, five patients (15%) experienced recurrent biliary stones after a mean follow up of 8 years (which is the longest reported so far) [50]. In the same study, biliary obstruction in four cases and anastomotic stricture in one case occurred [50]. In another report, there were five cases of recurrent cholangitis occurring between two to nine years after cholecysto-enteric bypass [51]. Three of these patients required repeat surgery, and chronic inflammation at the anastomosis site was pathologically proven. No patient developed biliary tract or gastrointestinal tract malignancy in these reports [50, 51].

Regarding the neoplastic risk after gallbladder-enteric anastomosis, the available evidence is far more limited. If we refer to biliary-enteric anastomoses in general, there is experimental, clinical, and epidemiological data available to support the risk of cholangiocarcinoma [52-54]. It developed in 5.5% of a cohort of 1,003 patients with biliary-enteric anastomoses collected over a 30-year period [55]. The risk was higher in patients with choledocho-duodenostomy than in those with transduodenal sphincteroplasty or hepatico-jejunostomy (7.6% vs. 4.8% vs. 1.9%, respectively). Interestingly, it has been found that only patients who had recurrent bouts of cholangitis developed cholangiocarcinoma [56], linking infection and inflammation to neoplasia development. Likewise, irritation of the gallbladder mucosa could predispose to gallbladder carcinoma when anastomoses involving this organ are performed and left in place, but so far only two patients who developed gallbladder carcinoma 11 and 22 years after cholecysto-jejunostomy have been reported [57, 58].

All the above considerations seem to have little impact in high-risk surgical patients, in whom life expectancy is limited, while they need to be considered in studies designed to widen the indications for EUS-guided cholecystostomy.

## CONCLUSION AND FUTURE DIRECTIONS

EUS-guided cholecystostomy is steadily gaining its place as a definitive treatment or a bridge to surgery in high-risk surgical patients with acute cholecystitis and might become soon the standard of care in this clinical setting when results of randomized trials become available. These results will be the basis for future studies in patients with less strict inclusion criteria and compared with LC in patients who are fit for surgery. In malignant unresectable distal biliary obstruction, EUS-GBD could also represent a viable option, but more data are needed. Finally, minimally invasive creation of a cholecysto-enteric anastomosis that could allow endoscopic clearance of gallbladder stones, careful exploration of the mucosa with state-of-the-art endoscopic imaging modalities, and endoscopic resection of gallbladder polyps is without any doubt very attractive. However, in cases in which definitive cholecysto-enterostomy needs to be created, a balance between the benefit of the procedure with the long-term risks of malignancy has to be carefully considered. We believe that the beauty is in the eye of the beholder and the future of this procedure looks extremely bright.

**Conflicts of interest:** None to declare.

**Authors' contributions:** A.L., M.R., S.F.C.: concept and design the review; M.R., S.F.C.: literature search and manuscript drafting; M.R., S.F.C.: summary of the relevant data in tables; A.G., A.L., M.R., S.F.C.: critical review of the manuscript. All authors read and approved the final version of the manuscript.

## REFERENCES

1. Decker G, Goergen M, Philippart P, Mendes da Costa P. Laparoscopic cholecystectomy for acute cholecystitis in geriatric patients. *Acta Chir Belg* 2001;101:294-249.
2. Kirshtein B, Bayme M, Bolotin A, Mizrahi S, Lantsberg L. Laparoscopic cholecystectomy for acute cholecystitis in the elderly: is it safe? *Surg Laparosc Endosc Percutan Tech* 2008;18:334-339. doi:10.1097/SLE.0b013e318171525d
3. Winbladh A, Gullstrand P, Svanvik J, Sandström P. Systematic review of cholecystostomy as a treatment option in acute cholecystitis. *HPB (Oxford)* 2009;11:183-193. doi:10.1111/j.1477-2574.2009.00052.x
4. Kiviniemi H, Makela JT, Autio R, et al. Percutaneous cholecystostomy in acute cholecystitis in high-risk patients: an analysis of 69 patients. *Int Surg* 1999;83:299-302.
5. Mutignani M, Iacopini F, Perri V, et al. Endoscopic gallbladder drainage for acute cholecystitis: technical and clinical results. *Endoscopy* 2009;41:539-546. doi:10.1055/s-0029-1214727
6. Hatzidakis AA, Prassopoulos P, Petinarakis I, et al. Acute cholecystitis in high-risk patients: percutaneous cholecystostomy vs conservative treatment. *Eur Radiol* 2002;12:1778-1784. doi:10.1007/s00330-001-1247-4
7. Itoi T, Coelho-Prabhu N, Baron TH. Endoscopic gallbladder drainage for management of acute cholecystitis. *Gastrointest Endosc* 2010;71:1038-1045. doi:10.1016/j.gie.2010.01.026
8. Lee SS, Park DH, Hwang CY, et al. EUS-guided transmural cholecystostomy as rescue management for acute cholecystitis in elderly or high-risk patients: a prospective feasibility study. *Gastrointest Endosc* 2007;66:1008-1012. doi:10.1016/j.gie.2007.03.1080
9. Song TJ, Park DH, Eum JB, et al. EUS-guided cholecystoenterostomy with single-step placement of a 7Fr double-pigtail plastic stent in patients who are unsuitable for cholecystectomy: a pilot study (with video). *Gastrointest Endosc* 2010;71:634-640. doi:10.1016/j.gie.2009.11.024
10. Jang JW, Lee SS, Park DH, Seo DW, Lee SK, Kim MH. Feasibility and safety of EUS-guided transgastric/transduodenal gallbladder drainage with single-step placement of a modified covered self-expandable metal stent in patients unsuitable for cholecystectomy. *Gastrointest Endosc* 2011;74:176-181. doi:10.1016/j.gie.2011.03.1120
11. Jang JW, Lee SS, Song TJ, et al. Endoscopic ultrasound-guided transmural and percutaneous transhepatic gallbladder drainage are comparable for acute cholecystitis. *Gastroenterology* 2012;142:805-811. doi:10.1053/j.gastro.2011.12.051
12. Choi JH, Lee SS, Choi JH, et al. Long-term outcomes after endoscopic ultrasonography-guided gallbladder drainage for acute cholecystitis. *Endoscopy* 2014;46:656-661. doi:10.1055/s-0034-1365720
13. Takagi W, Ogura T, Sano T, et al. EUS-guided cholecystoduodenostomy for acute cholecystitis with an anti-stent migration and anti-food impaction system; a pilot study. *Therap Adv Gastroenterol* 2016;9:19-25. doi:10.1177/1756283X15609285
14. Kamata K, Takenaka M, Kitano M, et al. Endoscopic ultrasound-guided gallbladder drainage for acute cholecystitis: long-term outcomes

- after removal of a self-expandable metal stent. *World J Gastroenterol* 2017;23:661–667. doi:[10.3748/wjg.v23.i4.661](https://doi.org/10.3748/wjg.v23.i4.661)
15. Kahaleh M, Perez-Miranda M, Artifon EL, et al. International collaborative study on EUS-guided gallbladder drainage: are we ready for prime time? *Dig Liver Dis* 2016;48:1054–1057. doi:[10.1016/j.dld.2016.05.021](https://doi.org/10.1016/j.dld.2016.05.021)
  16. Tyberg A, Saumoy M, Sequeiros EV, et al. EUS-guided versus percutaneous gallbladder drainage: isn't it time to covert? *J Clin Gastroenterol* 2018;52:79–84. doi:[10.1097/MCG.0000000000000786](https://doi.org/10.1097/MCG.0000000000000786)
  17. de la Serna-Higuera C, Pérez-Miranda M, Gil-Simón P, et al. EUS-guided transenteric gallbladder drainage with a new fistula-forming, lumen-apposing metal stent. *Gastrointest Endosc* 2013;77:303–308. doi:[10.1016/j.gie.2012.09.021](https://doi.org/10.1016/j.gie.2012.09.021)
  18. Irani S, Baron TH, Grimm IS, Khashab MA. EUS-guided gallbladder drainage with a lumen-apposing metal stent (with video). *Gastrointest Endosc* 2015;82:1110–1115. doi:[10.1016/j.gie.2015.05.045](https://doi.org/10.1016/j.gie.2015.05.045)
  19. Dollhopf M, Larghi A, Will U, et al. EUS-guided gallbladder drainage in patients with acute cholecystitis and high surgical risk using an electrocautery-enhanced lumen-apposing metal stent device. *Gastrointest Endosc* 2017;86:636–643. doi:[10.1016/j.gie.2017.02.027](https://doi.org/10.1016/j.gie.2017.02.027)
  20. Walter D, Teoh AY, Itoi T, et al. EUS-guided gall bladder drainage with a lumen-apposing metal stent: a prospective long-term evaluation. *Gut* 2016;65:6–8. doi:[10.1136/gutjnl-2015-309925](https://doi.org/10.1136/gutjnl-2015-309925)
  21. Manta R, Zulli C, Zullo A, et al. Endoscopic ultrasound-guided gallbladder drainage for acute cholecystitis with a silicone-covered nitinol short bilaterally flared stent: a case series. *Endosc Int Open* 2017;5:E1111–E1115. doi:[10.1055/s-0043-118659](https://doi.org/10.1055/s-0043-118659)
  22. Kalva NR, Vanar V, Forcione D, et al. Efficacy and Safety of Lumen Apposing Self-Expandable Metal Stents for EUS Guided Cholecystostomy: A Meta-Analysis and Systematic Review. *Can J Gastroenterol Hepatol* 2018;2018:7070961. doi:[10.1155/2018/7070961](https://doi.org/10.1155/2018/7070961)
  23. Anderloni A, Buda A, Vieceli F, Khashab MA, Hassan C, Repici A. Endoscopic ultrasound-guided transmural stenting for gallbladder drainage in high-risk patients with acute cholecystitis: a systematic review and pooled analysis. *Surg Endosc* 2016;30:5200–5208. doi:[10.1007/s00464-016-4894-x](https://doi.org/10.1007/s00464-016-4894-x)
  24. Teoh AYB, Serna C, Penas I, et al. Endoscopic ultrasound-guided gallbladder drainage reduces adverse events compared with percutaneous cholecystostomy in patients who are unfit for cholecystectomy. *Endoscopy* 2017;49:130–138. doi:[10.1055/s-0042-119036](https://doi.org/10.1055/s-0042-119036)
  25. Choi JH, Kim HW, Lee JC, et al. Percutaneous transhepatic versus EUS-guided gallbladder drainage for malignant cystic duct obstruction. *Gastrointest Endosc* 2017;85:357–364. doi:[10.1016/j.gie.2016.07.067](https://doi.org/10.1016/j.gie.2016.07.067)
  26. Irani S, Ngamruengphong S, Teoh A, et al. Similar Efficacies of Endoscopic Ultrasound Gallbladder Drainage With a Lumen-Apposing Metal Stent Versus Percutaneous Transhepatic Gallbladder Drainage for Acute Cholecystitis. *Clin Gastroenterol Hepatol* 2017;15:738–745. doi:[10.1016/j.cgh.2016.12.021](https://doi.org/10.1016/j.cgh.2016.12.021)
  27. Luk SW, Irani S, Krishnamoorthi R, Wong Lau JY, Wai Ng EK, Teoh AY. Endoscopic ultrasound-guided gallbladder drainage versus percutaneous cholecystostomy for high risk surgical patients with acute cholecystitis: a systematic review and meta-analysis. *Endoscopy* 2019;51:722–732. doi:[10.1055/a-0929-6603](https://doi.org/10.1055/a-0929-6603)
  28. Oh D, Song TJ, Cho DH, et al. EUS-guided cholecystostomy versus endoscopic transpapillary cholecystostomy for acute cholecystitis in high-risk surgical patients. *Gastrointest Endosc* 2019;89:289–298. doi:[10.1016/j.gie.2018.08.052](https://doi.org/10.1016/j.gie.2018.08.052)
  29. Higa JT, Sahar N, Kozarek RA, et al. EUS-guided gallbladder drainage with a lumen-apposing metal stent versus endoscopic transpapillary gallbladder drainage for the treatment of acute cholecystitis (with videos). *Gastrointest Endosc* 2019 May 2. doi:[10.1016/j.gie.2019.04.238](https://doi.org/10.1016/j.gie.2019.04.238)
  30. Siddiqui A, Kunda R, Tyberg A, et al. Three-way comparative study of endoscopic ultrasound-guided transmural gallbladder drainage using lumen-apposing metal stents versus endoscopic transpapillary drainage versus percutaneous cholecystostomy for gallbladder drainage in high-risk surgical patients with acute cholecystitis: clinical outcomes and success in an International, Multicenter Study. *Surg Endosc* 2019;33:1260–1270. doi:[10.1007/s00464-018-6406-7](https://doi.org/10.1007/s00464-018-6406-7)
  31. Itoi T, Binmoeller K, Itokawa F, Umeda J, Tanaka R. Endoscopic ultrasonography-guided cholecystogastrostomy using a lumen-apposing metal stent as an alternative to extrahepatic bile duct drainage in pancreatic cancer with duodenal invasion. *Dig Endosc* 2013;25 Suppl 2:137–141. doi:[10.1111/den.12084](https://doi.org/10.1111/den.12084)
  32. Imai H, Kitano M, Omoto S, et al. EUS-guided gallbladder drainage for rescue treatment of malignant distal biliary obstruction after unsuccessful ERCP. *Gastrointest Endosc* 2016;84:147–151. doi:[10.1016/j.gie.2015.12.024](https://doi.org/10.1016/j.gie.2015.12.024)
  33. Larghi A, Rimbas M, Attili F, Kunda R. Endoscopic Holmium Laser Lithotripsy of Symptomatic Gallstones Through a Lumen-Apposing Self-Expandable Metal Stent. *Am J Gastroenterol* 2016;111:1516. doi:[10.1038/ajg.2016.258](https://doi.org/10.1038/ajg.2016.258)
  34. Chan SM, Teoh AYB, Yip HC, Wong VWY, Chiu PWY, Ng EKW. Feasibility of per-oral cholecystoscopy and advanced gallbladder interventions after EUS-guided gallbladder stenting (with video). *Gastrointest Endosc* 2017;85:1225–1232. doi:[10.1016/j.gie.2016.10.014](https://doi.org/10.1016/j.gie.2016.10.014)
  35. Tian L, Yang Y, Xiao D, et al. Resection of gallbladder polyps following endoscopic ultrasound-guided cholecystoduodenostomy using a lumen-apposing metal stent. *Endoscopy* 2018;50:E307–E308. doi:[10.1055/a-0631-7970](https://doi.org/10.1055/a-0631-7970)
  36. Rais R, González I, Chatterjee D. Dysplasia in Gallbladder: What Should We Do? *J Gastrointest Surg* 2019;23:686–689. doi:[10.1007/s11605-018-3955-y](https://doi.org/10.1007/s11605-018-3955-y)
  37. Lin WR, Lin DY, Tai DI, et al. Prevalence of and risk factors for gallbladder polyps detected by ultrasonography among healthy Chinese: analysis of 34 669 cases. *J Gastroenterol Hepatol* 2008;23:965–969. doi:[10.1111/j.1440-1746.2007.05071.x](https://doi.org/10.1111/j.1440-1746.2007.05071.x)
  38. Elmasry M, Lindop D, Dunne DF, Malik H, Poston GJ, Fenwick SW. The risk of malignancy in ultrasound detected gallbladder polyps: A systematic review. *Int J Surg* 2016;33 Pt A:28–35. doi:[10.1016/j.ijso.2016.07.061](https://doi.org/10.1016/j.ijso.2016.07.061)
  39. Roa I, de Aretxabala X, Araya JC, Roa J. Preneoplastic lesions in gallbladder cancer. *J Surg Oncol* 2006;93:615–623. doi:[10.1002/jso.20527](https://doi.org/10.1002/jso.20527)
  40. Wiles R, Thoeni RF, Barbu ST, et al. Management and follow-up of gallbladder polyps: Joint guidelines between the European Society of Gastrointestinal and Abdominal Radiology (ESGAR), European Association for Endoscopic Surgery and other Interventional Techniques (EAES), International Society of Digestive Surgery - European Federation (EFISDS) and European Society of Gastrointestinal Endoscopy (ESGE). *Eur Radiol* 2017;27:3856–3866. doi:[10.1007/s00330-017-4742-y](https://doi.org/10.1007/s00330-017-4742-y)
  41. Chen YY, Su PY, Shen WC. Gallbladder polyp treated with endoscopic polypectomy through a cholecystogastrostomy. *Endoscopy* 2011;43 Suppl 2 UCTN:E88–E89. doi:[10.1055/s-0030-1255983](https://doi.org/10.1055/s-0030-1255983)
  42. Ge N, Sun S, Sun S, Wang S, Liu X, Wang G. Endoscopic ultrasound-assisted transmural cholecystoduodenostomy or cholecystogastrostomy as a bridge for per-oral cholecystoscopy therapy using double-flanged fully covered metal stent. *BMC Gastroenterol* 2016;16:9. doi:[10.1186/s12876-016-0420-9](https://doi.org/10.1186/s12876-016-0420-9)



43. Mori Y, Itoi T, Baron TH, et al. Tokyo Guidelines 2018: management strategies for gallbladder drainage in patients with acute cholecystitis (with videos). *J Hepatobiliary Pancreat Sci* 2018;25:87-95. doi:[10.1002/jhbp.504](https://doi.org/10.1002/jhbp.504)
44. Saumoy M, Novikov A, Kahaleh M. Long-term outcomes after EUS-guided gallbladder drainage. *Endosc Ultrasound* 2018;7:97-101.
45. Zhang Y, Liu H, Li L, et al. Cholecystectomy can increase the risk of colorectal cancer: A meta-analysis of 10 cohort studies. *PLoS One* 2017;12:e0181852. doi:[10.1371/journal.pone.0181852](https://doi.org/10.1371/journal.pone.0181852)
46. Păduraru DN, Nica A, Ion D, Handaric M, Andronic O. Considerations on risk factors correlated to the occurrence of gastric stump cancer. *J Med Life* 2016;9:130-136.
47. Løntoft E, Rasmussen L, Pedersen SA. Deleterious circulation of intestinal contents through the biliary tract after cholecystojejunostomy. *Endoscopy* 1991;23:309-310. doi:[10.1055/s-2007-1010702](https://doi.org/10.1055/s-2007-1010702)
48. Kim JJ, Hiotis SP, Sur MD. Gastric Reflux Into the Gallbladder After EUS-guided Stenting-Letter to the Editor Regarding “EUS-guided Versus Percutaneous Gallbladder Drainage: Isn’t It Time to Convert?” *J Clin Gastroenterol* 2019;53:392-393. doi:[10.1097/MCG.0000000000000890](https://doi.org/10.1097/MCG.0000000000000890)
49. Ahmed O, Ogura T, Eldahrouy A, et al. Endoscopic ultrasound-guided gallbladder drainage: Results of long-term follow-up. *Saudi J Gastroenterol* 2018;24:183-188. doi:[10.4103/sjg.SJG\\_506\\_17](https://doi.org/10.4103/sjg.SJG_506_17)
50. Oishi AJ, Sarr MG, Nagorney DM, Traynor MD, Mucha P Jr. Long-term outcome of cholecystoenterostomy as a definitive biliary drainage procedure for benign disease. *World J Surg* 1995;19:616-619.
51. Thomson SR. Sequelae of cholecystojejunostomy for benign intrapancreatic biliary strictures. *S Afr J Surg* 1998;36:26-29.
52. Eleftheriadis E, Tzioufa V, Kotzampassi K, Aletras H. Common bile-duct mucosa in choledochoduodenostomy patients--histological and histochemical study. *HPB Surg* 1988;1:15-20. doi:[10.1155/1988/85102](https://doi.org/10.1155/1988/85102)
53. Kurumado K, Nagai T, Kondo Y, Abe H. Long-term observations on morphological changes of choledochal epithelium after choledochenterostomy in rats. *Dig Dis Sci* 1994;39:809-820. doi:[10.1007/bf02087428](https://doi.org/10.1007/bf02087428)
54. Tajima Y, Eto T, Tsunoda T, et al. Induction of extrahepatic biliary carcinoma by N-nitrosobis(2-oxopropyl)amine in hamsters given cholecystoduodenostomy with dissection of the common duct. *Jpn J Cancer Res* 1994;85:780-788. doi:[10.1111/j.1349-7006.1994.tb02948.x](https://doi.org/10.1111/j.1349-7006.1994.tb02948.x)
55. Tocchi A, Mazzoni G, Liotta G, Lepre L, Cassini D, Miccini M. Late development of bile duct cancer in patients who had biliary-enteric drainage for benign disease: a follow-up study of more than 1,000 patients. *Ann Surg* 2001;234:210-214. doi:[10.1097/0000658-200108000-00011](https://doi.org/10.1097/0000658-200108000-00011)
56. Bettschart V, Clayton RA, Parks RW, Garden OJ, Bellamy CO. Cholangiocarcinoma arising after biliary-enteric drainage procedures for benign disease. *Gut* 2002;51:128-129. doi:[10.1136/gut.51.1.128](https://doi.org/10.1136/gut.51.1.128)
57. Pilgrim CH, Satgunaseelan L, Ward SM, Evans PM. Gallbladder carcinoma as a long-term complication of cholecystojejunostomy. *J Gastrointest Surg* 2009;13:2330-2332. doi:[10.1007/s11605-009-0879-6](https://doi.org/10.1007/s11605-009-0879-6)
58. Pérez Ruiz L, Gabarrell Oto A, Viñas Salas J, Torres Romañá S, Gómez Quiles L. Biliary tract cancer following bilioenteric anastomosis. *Rev Esp Enferm Dig* 1994;86:853-855.